



Incidence of Incisional Hernias in Patients Undergoing Abdominal Aortic Surgery through a Left Subcostal Minilaparotomy and Enhanced Recovery Protocol

Piero Brustia*, Renato Cassatella and Michele Aronici

Department of Vascular Surgery, University Hospital "Maggiore della Carità", Italy

Abstract

Background: This study investigated the incidence of Incisional Hernias (IHs) in patients undergoing abdominal aortic reconstructive surgery through a Left Subcostal Minilaparotomy (LSM) as a part of an enhanced perioperative recovery program.

Methods: Patients with AAA or AOD from three major institutions were retrospectively examined. Data collected included demographic, operative data and cardiopulmonary risk factors. At a minimum of 6 months after LSM patients were evaluated clinically for a new incision hernia.

Results: We treated 689 patients with a mean age of 70.6 years (range 40-89), including 631 men (91.7%) and 58 women (8.3%). Twelve patients died in the perioperative period (1.7%). The duration of follow-up was two years, and 25 patients dropped out from the control program. We found 17 IHs (2.6%) and 5 diastases of the surgical wound without involvement of the rectus sheath (0.8%).

Conclusion: LSM ensures a good seal of the abdominal-wall repair and reduces the invasiveness of the surgery without compromising the treatment of aorta-iliac diseases.

Keywords: Incisional hernias; Abdominal aortic surgery; Minilaparotomy; Enhanced recovery

Introduction

The rate of Incisional Hernias (IHs) after midline laparotomy can be as high as 21% in patients undergoing aortic surgery [1]. These abdominal-wall defects impact the overall health status and expose the patient to the risks of a new surgical procedure. Thus there is an increasing demand for less invasive approaches in traditional open surgery, primarily when endovascular techniques are not suitable [2,3]. This has a great prominence in the aortic surgery because of multiple comorbidities of the patients and the high risk for serious perioperative complications. Patients with aneurismal disease have a greater risk for abdominal-wall hernias if we compare them with those with occlusive one [4,5]. Several predisposing factors have been proposed (age, gender, smoking, diabetes, hypertension, high body mass index, blood loss, prolonged ileus, duration of surgery, closure technique and suture materials) but no one of these seems to have a decisive influence [6]. Some authors suggest the presence of a genetic predisposition or a connective structural disorder in both the aortic and abdominal wall [7]. The search for minimally invasive surgical approaches aims to reduce the impact on the patient's physiology. Currently the lowering of surgical trauma is associated with accelerated postoperative-recovery programs that involve the integrated intervention of anaesthesiologists and rehabilitation nurses [3,8]. The purpose of this study is to verify the incidence of IHs in patients undergoing abdominal aortic reconstructive surgery through a Left Subcostal Minilaparotomy (LSM) and an enhanced perioperative recovery protocol.

Methods

This study included patients who were treated for elective surgery for infra-renal Abdominal Aortic Aneurysms (AAA) or Aorto-iliac Occlusive Disease (AOD) from April 2000 to June 2011. The patients were enrolled at the Department of Vascular Surgery, University Hospital "Maggiore della Carità", Novara, Italy. The same surgical team always performed an LSM and completed all of the surgical reconstruction by means of traditional techniques and instrumentation. The minimally invasive surgical approach consisted of a left sub costal mini-incision with transperitoneal access (Figure 1). No drains or nasogastric tubes were used in the whole series. The patient was placed in a dorsal decubitus position. Depending on the abdominal size of the patients, we made a 10

OPEN ACCESS

*Correspondence:

Piero Brustia, Department of Vascular Surgery, University Hospital "Maggiore della Carità", Italy, Tel: 393356623835; E-mail: brustiapiro@aruba.it

Received Date: 28 Nov 2017

Accepted Date: 30 Dec 2017

Published Date: 08 Jan 2018

Citation:

Brustia P, Cassatella R, Aronici M. Incidence of Incisional Hernias in Patients Undergoing Abdominal Aortic Surgery through a Left Subcostal Minilaparotomy and Enhanced Recovery Protocol. *World J Vasc Surg.* 2018; 1(1): 1002.

Copyright © 2018 Piero Brustia. This is an open access article distributed under the Creative Commons Attribution License, which permits unrestricted use, distribution, and reproduction in any medium, provided the original work is properly cited.

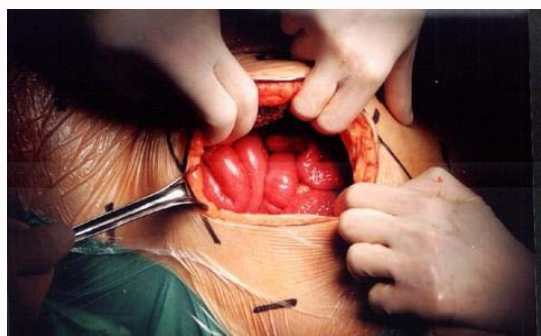


Figure 1: Peritoneal access.

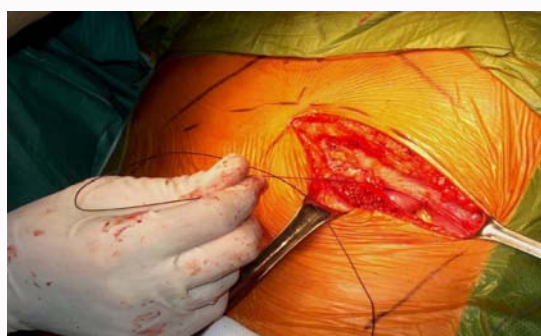

Figure 2: Closing.

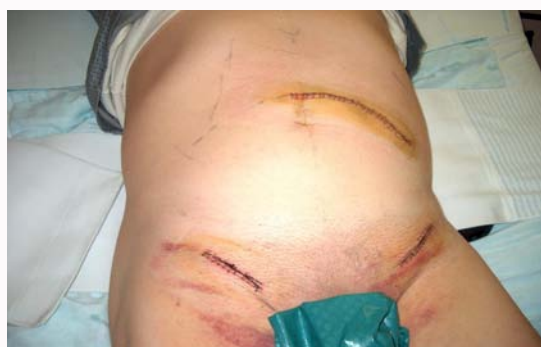

Figure 3: Wounds.

cm to 15 cm cutaneous incision that was parallel to the chondro-costal edge and spread from the linea alba to the edge of the rectus muscle. The cutaneous incision crossed the linea alba about halfway between the xiphoid and the umbilicus depending on the extension of the aortoiliac aneurismal disease. The incision of the rectus muscle allowed access to the peritoneal cavity. The oblique and transverse muscles were divided. The bowel was kept inside the abdominal cavity and displaced to the right in all cases. We usually don't use self-retaining retractors in order to avoid wall strain and to minimize postoperative pain. The abdominal wall and the bowel were retracted gently with moistened towels held by the blade intestinal retractors [9]. At the end of surgery, the patients were transferred directly to the surgical ward where the accelerated rehabilitation protocol started on the same day of surgery with early feeding and early ambulation (Figure 2). All patients underwent blended anesthesia, which included general and thoracic epidural anesthesia/analgesia [3]. We stored the patient's data in a computerized database. We always provided a clinical evaluation and an abdominal ultrasound at 6-12-18-24 months after surgery. We followed-up with the patient

Table 1: Population data, intraoperative data and outcome in postoperative period (30 days).

Total patients treated (n)	689
Male n (%)	631 (91.7)
Female n (%)	58 (8.3)
Age - mean (range)	70.6 (40-89)
Patients with ASA score 3 and 4 n (%)	549 (82.6)
Duration of surgery, minutes mean (range)	149 (75-365)
Duration of aortic clamping, minutes mean (range)	67 (25-193)
Mortality n (%)	12 (1.7)
Overall morbidity n (%)	37 (5.4)
Cardiac complications n (%)	7 (1)
Renal complications n (%)	16 (2.5)
Post operative dialysis n (%)	0 (0)
Pulmonary complications n (%)	0 (0)
Lower limb ischaemia n (%)	14 (2)
Hospital stay, days- mean (range)	4 (2-24)

for at least 12 months (range 12-156). We examined 689 patients with aortic aneurismal and obstructive disease. Among these, 631 (91.7%) were male and 58 (8.3%) female. The mean age was 70.6 (range 40-89). ASA class 3 and 4 included 82.6% of patients. Surgery lasted an average of 149 minutes (range 75-365) and the average length of aortic clamping was 67 minutes (range 25-193).

In our series, we did not have a homogeneous control group that could be compared with the group treated by LSM. This is because we performed different surgical incisions on 154 patients (median and complete transverse laparotomy, extraperitoneal access) depending on the extent of disease and the anatomical features of the aorto-iliac axis. Therefore, we draw a comparison between our sample and the international literature (Table 1).

Results

In seven patients (1%) we observed no disabling minor cardiac complications without necessity of intensive care or surgical/endovascular procedure. There was a transient increase (at least a 50% increase of the preoperative levels) of creatinine serum levels in 16 patients (2.5%). Fourteen patients (2%) experienced acute ischemia of the lower limbs that required additional intervention. The overall perioperative mortality was 1.7% (12 patients died within 30 days). The mean hospital stay was four days.

We followed up on 677 patients. Twenty-five patients were lost to clinical monitoring. In the remaining 652 patients (569 aortic aneurysms and 83 aorto-iliac obstructions) we found 17 (2.6%) incisional hernias and five (0.8%) with diastases of the surgical wound without involvement of rectus sheath (Figure 3). We recorded 15 cases of hernia in the aneurysm group (2.6%) and two cases in the obstructive-disease group (2.4%).

Discussion

The traditional midline incision is simple but results in a high rate of complications. Incisional hernias are a significant cause of morbidity and mortality following aortic abdominal surgery, also owing to the associated pathologies. True aneurysms of the abdominal aorta and its branches are partly due to defects in the structural integrity of the arterial wall. Whether the defect is isolated to the vascular wall

Table 2: Comparison of the literature.

	Hall KA, et al. [12]	Musella M, et al. [17]	Raffetto JD, et al. [6]	Gruppo M, et al. [5]	Brustia, et al. [3,4]
Male, n (%)	139 (72)	99 (86.8)	203 (78.4)	734 (68.9)	598 (91.7)
AAA, n (%)	128 (66.3)	51 (44.7)	177 (68.3)	412 (38.7)	569 (87.3)
AOD, n (%)	65 (33.7)	63 (55.3)	82 (31.7)	653 (61.3)	83 (12.7)
Follow-up (months, n)	60	48.6	32.8	79	24
Incidence of IHs, n (%)	54 (27.9)	33 (28.8)	59 (22.7)	124 (11.6)	17 (2.6)
AAA, n (%)	41 (32)	20 (39.2)	50 (28.2)	51 (12.4)	15 (2.6)
AOD, n (%)	13 (20)	13 (20.6)	9 (11)	73 (11.2)	2 (2.4)
Incidence of diastasis of rectum muscle, n (%)	-	-	-	-	5 (0.8)

is unclear. If the structural weakness involves other tissues, patients with aneurysmal disease should have a higher incidence of collagen and fascial defects, such as abdominal and inguinal hernias.

Some studies have suggested that a modification in metabolism of connective tissues is responsible for such diseases. Some authors reported an increased incidence of abdominal wall hernias in patients undergoing surgery for aneurysmal disease and in patients undergoing surgery for aorto-iliac obstructive disease. The meta-analysis by Takagi shows that the risk increases by five times for the first group compared to the second [10]. Most incisional hernias develop within two years of operation. Israelsson emphasizes the importance of suture technique rather than the type of incision. Our experience and the most important ones in the international literature are summarized in (Table 2) [4,5,11-17]. LSM seems to provide better results because the proportion of patients experiencing an IHs was only 2.6% in the entire sample, 2.6% in the aneurysm group and 2.4% in the aorto-iliac obstructive disease group ($p < 0.05$). In the literature, the rate of IHs was never less than 7.4% considering all of the aortic pathologies, 10% considering only the aneurysmal disease and 3% considering only the occlusive one.

The prophylactic placement of a pre-peritoneal polypropylene mesh appears to be an effective method to decrease the incidence of IHs after AAA repair [18,19]. Incisional hernia rates are known to be lower if a transverse incision is used but two randomised trials and a systematic review showed no differences between the midline and transverse incisions [20-22].

Conclusions

Our technique allows for reduced invasiveness, thereby enhancing the quality of the arterial repair. At the same time it favours an accelerated recovery in the context of an enhanced recovery protocol. This experience suggests that the use of LSM for treatment of aortic diseases can preserve the outcomes of vascular reconstruction and at the same time to reduce the IHs rate and the associated potential hazard.

References

- Stevick CA, Long JB, Jamasbi B, Nash M. Ventral hernia following abdominal aortic reconstruction. *Am Surg*. 1988;54(5):287-9.
- Turnipseed WD. A less invasive minilaparotomy technique for repair of aortic aneurysm and occlusive disease. *J Vasc Surg*. 2001;33(2):431-4.
- Brustia P, Renghi A, Gramaglia L, Porta C, Cassatella R, De Angelis R, et al. Minimally invasive abdominal aortic surgery. Early recovery and reduced hospitalization after multidisciplinary approach. *J Cardiovasc Surg*. 2003;44(5):629-35.
- Brustia P, Renghi A, Fassiola A, Gramaglia L, Della Corte F, Cassatella R, et al. Fast-track approach in abdominal aortic surgery: left subcostal incision with blended anesthesia. *Interact Cardiovasc Thorac Surg*. 2007;6(1):60-4.
- Gruppo M, Mazzalai F, Lorenzetti R, Piatto G, Toniato A, Ballotta E. Midline abdominal wall incisional hernia after aortic reconstructive surgery: a prospective study. *Surgery*. 2012;151(6):882-8.
- Raffetto JD, Cheung Y, Fisher JB, Cantelmo NL, Watkins MT, Lamorte WW, et al. Incision and abdominal wall hernias in patients with aneurysm or occlusive aortic disease. *J Vasc Surg*. 2003;37(6):1150-4.
- Henriksen NA, Helgstrand F, Vogt KC, Jorgensen LN, Bisgaard T. Risk factors for incisional hernia repair after aortic reconstructive surgery in a nationwide study. *J Vasc Surg*. 2013;57(6):1524-30.
- Antoniou GA, Georgiadis GS, Antoniou SA, Grandrath FA, Giannoukas AD, Lazarides MK. Abdominal aortic aneurysm and abdominal wall hernia as manifestations of a connective tissue disorder. *J Vasc Surg*. 2011;54(4):1175-81.
- Brustia P, Porta C. Left sub costal minilaparotomy in aortic surgery. *Minerva Cardioangiol*. 2001;49(1):91-7.
- Takagi H, Sugimoto M, Kato T, Matsuno Y, Umemoto T. Postoperative incision hernia in patients with abdominal aortic aneurysm and aortoiliac occlusive disease: a systematic review. *Eur J Vasc Endovasc Surg*. 2007;33:177-81.
- Israelsson LA. Incisional hernias in patients with aortic aneurysmal disease: the importance of suture technique. *Eur J Vasc Endovasc Surg*. 1999;17(2):133-5.
- Hall KA, Peters B, Smyth SH, Warneke JA, Rappaport WD, Putnam CW, et al. Abdominal wall hernias in patients with abdominal aortic aneurysmal versus aortoiliac occlusive disease. *Am J Surg*. 1995;170(6):572-5.
- Adye B, Luna G. Incidence of abdominal wall hernia in aortic surgery. *Am J Surg*. 1998;175(5):400-2.
- Holland AJ, Castleden WM, Norman PE, Stacey MC. Incisional hernias are more common in aneurysmal arterial disease. *Eur J Vasc Endovasc Surg*. 1996;12(2):196-200.
- Papadimitriou D, Pitoulis G, Papaziogas B, Koutsias S, Vretzakis G, Argiriadou H, et al. Incidence of abdominal wall hernias in patients undergoing aortic surgery for aneurysm or occlusive disease. *Vasa*. 2002;31:111-4.
- Liapis CD, Dimitroulis DA, Kakisis JD, Nikolaou AN, Skandalakis P, Daskalopoulos M, et al. Incidence of incisional hernias in patients operated on for aneurysm or occlusive disease. *Am Surg*. 2004;70:550-2.
- Musella M, Milone F, Chello M, Angelini P, Jovino R. Magnetic resonance imaging and abdominal wall hernias in aortic surgery. *J Am Coll Surg*. 2001;193:392-5.
- O'Hare JL, Ward J, Earnshaw JJ. Late results of mesh wound closure after elective open aortic aneurysm repair. *Eur J Vasc Endovasc Surg*. 2007;33:412-3.

19. Bevis PM, Windhaber RA, Lear PA, Poskitt KR, Earnshaw JJ, Mitchell DC. Randomized clinical trial of mesh versus sutured wound closure after open abdominal aortic aneurysm surgery. *Br J Surg.* 2010;97:1497-502.
20. Halm JA, Lip H, Schmitz PI, Jeekel J. Incisional hernia after upper abdominal surgery: a randomised controlled trial of midline versus transverse incision. *Hernia.* 2009;13:275-80.
21. Fassiadis N, Roidl M, Hennig M, South LM, Andrews SM. Randomized clinical trial of vertical or transverse laparotomy for abdominal aortic aneurysm repair. *Br J Surg.* 2005; 92:1208-11.
22. Brown SR, Goodfellow PB. Transverse versus midline incisions for abdominal surgery. *Cochrane Database Syst Rev.* 2005;19;CD005199.