



Hidradenitis Suppurativa: The Third Cause of Vulva Carcinoma

Ineke Janse^{1*}, Gilles Diercks^{1,2}, Jan Doff¹, Marian Mourits³ and Barbara Horvath¹

¹Departments of Dermatology, University of Groningen, University Medical Center Groningen, Groningen, The Netherlands

²Departments of Pathology, University of Groningen, University Medical Center Groningen, Groningen, The Netherlands

³Departments of Gynecology, University of Groningen, University Medical Center Groningen, Groningen, The Netherlands

Abstract

The development of Squamous Cell Carcinoma (SCC) is a severe complication of chronic Hidradenitis Suppurativa (HS). Male patients with prolonged HS in extra-axillary areas are especially at risk of this complication. The case in our paper of HS associated with vulvar SCC emphasizes that women can also develop this complication. In addition to lichen sclerosus vulvae (via dVIN) and high risk HPV (via uVIN) there is a third disease that can lead to vulvar cancer, namely chronic HS. The clinician should look out for a malignant transformation in the presence of severe, chronic HS, and have a low threshold for biopsy. Staging, therapy and follow-up should be performed by gynecologic oncologists.

Keywords: Chronic hidradenitis suppurativa; Sclerosus vulvae; Vulvar cancer

Case Presentation

A 56-year-old woman, with a 30-year history of Hidradenitis Suppurativa (HS), presented herself to the emergency department with a painful growth on her right labium majus. A physical examination uncovered a 2 cm diameter verrucous tumor on an erythematous, enlarged, diffuse infiltrated labium majus on a background of HS Hurley stage III with scarring and sinus tract formation (Figure 1). An abscess was suspected in the context of a HS whereupon a general surgeon performed an incision and drainage. However, no pus oozed out and a skin biopsy was taken. Histopathology showed a Squamous Cell Carcinoma (SCC), but was high risk (hr) human papillomavirus (HPV) negative (Figure 2). The sentinel lymph nodes were free of disease. SCC is a rare but severe complication of HS. Malignant transformation in long-standing HS results from chronic inflammation, a phenomenon known as Marjolin's Ulcer [1].

There is a lack of reliable incidence rate estimates of SCC arising in HS. Only 7 cases, including our patient, of HS associated vulvar SCC have been reported [2]. Although HS is three times more common in women than in men, SCC development in HS is observed more frequently in males (4:1 ratio) [3]. This can be explained by the fact that perineal/gluteal and perianal HS lesions have the highest predisposition to becoming malignant and these are the typical HS locations in men [1]. HS rarely occurs in these locations in women, but rather in the groin or the chest [4].

SCCs develop after 20-30 years of chronic HS [3]. Early recognition is important where the prognosis of vulvar cancer is associated with lymph node metastases in the groin and tumor size [5]. In HS, SCCs can be recognized by a persisting tumor or ulcer and the lack of typical HS features like sinus tracts and inflammation. 'High risk' (hr) human papillomavirus (HPV) can be identified in one-third of vulvar SCCs and is supposed to be a contributory factor of HS associated perianal/perineal SCC [6]. Studies showed that HPV types, especially HPV-16, are present in these carcinomas [3]. The presence of hrHPV was not investigated in the previously reported cases of HS associated vulvar SCCs. Our case suggests that hrHPV does not play a role in HS associated vulvar SCC.

Our patient was referred to the gynecologic oncologist who performed a sentinel node (SN) procedure and wide local excision. Histopathology showed negative SN and clear margins. No signs of recurrence were seen six months after the diagnosis. Staging, therapy and follow-up of vulvar SCC should be performed by gynecologic oncologists, according to the guidelines for vulvar cancer [7].

OPEN ACCESS

*Correspondence:

Ineke Janse, Department of Dermatology, University of Groningen, University Medical Center Groningen, Hanzeplein 1, 9700 RB Groningen, The Netherlands, Tel: +31-50-3614565; Fax: +31-50-3612624;

E-mail: i.c.janse@umcg.nl

Received Date: 16 Oct 2017

Accepted Date: 23 Nov 2017

Published Date: 30 Nov 2017

Citation:

Janse I, Diercks G, Doff J, Mourits M, Horvath B. Hidradenitis Suppurativa: The Third Cause of Vulva Carcinoma. *J Clin Obstet Gynecol Infertil*. 2017; 1(5): 1022.

Copyright © 2017 Ineke Janse. This is an open access article distributed under the Creative Commons Attribution License, which permits unrestricted use, distribution, and reproduction in any medium, provided the original work is properly cited.

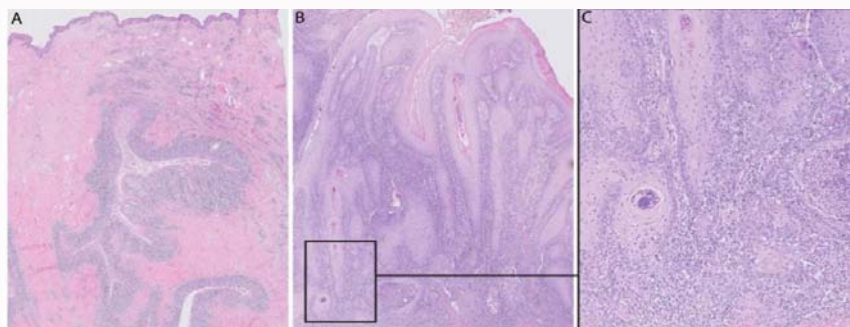


Figure 1: Histopathology: A) Invaginated anastomoses (sinus tracts). B) Well-differentiated squamous cell carcinoma (SCC). Atypical cells with enlarged, irregular nuclei and mitoses. C) SCC infiltrating the fibrous stroma.

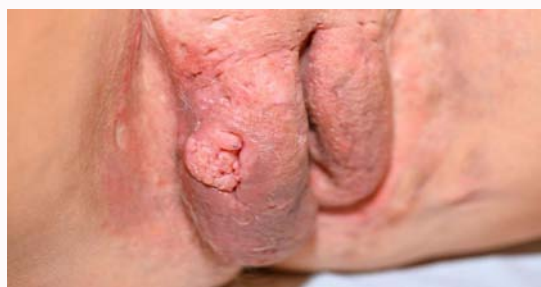

Figure 2: Two cm diameter verrucous tumor on an erythematous, enlarged, diffuse infiltrated labium majus on a background of HS Hurley stage III with scarring and sinus tract formation.

Conclusion

This case shows that, in addition to lichen scleroses (via differentiated-type VIN) and high-risk HPV (via usual-type VIN), a third disease can progress to vulva carcinoma, namely chronic HS [8]. Therefore, clinicians should be vigilant for malignant transformation in HS and have a low threshold for biopsy.

References

1. Yon JR, Son JD, Fredericks C, Morton M, Kingsley S, Gupta S, et al. Marjolin's ulcer in chronic hidradenitis suppurativa: A rare complication of an often neglected disease. *J Burn Care Res.* 2017;38(2):121-4.
2. Makris GM, Poulakaki N, Papanota AM, Kotsifa E, Sergeantanis TN, Psaltopoulou T. Vulvar, perianal and perineal cancer after hidradenitis suppurativa: A systematic review and pooled analysis. *Dermatol Surg.* 2017;43(1):107-15.
3. Rekawek P, Shailja M, Andikyan V, Harmaty M, Konstantin Z. Squamous cell carcinoma of the vulva arising in the setting of chronic hidradenitis suppurativa: A case report. *Gynecol Oncol Rep.* 2016;16:28-30.
4. Revuz J. Hidradenitis suppurativa. *J Eur Acad Dermatol Venereol.* 2009;23(9):985-98.
5. Van der Zee AG, Oonk MH, De Hullu JA, Ansink AC, Vergote I, Verheijen RH, et al. Sentinel node dissection is safe in the treatment of early-stage vulvar cancer. *J Clin Oncol.* 2008;26(6):884-9.
6. Fox H, Wells M. Recent advances in the pathology of the vulva. *Histopathology.* 2003;42(3):209-16.
7. Te Grootenhuys NC, van der Zee AG, van Doorn HC, van der Velden J, Vergote I, Zanagnolo V, et al. Sentinel nodes in vulvar cancer: Long-term follow-up of the GONingen International Study on Sentinel nodes in Vulvar cancer (GROINSS-V) I. *Gynecol Oncol.* 2016;140(1):8-14.
8. Sideri M, Jones RW, Wilkinson EJ, Preti M, Heller DS, Scurry J, et al. Squamous vulvar intraepithelial neoplasia: 2004 modified aterminology, ISSVD Vulvar Oncology Subcommittee. *J Reprod Med.* 2005;50(11):807-10.