



Embedded and Fractured Esophageal Self-Expanding Metal Stent

Sabbah Meriam*, Trad Dorra, Ouakaa Asma, Elloumi H ela, Bibani Norsaf and Gargouri Dalila

Department of Gastroenterology, Habib Thameur Hospital, Tunisia

Clinical Image

A 70-year-old hypertensive patient underwent right bilobectomy for pulmonary carcinosarcoma. Five days after the procedure, he presented esophageal fistula treated endoscopically by a 12 cm partially covered metal stent. The patient was lost of view during three months after procedure. He presented then for dysphagia. Upper endoscopy (Figure 1) and CT scan (Figure 2 and 3) showed an impacted and fractured stent. The stent could not be removed endoscopically due to the embedding of the uncovered stent ends in the oesophageal wall.

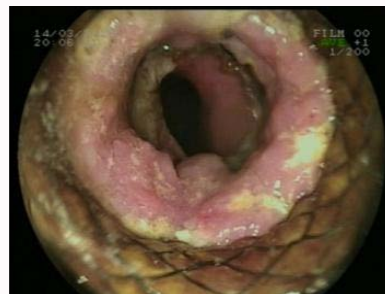

Figure 1: Upper endoscopy showing and embedding of the upper metallic stent end in the oesophageal wall.

OPEN ACCESS

*Correspondence:

Sabbah Meriam, Department of Gastroenterology, Habib Thameur Hospital, 1 rue El Messelekh, Montfleury, 2004 Tunis, Tunisia, Tel: 21671397000, E-mail: sabbah_meriam@yahoo.fr

Received Date: 19 Mar 2019

Accepted Date: 01 Apr 2019

Published Date: 04 Apr 2019

Citation:

Meriam S, Dorra T, Asma O, H ela E, Norsaf B, Dalila G. Embedded and Fractured Esophageal Self-Expanding Metal Stent. *Oncol Case Report J.* 2019; 2(1): 1010.

Copyright   2019 Sabbah Meriam.

This is an open access article distributed under the Creative Commons Attribution License, which permits unrestricted use, distribution, and reproduction in any medium, provided the original work is properly cited.

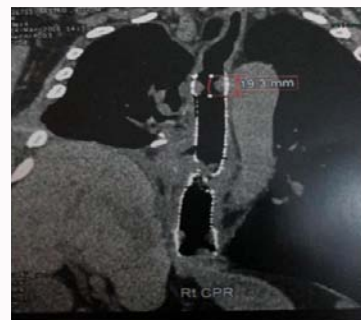

Figure 2: CT scan (coronal slice) showing an embedding of the two ends of the stents in the oesophageal wall with median fracture of the stent.

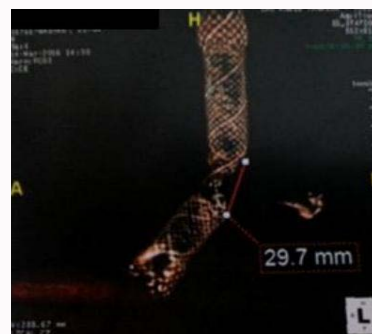


Figure 3: CT scan (reconstruction) showing the median fracture of the oesophageal stent.