Annals of Short Reports

Case Report
Published: 09 Mar, 2020

Non-Parazitary Cysts of the Liver

Kemal P[1], Ramazan D[2], Alper Murat İ[1] and Ertan E[2]*

[1]*Department of General Surgery, Düzce University, Turkey*

[2]*Department of General Surgery, Yedikule University, Turkey*

Abstract

Some of the non-parasitic cystic lesions of the liver are benign, small and asymptomatic lesions. They are often detected accidentally. In particular, the spread and increase of imaging methods led to an increase in coincidental findings and incidences of these lesions. Only 16% of cases are symptomatic. Symptoms are directly related to the size of the cyst or the pressure on the surrounding tissues. Abdominal pain and distension are the most common symptoms and occur in approximately 50% of cases. For asymptomatic cases, no treatment is required. In contrast, large, symptomatic and neoplastic cysts require treatment. In our study, we wanted to present two simple epithelial liver cyst cases that refer to our clinic with complications.

Keywords: Liver; Non-parasitic cyst; Simple cyst

Introduction

Non-parasitic cysts of the liver; are highly heterogeneous lesions in terms of their pathogenesis, clinical features, diagnostic methods and treatment requirements. Most of the simple cystic lesions are benign and asymptomatic. Liver cysts are usually solitary and unilocular lesions and are the most common benign lesions of the liver. Rarely, large cysts can cause discomfort and a mass in the upper abdominal region. In polycystic liver disease, there are more than twenty cysts in the liver. This form is associated with genetic diseases [1,2]. In our study, we wanted to introduce two cases that applied to our clinic as a result of advanced complications.

Case Presentation

Case 1

A 26-year-old female patient applied to the outer center with complaints of pain and occasional nausea in the upper right quadrant about a year ago. In the examinations performed here, a cystic lesion in the liver is detected and the follow-up of the patient is decided. The patient applies to our general surgery outpatient clinic about 7 months after his complaints increase. In the all abdominal USG assessment, a cystic lesion of approximately 10 cm × 8 cm with air fluid levels was detected in liver right lobe localization. KC abscess was considered in the patient, but additional tests were performed on the patient as the other clinical findings were not compatible with the abscess.

ELISA test results for liver hydatid cyst disease were reported as negative. The *Entemobea histolitica* antibody test studied in the patient was negative. In the upper abdominal Computed Tomography (CT), which was taken with IV and Oral contrast, revealed cystic formation in segment 4B, which is associated with duodenum with a diameter of about 10 cm and which is contrasting with oral contrast graphs (Figure 1). Consequently, the upper GIS endoscopy was planned for the patient considering that there was a fistula between the cyst and the intestinal system. In the regular upper GIS endoscopic examination, the opening that allows the passage of the endoscope in the lateral of the bulbus was detected just distal to the pylorus. When passed through the endoscope, a cystic lesion filled with bile residues located in the liver parenchyma was observed (Figure 2). After the interviews with the patient, the decision for exploration was made. During the operation, a 15 mm diameter fistula (Figure 3) was observed in the medial of the gallbladder, extending from the liver parenchyma to the duodenum, located on the hepatoduodenal ligament and separated from the hepatoduodenal ligament by clear borders. After suspending the fistula tract and making sure it was unrelated to the hepatoduodenal ligament and the structures within it, the tract us broke down and the duodenum side double layer primary was repaired. When the cyst content was aspirated, a collapse occurred in the liver parenchyma. The cyst wall was completely excised by opening this place. The operation was terminated by placing two rubber drains into the cyst and Morison pouch. Patient post op 5 the day was withdrawn upon the absence from the drains in Morison pouch.

OPEN ACCESS

Correspondence:
Kemal Peker, Department of General Surgery, Düzce University, 81620 Yoruk, Turkey, Tel: +90-5359368528; E-mail: k.peker@yahoo.com.tr

Received Date: *17 Feb 2020*
Accepted Date*: 05 Mar 2020*
Published Date*: 09 Mar 2020*

Citation:
Kemal P, Ramazan D, Alper Murat İ, Ertan E. Non-Parazitary Cysts of the Liver. Ann Short Reports. 2020; 3: 1048.

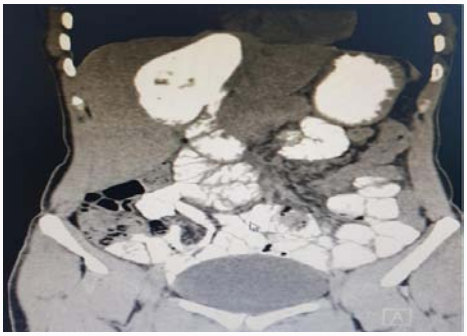

Figure 1: Radiological view of the fistula tract formed between the liver and duodenum.

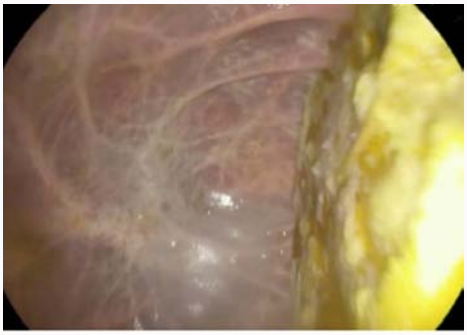

Figure 2: Liver cyst seen in endoscopic examination.

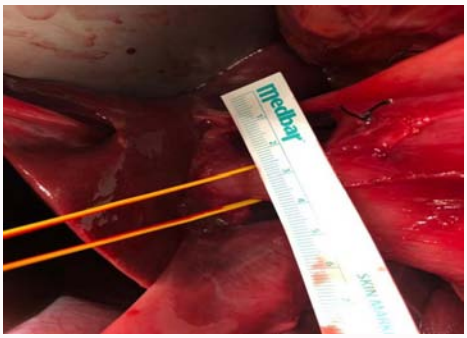

Figure 3: Intaoperative view of hepatoduodenal fistula.

The drain inserted into the cyst did not come after the first day of postoperative. However, since a partial cystectomy was performed, the drain was followed for about 6 weeks. Pathological examination of the cyst content and excised wall was reported as fibrotic non-epithelial tissue.

Case 2

A 75-year-old male was admitted due to severe abdominal pain and fever. In the physical examination, widespread sensitivity in all quadrants, especially in the upper right quadrant and epigastric region, muscular defenses and rebounds were present. The tests were Hgb: 11.9 g/dl WBC: 6800 Plt: 232000 CRP: 93 mg/L. In abdominal CT, the largest 17 cm × 15 cm interrelated smooth contoured hypodense lesions covering the left lobe in the liver are evaluated as simple cysts, and also 9 cm × 1 cm wide free liquid cyst perforation in the lateral right lobe of the liver? Reported as Figure 4. The patient underwent the operation after the patient's complaints failed to recede during clinical follow-up. Widespread peritonitis due to cyst perforation

Figure 4: Macroscopic view of a simple cyst that has completely covered the left lobe of the liver.

was observed in the operation. The cysts associated with each other completely covering the left lobe of the liver were totally excised. The patient, who had no problems with follow-up, was externalized. Specifically pathologically taken in the operation; Tissue fragments lined with a single row of cubic epithelium in the focal area, showing signs of active chronic inflammatory infiltration and bleeding in the fibrous wall, and fibrosis, mononuclear inflammatory cell infiltration with increased connective tissue in the surrounding liver tissue.

Discussion

Non-parasitic simple epithelial cysts that can be seen in the liver are generally benign lesions. There are reports that the incidence varies between 1% and 5%. In particular, the spread and increase of imaging methods has led to an increase in the incidences and incidences of these lesions [3]. No treatment is required for non-symptomatic cases. Only 16% of cases are symptomatic. Symptoms are directly related to the size of the cyst or its pressure on surrounding tissues. According to this, abdominal pain, palpable abdominal mass, nausea, vomiting, dyspnea, fatigue, feeling of quick saturation, cholestasis and jaundice signs and symptoms can be seen frequently. Abdominal pain and distension are the most common symptoms and occur in approximately 50% of cases. Liver function tests are completely normal in simple cysts of the liver. If a liver function test shows a disorder, it is not caused by a cyst, but by another liver disease. Simple liver cysts are usually millimeters in size, but they can also be large sizes up to 20 cm [4-6].

The most effective imaging method for diagnosis is Ultrasonography (US). The sensitivity and specificity of the diagnosis is approximately 90%. It is also cheap and non-invasive; the patient is not exposed to radiation. Therefore, other imaging methods are often unnecessary. It is observed in the form of a massive, circular or oval, completely anechoic and strong posterior wall echo in the US. If done, CT shows a sharp limited, homogeneous and hypodens lesion. Magnetic Resonance Imaging (MRI) shows a low signaling lesion in T1 series and high signaling lesion in T2 series, and this signaling feature is not affected by contrast injection. Its complications are rare; the most common is bleeding into the cyst. In this case, sudden, severe pain develops and the cyst diameter grows rapidly. In the US, this time, typically a hyperechogenic echo pattern is detected and a septation or solid component-like appearance is detected inside. Other complications include rupture, bacterial infection, inferior vena cava compression, duodenum fistulization, cholestasis, portal vein compression and portal hypertension. In the differential diagnosis, liver abscess, malignant tumor, giant hemangioma, hematoma and *Echinococcus* cyst should be considered [7,8].

Asymptomatic and small cyst (<8 cm) follow-up is sufficient for the management of simple cysts. Treatment should be considered if there is a change in the size of the cyst or growth in size, such as in a very small patient population during follow-up [9,10]. Large symptomatic and neoplastic cysts require treatment. Aspiration indication is very limited as repeated fluid accumulation is rapid in symptomatic large simple cysts, neoplastic ones need to be excised. In contrast, small cysts can be aspirated and eliminated by injecting alcohol into them. Eradication with alcohol injection is not possible in large symptomatic cysts. The most effective method for these cysts is laparoscopic unroofing (excision of the superficial part of the cyst approximately 30% to 40%) and omentoplasty if necessary. Multiple cysts generally do not require treatment, but in cases with symptomatic (abdominal pain, obstructive jaundice) very large polycystic liver disease, abdominal drainage of cyst fluids can be achieved by unroofing the superficial cysts and by opening windows between the deep cysts and superficial cysts, thus reducing the size of the liver to about half [4,11].

Result

Most non-parasitic cystic lesions of the liver are benign, small and asymptomatic lesions, and are often detected accidentally. No treatment is required for these. In contrast, large, symptomatic and neoplastic cysts require treatment. Aspiration indication is very limited as repeated fluid accumulation is rapid in symptomatic large simple cysts, neoplastic ones need to be excised. In contrast, small cysts can be aspirated and eliminated by injecting alcohol into them. Eradication by alcohol injection is not possible in large symptomatic cysts. The most effective method for these cysts is laparoscopic unroofing (excision of approximately 30% to 40% of the cyst's superficial section) and, if necessary, omentoplasty. Multiple cysts usually do not require treatment, but in patients with symptomatic (abdominal pain, obstructive jaundice) very large polycystic liver disease, an unroofing procedure to be applied to superficial cysts and abdominal drainage of cyst fluids can be achieved by opening windows between deep cysts and superficial cysts.

References

1. Macutkiewicz C, Plastow R, Melissa Chrispijn M, Filobbos R, Ammori BA, Sherlock DJ, et al. Complications arising in simple and polycystic liver cysts. World J Hepatol. 2012;4(12):406-11.
2. Amendolara M, Bucca D, Barbarino C, Romano MF, Marino G, Zucchelli M, et al. Surgical management of symptomatic simple hepatic cysts. G Chir. 2012;33(1-2):17-20.
3. Kentaro I, Tomohiro I, Shuhei I, Takefumi O, Tadahiro N, Shirabe K, et al. Rerupture of nonparasitic liver cyst treated with cyst fenestration: A case report. Surg Case Rep. 2015;1:71.
4. Kapan M. Liver cysts and hydatid Disease. Goksoy E, editor. General Surgery Course Book, Istanbul University Publications, Istanbul; 2010:s559.
5. Lantiga MA, Gevers TJ, Drenth JP. Evaluation of hepatic cytic lesions. World J Gastroenterol 2013;19(23):3543-54.
6. Macedo FI. Current management of noninfectious hepatic cystic lesions: A review of the literature. World J Hepatol. 2013;5(9):462-9.
7. Farges O, Menu Y, Benhamou JP. Non-parasitic cystic disease of the liver and intrahepatic biliary tree. In: Blumgart LH, Fong Y, editors. Surgery of the Liver and Biliary Tract, 3rd ed. WB Saunders. 2000;1243-60.
8. Ruiz-Tovar J, López-Buenadicha A, Moreno-Caparros A, Vázquez-Garza JN. Surgical management of simple liver cysts. Cir Cir. 2012;80(1):52-5.
9. Saini S, Mueller PR, Ferrucci JT, Simeone JF, Wittenberg J, Butch RJ. Percutaneous aspiration of hepatic cysts does not provide definitive therapy. Am J Roentgenol. 1983;141(3):559-60.
10. Souftas VD, Kosmidou M, Karanikas M, Souftas D, Menexes G, Prassopoulos P. Symptomatic abdominal simple cysts: Is percutaneous sclerotherapy with hypertonic saline and bleomycin a treatment option? Gastroenterol Res Pract. 2015;2015:489363.
11. Garcea G, Rajesh A, Dennison AR. Surgical management of cystic lesions in the liver. ANZ J Surg. 2013;83(7-8):E3-20.