Journal of Dermatology and Plastic Surgery

Research Article
Published: 04 Mar, 2019

Needling Combined with Intralesional Corticosteroid Injections Compared to Intralesional Botulinum Toxin A Injections in the Treatment of Hypertrophic Scars and Keloids

*Eman El Morsy, Tarek M Hussien and Omnia M Abdel Maksoud**

Department of Dermatology, Venereology and Andrology, Alexandria University, Egypt

Abstract

Introduction: Scar formation is an inevitable consequence of wound healing from either a traumatic or a surgical intervention in which the normal skin is replaced by a fibrous tissue, although Scar formation is beneficial in wound healing, it can lead to cosmetic problems, psychological and financial issues.

Material and Method: Forty patients were divided into two groups, Group A was subjected to needling technique followed by intralesional injection of triamicinolone acetonide (40 mg/ml) in the same session once/month for three months, while group B was subjected to intralesional botulinum toxin A injection once/month for three months. An independent physician evaluator assessed the treatment outcomes using Vancouver Scar Scale (VSS) and Quartile grading scale (slight improvement: 0% to 25%; moderate: 25% to 50%; significant: 50% to 75%; marked: 75% to 100% improvement).

Results: There were statistically significant differences between the 2 groups as regards the VSS (p=0.023). Average percentage changes of VSS were 84.47% ± 14.34% in group A while was 72.71% ± 14.60% in group B. Improvement was evident as regards vascularity, pliability, height and pigmentation in both groups after treatment with better results in group A. Patient's subjective satisfaction scores paralleled the physician's objective evaluation.

Conclusion: Microneedling combined IL-CST injection is safe and effective modality and its results was superior to IL-BTA in the treatment of HTSs and keloids.

Keywords: Scars; Needling; Steroid; Botox

OPEN ACCESS

***Correspondence:**
Omnia M Abdel Maksoud, Department of Dermatology, Venereology and Andrology, Faculty of Medicine, Alexandria University, Ibn Salama Street, Victoria, Alexandria, Egypt, Tel: 01003299804;
E-mail: linamostafa1212@gmail.com

Received Date: *18 Jan 2019*
Accepted Date*: 01 Mar 2019*
Published Date*: 04 Mar 2019*

Citation:
El Morsy E, Hussien TM, Abdel Maksoud OM. Needling Combined with Intralesional Corticosteroid Injections Compared to Intralesional Botulinum Toxin A Injections in the Treatment of Hypertrophic Scars and Keloids. J Dermatol Plast Surg. 2019; 3(1): 1021.
ISSN: 2475-5753

Introduction

Scars are the end point of the abnormal wound repair which is a fibrous tissue replacement manifesting itself as an elevated or depressed area, with an alteration of skin texture, color, vascularity, nerve supply and biomechanical properties [1].

Hypertrophic scars and keloids differ clinically and histologically. HTSs are fibrous tissue outgrowth with excessive scarring, which are confined to the original wound margins. They grow rapidly for several months and then gradually regress over the next few years. They are red or pink, rigid and sometimes pruritic, certain sites such as the chest and back are predisposed because of increased skin tension [2,3]. Whereas keloids extend beyond the borders of the original wound invading into and around normal skin. Keloid usually appear as firm nodules, often pruritic, painful and generally do not regress spontaneously [3].

There are numerous treatments available including surgical excision, intralesional steroid injection, radiation therapy, lasers and pressure therapy [4,5]. However, outcomes have remained unsatisfactory and require several treatments to achieve satisfactory results.

Microneedling technique has become a novel strategy for the treatment of scars; it acts through producing micropunctures which induce a controlled skin injury without actually damaging the epidermis. These microinjuries lead to minimal superficial bleeding and set up a wound healing cascade with release of various growth factors [6]. The needles also breakdown the old hardened

scar strands and allow it to revascularize. This triggers increase cell activity and the release of various proteins, potassium and growth factors leading to migration of fibroblasts to the site of injury and collagen induction. After needling TGF-β-1 and -β-2 rapidly disappear from the scene and TGF-β-3 dominates and that results in scarless healing and regeneration [7]. The expression of matrix metalloproteinases induced by microneedling is speculated in reduction of hyperpigmentation [8]. Microneedling enhances the delivery of various drugs across the skin barrier as it bypasses the stratum corneum and deposits the drug directly into the vascularized dermis.

Intralesional steroids was the main treatment for decades, leading to improvement through variable mechanisms mainly by excerting their anti-inflammatory properties and reduction of glycosaminoglycans, it has been suggested that steroids exert a vasoconstrictor and an antimitotic activity. It also arrest pathological collagen production and increase collagen degradation through two distinct mechanisms: reduction of oxygen and nutrients to the scar with inhibition of the proliferation of keratinocytes and fibroblasts [9,10].

Botulinum toxin type A is an exotoxin of the anaerobic spore forming bacterium, Clostridium botulinum. It act through inhibition of acetylcholine release, blocking cholinergic neuromuscular transmission or cholinergic autonomic innervation of exocrine glands and smooth muscles [11]. It can minimize scarring through temporary denervation of smooth muscle fibers decreasing the tension in the scar tissue that acts on the healing wound. It may produce changes in the muscle spindles, that could lead to altered sensory input, changes in the cell cycle and distribution of fibroblasts derived from the scar and gradually change their functional status to proliferate slower, secrete less biologically active mediators and synthesize less extracellular matrix and collagen resulting in improvement of hypertrophic scars and keloids [3,12,13].

Materials and Methods

This study was a randomized comparative trial. A total of 40 Egyptian patients who attended the dermatology outpatient clinic of Alexandria Main University Hospital (AMUH) is from June 2017 to March 2018. Patients were diagnosed clinically with hypertrophic scars and keloids. This study included, 12 males and 28 females aged between 10 and 30 years old, 2 patients had Fitzpatrick skin type II, 12 had Fitzpatrick skin type III, and 26 had Fitzpatrick skin type IV. Patients were randomly distributed into two groups in individual sealed envelopes. Each group included twenty patients (n=20). Group A was subjected to needling technique followed by intralesional corticosteroid injection in the same session once/month for three months, while group B was subjected to intralesional botulinum toxin injection once/month for three months.

Procedure

Group A: Anesthesia of the treatment area with topical anesthetic containing Eutectic Mixture of Lignocaine and Prilocaine (EMLA cream) was used under occlusion for 45 minutes to 1 hour preoperatively and disinfection of the operation area using Povidon Iodine then antiseptic and saline, a drop of lubricant was applied to the scar surface, the skin was stretched with one hand and perpendicularly rolling was done 5 to 10 times each in the horizontal, vertical, oblique directions (star shaped) and in stamping manner with the other hand, derma pen (Dermapen 3™) was used, The depth used 1.5 mm to 3 mm according to the height of the scar [14]. The treatment end point was identified as uniform pin-point bleeding which was easily controlled. The treatment took an average of 15 mins to 20 mins. The area was made wet with saline or ice packs [14].

The steroid used was triamcinolone acetonide (kenacort) 40 mg⁄mL injected using a 30 G needle insulin syringe, The solution was injected undiluted into the body of the scar until slight blanching was clinically visible about 30 minutes following the derma pen session. The maximum volume of injection per cm^2 did not exceed 0.5 mL. The delivered dose was adjusted according to the extent of the lesions but did not exceed 2 mL per session. Only the elevated portion of the hypertrophic scar or the keloid was treated by multiple injections [15].

Group B: BTX-A (Botox Allergan®, Irvine, CA, USA. 100 U vacuum-dried powder in a single-use vial for reconstitution diluted in 2 mL of sterile saline) was injected using a 30 G needle insulin syringe after performing the same measures of anaesthesia and disinfection [16]. The solution was injected into the body of the scar until slight blanching was clinically visible. The BTX-A dosage was adjusted to 2.5 U per cubic centimeter of the lesion, but did not exceed 100 U per patient in one injection [17].

Assessment

The improvement of the scars was evaluated through: The physician measured the scar using Vancouver scar scale, comparing pretreatment and posttreatment clinical photographs using a quartile grading scale; slight improvement (1% to 25% improvement), moderate (25% to 50% improvement), significant (50% to 75% improvement), marked (75% to 100% improvement) [18,19]. An independent physician evaluator assessed the results after treatment using the quartile grading scale. The patients were asked to scale their subjective satisfaction; satisfied or not satisfied. Side effects and complications were also recorded.

Statistical analysis

Data were fed to the computer and analyzed using IBM SPSS software package version 20.0. (Armonk, NY: IBM Corp) Qualitative data were described using number and percent [20]. The Kolmogorov-Smirnov test was used to verify the normality of distribution. Quantitative data were described using range (minimum and maximum), mean, standard deviation and median. The level of significance (p value) was 0.05. Results were statistically significant, if p value was less than 0.05. Standardized photographs were performed using the same digital camera set at a fixed distance from the patient's lesion and were taken before every session and one month after the final session for three months. All subjects involved in the current work were informed about the nature and the details of the work, a written consent and an approval by ethical committee were obtained.

Results

In the present study, the percentage of improvement in the VSS in group A was 84.47% ± 14.34% and the score improved from (9.80 ± 1.28 points; pretreatment) to (1.55 ± 1.47 points; post treatment), while in group B the improvement was 72.71% ± 14.60% with the score improved from (9.50 ± 1.85 points; pretreatment) to (2.55 ± 1.39 points; post treatment), the improvement between the two studied groups after treatment was significant with better results in group A (P value=0.023) (Figure 1).

Analysis of the subscales of the VSS (vascularity, pliability,

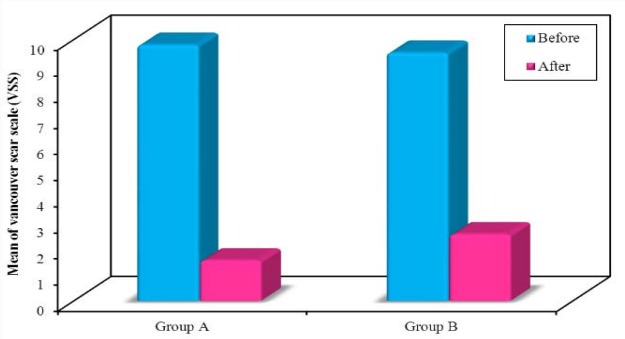

Figure 1: Improvement in the VSS at the end of the study.

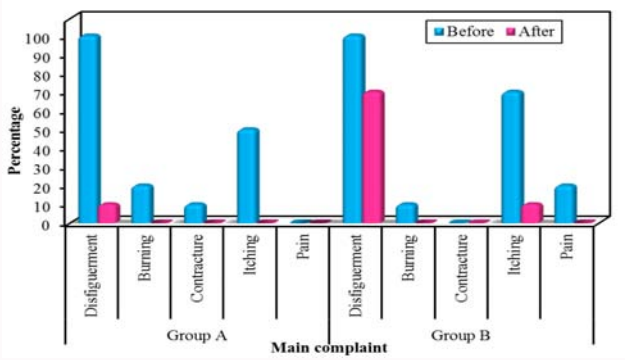

Figure 2: Clinical improvement at the end of the study.

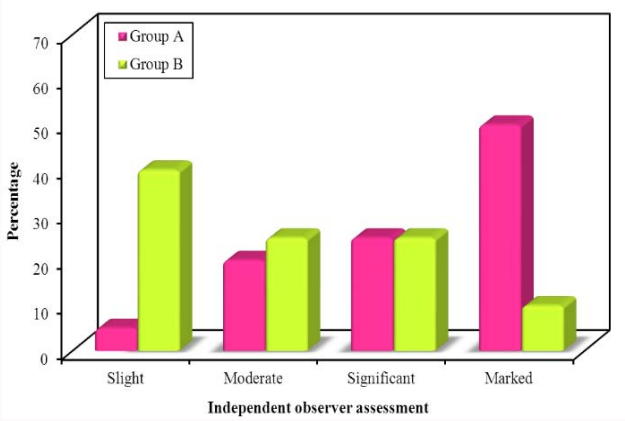

Figure 3: Independent observer assessment after 3 months follow up.

height and pigmentation) showed improvement in both groups after treatment. The difference between the two groups was statistically significant with better results reported in group A as regards scar vascularity (p=0.013), height (p=0.035), pliability (p=0.028) and pigmentation (p=0.045).

According to clinical improvement, In group A, out of the twenty patients complained of cosmetic disfigurement, 18 patient were satisfied with their cosmetic result and 2 still complaining, 10 patients complained of itching, 4 patients complained of burning sensation and 2 patients complained of contracture all of them completely improved. In group B, also all patients complained of cosmetic disfigurement, 14 still complaining, out of the 14 patients complained of itching 2 of them still complaining, 4 patients complained of pain and 2 patients complained of burning sensation, all of these

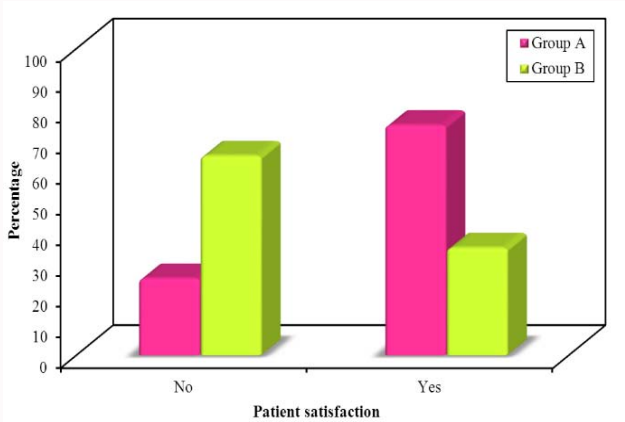

Figure 4: Patient satisfaction after 3 months follow up.

Figure 5: Marked improvement after CST + dermapen.

complaints improved. There was statistical significance difference between the two studied groups after treatment as regards cosmetic outcome ($p < 0.001$) with better results in group A (Figure 2).

The degree of improvement was reported 3 months after the last session of treatment by independent observer (according to Quartile grading system). Although all patients in the study improved by variable degrees, group A showed much better results than group B which was statistically significant (p value=0.011) (Figure 3), as regards patient satisfaction; In group A, 15 patients were satisfied with the treatment result and 5 patients were not satisfied, While In group B, 7 patients were satisfied with the treatment result and 13 patient were not satisfied. There was statistically significant difference between the two groups according to patient satisfaction (P=0.011) (Figure 4).

In the current study, No major adverse effects were observed among both groups, there was no statistically significant differences between the two groups according to pain following sessions, atrophy, dyschromia, scar reccurene or infection.

Discussion

Scar formation is an inevitable consequence of wound healing from either a traumatic or a surgical intervention in which the normal skin is replaced by a fibrous tissue, although Scar formation is beneficial in wound healing, it can lead to cosmetic problems, psychological and financial issues [10].

Figure 6: Marked improvement after CST + dermapen.

Figure 7: Significant improvement after BTX-A.

To the best of our knowledge, the present study is the first to combine needling technique with intralesional corticosteroid injection and compare its efficacy with intralesional botulinum toxin A injection, it was carried out on forty patients randomly divided into two groups (A, B). Each group included 20 patients. Group A were subjected to three sessions of microneedling treatment by automated microneedling device (Dermapen 3™) followed by intralesional injection of triamcinolone acetonide in the same session at one month interval, Whereas Group B were subjected to three sessions of intralesional injection of BTXA at one month interval.

All patients in the present study showed improvement, which was clearly higher in group A than that reported in group B based on Vancouver Scar Scale (VSS) (P value=0.023). The percentage of improvement in group A was 84.47% ± 14.34% while in group B was 72.71% ± 14.60%. All subscales of the VSS (vascularity, pliability, height and pigmentation) showed improvement in both groups after treatment. The difference between the two groups was significant with better results reported in group A.

In the present study as regards clinical improvement, There was no significant difference between the two studied groups except for the cosmetic improvement which was higher in group A (p<0.001), all patient's complaint (itching, burning and pain) had improved in both groups after treatment, this was in agreement with Shaarawy et al., [21], who compared IL-BTA with IL-CST in patients with keloids. Hardness, elevation, and redness, together with itching, pain, and tenderness were all improved in the two groups with no significant

Figure 8: Slight improvement after BTX-A.

difference. The itching score improved from (1-3, 2.25 ± 0.866) before treatment to (0-1, 0.25 ± 0.492) after treatment. However, the additional use of microneedling in the present study may be contributed to the better results achieved.

These results were in agreement with Aust et al., [22], who used micro-needling in patients with post-burn scars after preparation with topical vitamin A and C to maximize collagen production. Those patients reported clinical improvement in scar appearance. Histologic analysis of 3 mm punch biopsies at 1 year demonstrated an increase in collagen and elastin deposition. Dunkin et al., [23], used microneedling (a spring-loaded derma-stamp) together with topical preparations for hypertrophic scars. Scars were reduced more than 60% of their height with an average of 3 mm of shrinkage; the % of improvement was about 75%. Better results in group A in the present study may be due to the additional effect of IL-CST.

The beneficial role of CST in treatment of HTSs was documented by Margaret et al., [24], Ahuja and Chatterjee, who conducted two separate studies to compare the efficacy of CST (triamcinolone acetonide) to calcium channel blockers (verapamil), there was reduction in scar vascularity, pliability and height (measured using VSS), width and height (measured using centimeter scale), although scar pigmentation was not changed desirably in either studies with hypopigmentation or hyperpigmentation noticed in some patients treated with CST, this may demonstrate the role needling technique in improvement of scar pigmentation in the current study (Figure 5 and 6) [25].

The benefits of the combined modality in the present study was in agreement with Lee et al., [26], who reported significant improvement in depth and volume of 20 keloids treated with a combination of intralesional TAC and IFN alfa-2b compared with a non significant improvement obtained in another 20 keloids treated with TAC alone, also Connell et al., [27], who used a combined treatment of Pulsed Dye Laser (PDL) and intralesional steroid for recalcitrant keloid, The height of the scars being improved by 60%, erythema improved by 40%, and pain/itching by 75%. PDL facilitated steroid injection by making the scar edematous and therefore softer.

Beltraminelli et al., [28], compared the characteristics of microscopic treatment zones induced by ablative fractional CO_2 laser and by microneedle treatment in ex vivo human breast skin. While both methods induced minimally invasive sites needed for autologous cell therapy, the CO_2 laser resulted in superficial, epidermal papillary dermis defects of 0.1 mm to 0.3 mm covered by a thin eschar coated

with denatured collagen. In contrast, the microneedle intervention produced thin vertical skin fissures reaching up to 0.5 mm into the mid-dermis and injuring dermal blood vessels but without surrounding tissue necrosis. Both technologies created small epidermal defects which allow delivery of isolated cells such as melanocyte transplantation for vitiligo, with microneedle treatment having the advantage of lacking devitalized tissue and enabling vascular access for transplanted cells.

As regards BTX-A, Results of the present study was in accordance with Elhefnawy et al., [29], who used intralesional botulinum toxin type A as monotherapy. Erythema and pliability were graded on a 5-point scale as follows, 0: no erythema/pliability, 1: mild, 2: moderate, 3: severe, or 4: very severe. Erythema improved from (3.2 ± 0.78) pretreatment to (1.0 ± 0.66) post treatment, pliability was (3.3 ± 0.48) pretreatment then became (0.80 ± 0.42) post treatment, the itching score decreased from 3.50 to 0.83, also Xiao et al., [17], who treated 19 patients with hypertrophic scars with IL-BTA, The pliability score decreased from 3.85 to 0.78, In contrast, Gauglitz et al., [30], injected BTA into keloids. Differences in height and volume were evaluated clinically and measured with a 3-D optical profiling system it show that BTX did not change the macroscopic appearance, morphology or size of these scars (Figure 7 and 8).

In the present study as regards patient satisfaction; the results showed more satisfaction in group A than in group B (P=0.011). This was in agreement with Aust et al., [22], improvement was rated by the patients in his study was 80% better than before treatment with microneedling, Shaarawy et al., [21], showed that (50%) of patients in group A with IL-CST were highly satisfied, (42%) were satisfied, and (8%) were unsatisfied with their results, while (75%) of patients in group B with IL-BTA were highly satisfied, and (25%) were satisfied with their results, they reported rapid amelioration of the subjective complaints (itching, pain and allodynia), the higher doses of BTXA used in the previous study (5 IU/cm^3) in comparison to (2.5 IU/cm^3) used in group B in the current study may be the cause of the different results, also the additional use of microneedling in group A in the present study gave marked patient satisfaction especially in the cosmetic outcome.

As regard complication in the present study, all patients tolerated the procedure well. No major adverse effects were observed. The most common side effects noted in the immediate post-treatment period in all patients in group A were a transient minimal pain and mild transient erythema that resolved 1 to 2 days post-treatment. These results were in agreement with El-Domyati et al., [31], who reported slight pain and transient erythema after microneedling that were completely resolved 1 to 2 days post-treatment.

Also Shaarawy et al., [21], stated that a favorable aspect for the use of IL-BTA is the complete absence of side effects. On the other hand, the significantly higher cost of the IL-BTA is a drawback that could limit the use of this line of therapy as a routine.

Conclusion

The present study revealed that when microneedling was combined with intralesional CST the degree of improvement was clearly higher than that reported in intralesional BTA with no significant adverse effects were reported. Larger sample size and longer follow-up period would have given a better evaluation but was not feasible due to the high expenses involved.

Acknowledgements

Thanks to the Department of Dermatology and Andrology, Alexandria University, Egypt.

References

1. Tredget EE, Nedelec B, Scott PG, Ghahary A. Hypertrophic scars, keloids, and contractures. The cellular and molecular basis for therapy. Surg Clin North Am. 1997;77(3):701-30.
2. Shaffer JJ, Taylor SC, Cook-Bolden F. Keloidal scars: a review with a critical look at therapeutic options. J Am Acad Dermatol. 2002;46(2):S63-97.
3. Aoki K. Pharmacology, immunology and current developments. 1st ed. In: Benedetto A, editors. Botulinum Toxin in Clinical Dermatology. UK: Taylor and Francis; 2006. p. 16-35.
4. Jalali M, Bayat A. Current use of steroids in management of abnormal raised skin scars. Surgeon. 2007;5(3):175-80.
5. Leclère FM, Mordon SR. Twenty-five years of active laser prevention of scars: what have we learned? J Cosmet Laser Ther. 2010;12(5):227-34.
6. Falabella AF, Falanga V. Wound healing. In: Freinkel RK, Woodley DT, editors. The Biology of the Skin. New York: Parethenon; 2001. p. 281-99.
7. Wein AJ, Kavoussi LR, Novick AC, Partin AW, Peters CA. Campbell Walsh Urology : expert consult premium edition: enhanced online features and print, 4-volume set. 10th ed. Amsterdam: Elsevier Health Sciences; 2011:704.
8. Liebl H, Kloth LC. Skin cell proliferation stimulated by microneedles. J Am Coll Clin Wound Spec. 2012;4(1):2-6.
9. Niessen FB, Spauwen PH, Schalkwijk J, Kon M. On the nature of hypertrophic scars and keloids: a review. Plast Reconstr Surg. 1999;104(5):1435-58.
10. Mustoe TA, Cooter RD, Gold MH, Hobbs FD, Ramelet AA, Shakespeare PG, et al. International clinical recommendations on scar management. Plast Reconstr Surg. 2002;110(2):560-71.
11. Naumann M, So Y, Argoff CE, Childers MK, Dykstra DD, Gronseth GS, et al. Assessment: Botulinum neurotoxin in the treatment of autonomic disorders and pain (an evidence-based review): report of the Therapeutics and Technology Assessment Subcommittee of the American Academy of Neurology. Neurology. 2008;70(19):1707-14.
12. Aoki KR. Botulinum toxin: a successful therapeutic protein. Curr Med Chem. 2004;11(23):3085-92.
13. Xiao Z, Qu G. Effects of botulinum toxin type a on collagen deposition in hypertrophic scars. Molecules. 2012;17(2):2169-77.
14. Singh A, Yadav S. Microneedling: Advances and widening horizons. Indian Dermatol Online J. 2016;7(4):244-54.
15. Arora S, Gupta PB. Automated microneedling device-a new tool in dermatologist's kit-a review. J Pak Med Assoc. 2012;22(4):354-7.
16. BOTOX® Onabotulinumtoxina Injection. Botox® Reconstitution and Dilution Procedures. Ireland: Allergan, Inc; 2015.
17. Xiao Z, Zhang F, Cui Z. Treatment of hypertrophic scars with intralesional botulinum toxin type A injections: a preliminary report. Aesthetic Plast Surg. 2009;33(3):409-12.
18. Baryza MJ, Baryza GA. The Vancouver Scar Scale: an administration tool and its interrater reliability. J Burn Care Rehabil. 1995;16(5):535-8.
19. Leheta T, El Tawdy A, Abdel Hay R, Farid S. Percutaneous collagen induction versus full-concentration trichloroacetic acid in the treatment of atrophic acne scars. Dermatol Surg. 2011;37(2):207-16.
20. Kirkpatrick LA, Feeney BC. A simple guide to IBM SPSS statistics for version 20.0. Student ed. Belmont, Calif.: Wadsworth, Cengage Learning; 2013. p. 128.

21. Shaarawy E, Hegazy RA, Abdel Hay RM. Intralesional botulinum toxin type A equally effective and better tolerated than intralesional steroid in the treatment of keloids: a randomized controlled trial. J Cosmet Dermatol. 2015;14(2):161-6.

22. Aust MC, Knobloch K, Reimers K, Redeker J, Ipaktchi R, Altintas MA, et al. Percutaneous collagen induction therapy: an alternative treatment for burn scars. Burns. 2010;36(6):836-43.

23. Chambers A. Unified Approach to the Treatment of Hypertrophic and Atrophic Scars: A Pilot Study. AJCS. 2016;33(4):176-83.

24. Margaret Shanthi FX, Ernest K, Dhanraj P. Comparison of intralesional verapamil with intralesional triamcinolone in the treatment of hypertrophic scars and keloids. Indian J Dermatol Venereol Leprol. 2008;74(4):343-8.

25. Ahuja RB, Chatterjee P. Comparative efficacy of intralesional verapamil hydrochloride and triamcinolone acetonide in hypertrophic scars and keloids. Burns. 2014;40(4):583-8.

26. Lee JH, Kim SE, Lee AY. Effects of interferon-alpha2b on keloid treatment with triamcinolone acetonide intralesional injection. Int J Dermatol. 2008;47(2):183-6.

27. Connell PG, Harland CC. Treatment of keloid scars with pulsed dye laser and intralesional steroid. J Cutan Laser Ther. 2000;2(3):147-50.

28. Beltraminelli H, Dietrich N, Hunziker T. Fractional transepidermal delivery: a histological analysis. Dermatology. 2011;223(4):321-4.

29. Elhefnawy AM. Assessment of intralesional injection of botulinum toxin type A injection for hypertrophic scars. Indian J Dermatol Venereol Leprol. 2016;82(3):279-83.

30. Gauglitz GG, Bureik D, Dombrowski Y, Pavicic T, Ruzicka T, Schauber J. Botulinum toxin A for the treatment of keloids. Skin Pharmacol Physiol. 2012;25(6):313-8.

31. El-Domyati M, Medhat W. Minimally invasive facial rejuvenation: current concepts and future expectations. Expert Rev Dermatol. 2013;8(5):565-80.