



Monophasic Retroperitoneal Synovial Sarcoma: 3 Cases Reports

Diakité K*, Bouzid N, Darfaoui M, Zabroug S, Eddaoualine H, Lalya I, Kouchani M, El Omrani A and Bendouro H

Onco-radiotherapy service of Mohamed VI University Hospital of Marrakech, Morocco

Abstract

Retroperitoneal synoviosarcoma is a rare entity. WHO distinguishes three morphological forms: biphasic, monophasic and poorly differentiated. Surgery with R0 resection is the mainstay of treatment; Adjuvant radiotherapy and or chemotherapy often indicated to reduce recurrence risk. We report 3 cases of retroperitoneal synoviosarcoma.

Keywords: Synovial sarcoma; Retroperitoneal; Tumour; Surgery; Radiotherapy, Chemotherapy

Introduction

Synoviosarcoma is a mesenchymal soft tissue malignancy, affecting adolescents and young adults. The origin of this tumor remains unknown. It accounts for 5% to 10% of all soft tissue sarcomas [1]. The usual localization is mostly the extremities, particularly the lower limb around the knee, which is the most common localization [2]. Abdominal synoviosarcoma remains one of the rarest localizations.

Surgery is the mainstay of treatment; the goal is to have negative excision margins [3]. Unfortunately, most tumors are diagnosed at locally advanced stages. To optimize chances of R0 resection, neoadjuvant radiotherapy may be indicated [4]. Given the aggressive nature of the tumor. Chemotherapy may be indicated in an adjuvant setting or, more often, palliatively [5].

Case Presentation

Case 1

A 42-year-old woman consulted at the general surgery department for loss of consciousness associated with chest pain. The patient benefited from a fragmented partial resection for a para-aortic mass (coeliac pedicle level). A postoperative CT scan showed (Figure 1) a heterogeneous pre aortic remained mass (6 cm × 4 cm) that was evaluated to be unresectable, it was decided to begin a palliative chemotherapy (Adriamycin + Ifosfamide), and at the last follow-up the patient progressed locally after the 6th cycle and is intended for a second line chemotherapy.

Case 2

58-year-old woman consults for abdominal pain associated with abdominal swelling evolving for more than a year. The CT scan showed a solidocystic retro pancreatic mass of 17 mm in diameter. She underwent a R2 fragmented surgery. The patient has had adjuvant chemotherapy with Adriamycin and Ifosfamide with radiological stabilization.

Case 3

A male teenager of 15 years presents with abdominal pain with limping. CT scans showed (Figure 2) a large retroperitoneal mass of the left iliac fossa infiltrating the spine and psoas muscle. The surgical procedure consisted in a partial resection (R2) with 45Gy adjuvant radiotherapy. Unfortunately the patient was lost to follow up.

Discussion

Soft tissue sarcomas are most commonly seen in the extremities (59%), the trunk (19%), the retroperitoneum (15%) and the head and neck (9%) [2]. Primary intra-abdominal synoviosarcoma is rare and most cases are retroperitoneal. Morphologically, they are subclassified as biphasic, monophasic (with fibrous and epithelial component) and poorly differentiated. The poorly differentiated synoviosarcoma may show morphology of large cells, small cells, or high-grade fusiform cells [6].

OPEN ACCESS

*Correspondence:

Diakite Kadiatou, Onco-radiotherapy
Service of Mohamed VI University
Hospital of Marrakech, Morocco,
E-mail: diakite.kadiatou.dk@gmail.com

Received Date: 10 Jan 2019

Accepted Date: 08 Feb 2019

Published Date: 12 Feb 2019

Citation:

Diakité K, Bouzid N, Darfaoui M,
Zabroug S, Eddaoualine H, Lalya
I, Kouchani M, et al. Monophasic
Retroperitoneal Synovial Sarcoma: 3
Cases Reports. Ann Radiat Ther Oncol.
2019; 2(1): 1017.

Copyright © 2019 Diakité K. This is an
open access article distributed under
the Creative Commons Attribution
License, which permits unrestricted
use, distribution, and reproduction in
any medium, provided the original work
is properly cited.

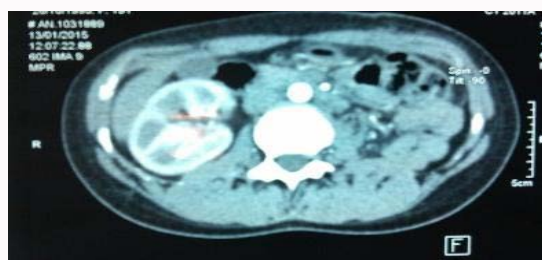


Figure 1: A postoperative CT scan showed a heterogeneous pre aortic remained mass.

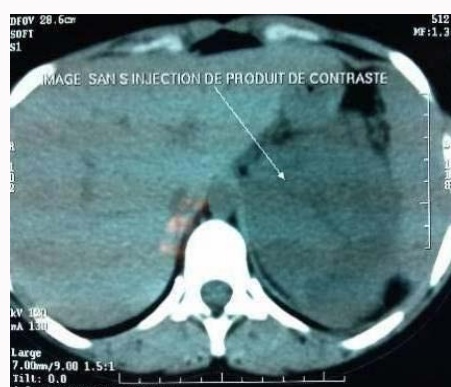

Figure 2: CT scans showed a large retroperitoneal mass of the left iliac fossa infiltrating the spine and psoas muscle.

Because of their size and intra-abdominal location, retroperitoneal synovial sarcoma can be confused with other fusiform cell neoplasms such as fibrosarcomas in adults, fibrous solitary tumors [7], PNET (peripheral neuro-ectodermic tumor), leiomyosarcoma, sarcomatous mesothelioma and GIST (Gastro-intestinal stromal tumor) [8,9]. Monobloc Surgery with negative resection margins of at least 1 cm without compromising the quality of life will be the goal. This surgery can only be validated if the feasibility has been well defined by carrying out the appropriate assessments in a pluridisciplinary consultation meeting. If not, the procedure should be limited to a diagnostic biopsy, neoadjuvant radiotherapy or chemotherapy may be indicated in order to improve the chances to R0 resection. Radiotherapy could be indicated in neoadjuvant situation in order to increase resectability chances, or as exclusive treatment when the tumor is evaluated to be irresectable or if surgery is too risky in a multi morbid patient, or as adjuvant treatment after incomplete resection, a high grade tumor or a tumor size greater than 5 cm, or as palliative radiation therapy.

Retroperitoneal radiotherapy planning is quite difficult; due to the large extent of the treatment field and the tolerance of the surrounding structures. The combination of high-dose radiotherapy and complete excision improves local control without gain in survival [10]. Willet reports an increase in the rate of resectability (70% of cases) and a 4 years local control rate of 81% after radiotherapy [11]. The dose of radiation therapy varies depending on the indication and localization of the tumor and dose constraints to adjacent organs at risk.

Several adjuvant systemic therapy protocols were tested to reduce

the risk of metastatic spread after surgery with or without radiotherapy in randomized controlled trials [5] based on anthracycline regimens using doxorubicin as the main chemotherapeutic agent in early studies, while more recent ones have tested anthracycline associated with ifosfamide [12].

Because synovialsarcoma is high-grade malignancy, it is characterized by local invasion and high metastatic potential especially in lung. At the time of diagnosis, less than 10% of cases present with metastases, but metastatic dissemination may occur in 25% to 50% of cases.

Conclusion

The diagnosis is based on anatomopathological analysis and immunohistochemistry. The standard treatment remains monobloc R0 surgery. The prognosis remains pejorative. The quality of initial management directly impacts the recurrence free survival and overall survival. The multidisciplinary management and the coordination with a sarcoma center are necessary.

References

1. Sultan I, Rodriguez-Galindo C, Saab R, Yasir S, Casanova M, Ferrari A. Comparing children and adults with synovial sarcoma in the surveillance, epidemiology, and end results program, 1983 to 2005: an analysis of 1268 patients. *Cancer*. 2009;115(15):3537-47.
2. Enzinger FM, Weiss SW. Soft tissue tumor. St Louis: Mosby; 1995.
3. Gladdy RA, Gupta A, Catton CN. Retroperitoneal sarcoma: fact, opinion, and controversy. *Surg Oncol Clin N Am*. 2016;25(4):697-711.
4. Larrier NA, Czito BG, Kirsch DG. Radiation therapy for soft tissue sarcoma: indications and controversies for neoadjuvant therapy, adjuvant therapy, intraoperative radiation therapy, and brachytherapy. *Surg Oncol Clin N Am*. 2016;25(4):841-60.
5. Casali PG. Adjuvant chemotherapy for soft tissue sarcoma. *Am Soc Clin Oncol Educ Book*. 2015:e629-33.
6. Weiss SW, Goldblum JR, editors. Malignant soft tissue tumors of uncertain type. Enzinger & Weiss's soft tissue tumors. China: Mosby Elsevier; 2008. p.1161-82.
7. Fisher C, Folpe AL, Hashimoto H, Weiss SW. Intra-abdominal synovial sarcoma: A clinicopathological study. *Histopathology*. 2004;45(3):245-53.
8. Chan JK. Solitary fibrous tumour—everywhere, and a diagnosis in vogue. *Histopathology*. 1997;31(6):568-76.
9. Miettinen M, Monihan JM, Sarlomo-Rikala M, Kovatich AJ, Carr NJ, Emory T, et al. Gastrointestinal stromal tumors/smooth muscle tumors (GISTs) primary in the omentum and mesentery: clinicopathologic and immunohistochemical study of 26 cases. *Am J Surg Pathol*. 1999;23(9):1109-18.
10. Sindelar WF, Kinsella TJ, Chen PW, DeLaney TF, Tepper JE, Rosenberg SA, et al. Intraoperative radiotherapy in retroperitoneal sarcomas. Final results of a prospective, randomized, clinical trial. *Arch Surg*. 1993;128(4):402-10.
11. Willett CG, Suit HD, Tepper JE, Mankin HJ, Convery K, Rosenberg AL, et al. Intraoperative electron beam radiation therapy for retroperitoneal soft tissue sarcoma. *Cancer*. 1991;68(2):278-83.
12. Pervaiz N, Colterjohn N, Farrokhyar F, Tozer R, Figueredo A, Ghert M. A systematic meta-analysis of randomized controlled trials of adjuvant chemotherapy for localized resectable soft-tissue sarcoma. *Cancer*. 2008;113(3):573-81.