Oncology Case Reports Journal

Research Article
Published: 21 Sep, 2020

# Minimally Invasive Breast Surgery: A Single Incision Approach for Early Breast Cancer Treatment - A Descriptive Analysis of 94 Cases

***Silvio Eduardo Bromberg[1]*, Patricia RA Figueiredo Moraes[2], Paulo Gustavo Tenório do Amaral[1] and Dafne Raca Bromberg[3]***

*[1]Oncology Center, Hospital Israelita Albert Einstein, Brazil*

*[2]Women's Health Reference Center, Hospital Perola Byington, Brazil*

*[3]Faculty of Medical Sciences of Santa Casa de São Paulo, Brazil*

## Abstract

**Background:** The objective of this study is to describe the feasibility of a minimally invasive surgical approach to treat early breast cancer.

Breast-conserving surgery has become the standard of care for early breast carcinoma. The majority of cases, the traditional approach to conservative surgery require two incisions (over the tumor and axillary). It leaves more scars and patients whose sexual organs have cosmetic defects have to cope with social impacts and experience a loss in quality of life. The minimally invasive surgical approach re-moves the breast tumor and sentinel lymph node biopsy through a single incision.

**Methods:** We retrospectively selected 94 patients with early breast cancer treated with breast conserving surgery through a single incision between January 2015 and December 2018. All patients approved of its use because they were cosmetically satisfied with their breasts, and preferred to have as little scarring as possible. The following data were collected: Number of dissected sentinel lymph nodes, breast tissue volume removed, tumor location, incision site, time of surgery and histopathological reports.

**Results:** Among the analyzed cases, the median age of 55 years. The mean volume of the surgical specimen removed was 15.9 $cm^3$. In average, 3.6 lymph nodes were resected and the mean time of surgery was 2 h and 40 min. The type of incision was statistically associated with tumor location ($p<5\%$). There was no need to re operate anyone.

**Conclusions:** The single surgical incision technique is feasible and reinforces the oncoplastic concept in breast cancer treatment.

**Keywords: Breast cancer; Breast conserving surgery; Minimally invasive; Technique**

**OPEN ACCESS**

****Correspondence:***
*Silvio Eduardo Bromberg, Oncology Center, Hospital Israelita Albert Einstein, 627 Albert Einstein Av. Office A1 number 122 Morumbi - São Paulo, Brazil, Tel: +55 11 21515122; E-mail: sbromberg@einstein.br*

**Received Date**: *29 Aug 2020*
**Accepted Date***: 16 Sep 2020*
**Published Date***: 21 Sep 2020*

***Citation:***
*Bromberg SE, Figueiredo Moraes PRA, Tenório do Amaral PG, Bromberg DR. Minimally Invasive Breast Surgery: A Single Incision Approach for Early Breast Cancer Treatment - A Descriptive Analysis of 94 Cases. Oncol Case Report J. 2020; 3(2): 1025.*



## Introduction

Breast surgery remains the cornerstone of breast cancer treatment. In the early days, breast cancer surgery was an aggressive procedure associated with severe and incapacitating comorbidities and unfavorable aesthetic results. Over the years, concomitant with the evolution of local and systemic treatments like radiotherapy, chemotherapy and endocrine therapy, advances in breast cancer surgery resulted in smaller dissected volumes, fewer comorbidities and better cosmetic outcomes [1,2].

Today, breast-conserving surgery associated with sentinel node biopsy has become the standard of care for early breast carcinoma. Large trials have demonstrated that this approach leads to fewer surgical complications and rates of overall survival that are equivalent to those of radical mastectomy [3,4].

The breast-conserving surgery technique has changed a long time [5]. Currently, in the majority of cases, the traditional approach to conservative surgery requires two incisions; one over the tumor and another in the axillary. Although it is considered to be an approach with good recovery rates and few surgical complications, it leaves more scars and sometimes causes cosmetic defects that may distort the breast anatomy. Breast cancer patients whose sexual organs have cosmetic defects

have to cope with social impacts and consequently experience a loss in quality of life [6,7].

With the aim of reducing the number of scars and providing better cosmetic results we decided to perform what we named a minimally invasive surgical technique.

This approach differs from the conventional breast conserving surgery technique because it re-moves the breast tumor and sentinel lymph node biopsy through a single incision [8,9].

The objective of this study is to describe the feasibility and oncological safety of this approach.

## Materials and Methods

From our Clinical Data Base we randomly and retrospectively selected 94 patients with early breast cancer (invasive breast cancer measuring no more than 30 mm and negative clinically axillary) that were treated with breast conserving surgery through a single incision between January 2015 and December 2018. All patients had medical records collected with the main clinical data (age, comorbidities, exams, type of surgery performed, and histological reports). For the analysis, the following data were collected: Number of dissected sentinel lymph nodes, breast tissue volume removed, tumor location, incision site, time of surgery and histopathological reports. All patients received radiotherapy treatment, some of them around 30 days after the surgery and others during the surgery (intra-operative radiotherapy).

The study selected only patients with early stage breast cancer diagnosis who were submitted to a breast conserving surgery with an inframammary, periareolar or axillary single incision based on the minimally invasive technique approach. After the surgical technique was explained to them, all patients approved of its use because they were cosmetically satisfied with their breasts, did not wish to undergo a bilateral plastic breast surgery and preferred to have as little scarring as possible. All patients who gave their permission to this approach signed a consent form. All surgeries were carried out by the same surgical team and at the same hospital.

### Surgical technique

Initially the patients underwent tumor and sentinel lymph node staining at the nuclear medicine department with Tc99m around the tumor and sometimes under the areola, approximately 4 h before the surgical procedure.

The incision approach was chosen in accordance with tumor location. The infra-mammary fold incision was selected for inferior quadrants or lateral quadrants or medial tumor location. Axillary incision was used when the tumor was in the upper quadrants location and when the areolar diameter was less than 3 cm and finally, periareolar incision was chosen for upper quadrants or lateral tumor location and areolar diameter larger than 3 cm. (Figure 1 and 2).

Once the approach was determined, dissection was performed using a mono-polar electric scalpel and wound retractor [10]. A periareolar incision involving half of the areola, or a 4 cm to 7 cm inframammary incision or small axillary incision was used, always in accordance with tumor location and areolar diameter.

After the surgical incision, the skin was dissected through the superficial fascia and the wound retractor was used to protect the skin [10]. The gland tissue was dissected with the long and light valves and the lesion area was demarcated with the probe; next, the tumor was removed and the cavity shaved.

All surgeries were followed by the pathologist who analyzed the tumor margins with a freezing examination. After free margins were confirmed, the surgery preceded with dissection of the clavipectoral fascia and removal of the sentinel(s) lymph node(s), which was/were detected by the gamma probe. When needed, axillary lymph nodes in level I and II were dissected through the same incision. After this, we proceeded with hemostasis, drain placement and wound closure. All patients were followed for postoperative care, once a week during the first month; 45 days after the surgery and once every 3 months during the first year. After the first year all patients were followed every 6 months for 4 years. Patients who did not receive intra operative radiotherapy were submitted to conventional radio-therapy around 45 days after the surgery.

Intraoperative radiation was delivered *via* Zeiss intrabeam (Carl Zeiss Meditec AG, Germany). The X-ray system produces low-energy photons (30 KVp to 50 KVp) with a steep dose fall-off in soft-tissue. Dosimetry varied by applicator tip size. The most commonly used applicator was the 3.5 cm applicator sphere delivering 20 Gy at a radius of 1 mm from the surface and 5 Gy at 10 mm and 1 Gy at 27 mm in about 20/30 min, depending on the case.

Whole breast irradiation was achieved with a total dose of 45 Gy to 50 Gy delivered to the entire breast over 5 to 6 weeks (1.8 Gy to 2 Gy per fraction) in addition to a boost dose of 10 Gy to 16 Gy to the tumor bed.

### Data analyses

Numerical variables were described by means, standard deviations, interquartile ranges and minimum and maximum values. The variables categories were described in absolute frequencies and percentages. The variables location, volume of the surgical specimen and number of lymph nodes were compared in relation to the type of incision. For variables, when the variable presented normal distribution, the ANOVA test was used to compare the means of the groups. When distribution of the variable was asymmetric, the Kruskal-Wallis test was used. Fisher's test was applied to categorical variables. The analyses were performed with the R statistical package intersection and considering a significance level of 5%.

## Results and Discussion

Among the 94 cases analyzed, the median age was 55 years and the distribution was slightly asymmetric, with a higher concentration of values above the median. The age ranged from 26 to 87 years.

As to the histopathological type of the tumor, most cases were invasive ductal carcinoma (71.3%), followed by *in situ* ductal carcinoma (20.2%) and invasive lobular carcinoma (8.5%) (Table 1). The most frequent tumor location was in the lateral superior quadrant (34.1%), followed by the union of lateral quadrants (21.6%). The lowest frequency was observed in the union of the medial quadrants (2.3%).

The mean volume of the surgical specimen removed was 15.9 $cm^3$, with a standard deviation of 11.7 $cm^3$. Table 2 shows other features present in the removed surgical piece volume. The median was 13.7 $cm^3$ and the volume ranged from 6 $cm^3$ to 60.6 $cm^3$. The points plotted above the box represent values that differ from what is expected for this sample. In this case, values above approximately 35 $cm^3$ were considered higher than expected.

In average, 3.6 lymph nodes were resected (standard deviation

**Table 1:** Pathological anatomy and tumor location.

| Characteristic | n (%) |
|---|---|
| **Pathologic anatomy** | |
| Invasive Ductal Carcinoma | 67 (71.3%) |
| *in situ* Ductal Carcinoma | 19 (20.2%) |
| Invasive Lobular Carcinoma | 8 (8.5%) |
| n | 94 |
| **Tumor Location** | |
| Infero lateral Quadrant | 5 (5.7%) |
| Infero medial Quadrant | 4 (4.5%) |
| Union of inferior Quadrants | 7 (8%) |
| Union of lateral Quadrants | 19 (21.6%) |
| Union of medial Quadrants | 2 (2.3%) |
| Union of superior Quadrants | 7 (8%) |
| Supero lateral Quadrant | 30 (34.1%) |
| Supero medial Quadrant | 7 (8%) |
| Retroareolar | 7 (8%) |
| n | 88 |

of 4.1). The minimum number was 1 lymph node and the maximum number 25 lymph nodes (Table 3). Removal of only 1 sentinel lymph node (35.2%) represented the highest frequency; and most patients were not submitted to axillary emptying (91.2%).

The mean time of surgery was 2 h and 40 min, remarkably close to the median (2 h and 45 min). The period ranged from 1 h and 20 min to 5 h of surgery (Table 4). Cases with longer surgeries, close to 5 h of total procedure, were due to the delivery of intraoperative radiotherapy; since the procedure time is added to the total period. In surgical procedures total time also included the time spent by the pathologist in the intraoperative analysis, i.e. freezing of the sector and lymph node analysis.

Table 5 shows the distribution by type of incision performed. Most of the incisions were periareolar, followed by the infra-mammary incision type. Axillary incision frequency was small in the sample (only 4.3%).

The type of incision was statistically associated with tumor location (p<5%). For example, for the axillary incision a higher frequency of tumors were in the quadrant superior lateral. For the periareolar incision, the highest frequency was also in the super lateral quadrant, followed by the retroareolar and union of lateral quadrants. In the case of an infra-mammary fold incision, higher frequency was observed in the union of lateral quadrants, followed by the super lateral quadrant, inferomedial and union of medial quadrants.

The volume of the removed surgical specimen showed different numerical values depending on the type of approach. The amount of glandular tissue (tumor and surrounding tissue) removed through the axillary incision was smaller than that obtained through the periareolar incision. The infra-mammary incision approach presented higher removed volume. However, there was insufficient evidence to indicate that the differences between the volumes removed based on the approach (periareolar, sulcus and axillary) were statistically insignificant (p>5%). Similarly, there was not any evidence that the number of lymph nodes removed was affected by the type of approach (p>5%).

**Table 2:** Association between incision and tumor location; volume of surgical specimen and number of lymph nodes removed.

| Variables | Incision Type | | | p-value |
|---|---|---|---|---|
| | Axillary (n=4) | Periareolar (n=47) | Sulcus (n=42) | |
| **LOCATION** | | | | |
| | 0 (0%) | 0 (0%) | 5 (12.5%) | 0.003 |
| Infero medial Quadrant | 0 (0%) | 1 (2.27%) | 3 (7.5%) | |
| Union of inferior Quadrants | 0 (0%) | 2 (4.55%) | 5 (12.5%) | |
| Union of lateral Quadrants | 0 (0%) | 7 (15.91%) | 12 (30%) | |
| Union of medial Quadrants | 0 (0%) | 2 (4.55%) | 0 (0%) | |
| Union of superior Quadrants | 0 (0%) | 2 (4.55%) | 5 (12.5%) | |
| Supero lateral Quadrant | 3 (75%) | 19 (43.18%) | 8 (20%) | |
| Supero medial Quadrant | 1 (25%) | 4 (9.09%) | 2 (5%) | |
| Retroareolar | 0 (0%) | 7 (15.91%) | 0 (0%) | |
| N | 4 | 44 | 40 | |
| **Surgical Piece Volume Removed** | | | | |
| Mean (SD) | 9.85 (6.8) | 14.82 (10.98) | 17.51 (12.64) | 0.375 |
| Median [Q1; Q3] | 13.55 [7.78; 13.78] | 13.00 [6.80; 20.85] | 14.90 [9.45; 18.25] | |
| Min; Max | 2.00; 14.00 | 0.64; 43.00 | 3.00; 60.60 | |
| N | 3 | 39 | 35 | |
| **Number of lymph nodes removed** | | | | |
| Mean (SD) | 4.75 (1.26) | 3.28 (3.37) | 3.98 (5.08) | 0.160 |
| Median [Q1; Q3] | 5.00 [4.50; 5.25] | 2.00 [1.00; 5.00] | 2.00 [1.00; 4.00] | |
| Min; Max | 3.00; 6.00 | 1.00; 19.00 | 1.00; 25.00 | |
| N | 4 | 46 | 40 | |

**Table 3:** Number of sentinel lymph nodes removed and axillary dissection.

| Number of lymph nodes removed | n (%) |
|---|---|
| 1 | 32 (35.2%) |
| 2 | 15 (16.5%) |
| 3 | 17 (18.7%) |
| 4 | 3 (3.3%) |
| 5 | 10 (11%) |
| 6 or more | 14 (15.4%) |
| N | 91 |
| Axillary Lymph Node Dissection | |
| No | 83 (91.2%) |
| Yes | 8 (8.8%) |
| N | 91 |

**Table 4:** Surgical time.

| Surgery time | Statistics |
|---|---|
| Mean | 02:40:28 |
| Median | 02:45:00 |
| Min.; Max. | 01:30:00; 05:00:00 |

**Table 5:** Distribution of incision location.

| Incision Location | n (%) |
|---|---|
| Axillary | 4 (4.3%) |
| Periareolar | 47 (50.5%) |
| Sulcus | 42 (45.2%) |
| n | 93 |


**Figure 1:** Axillary incision.

There was no need to re operate anyone for surgical margins or other reasons and no immediate or late complications occurred.

Today, the Breast Unit (Oncology Department), at the Albert Einstein Hospital diagnoses early breast cancer more frequently than advanced breast cancer, allowing for more conservative surgeries. It is well known that patients value safe surgical oncology treatment as much as good cosmetic surgery outcomes [11-13]. Consequently, we are always enhancing our knowledge and searching for better practices and surgical techniques that favor an oncoplastic approach, following global trends [14].

This oncoplastic mentality dates back to the Vrouwe et al. study, which revealed that the majority of women feel negatively affected by their breast cancer surgery scars. More than 60% of lumpectomy patients were not satisfied with their breast scars, did not like their surgery scars and more than this, preferred to have fewer and smaller scars [15,16]. We agree with the idea that reducing the number of scars is a practice consistent with patient's preferences.

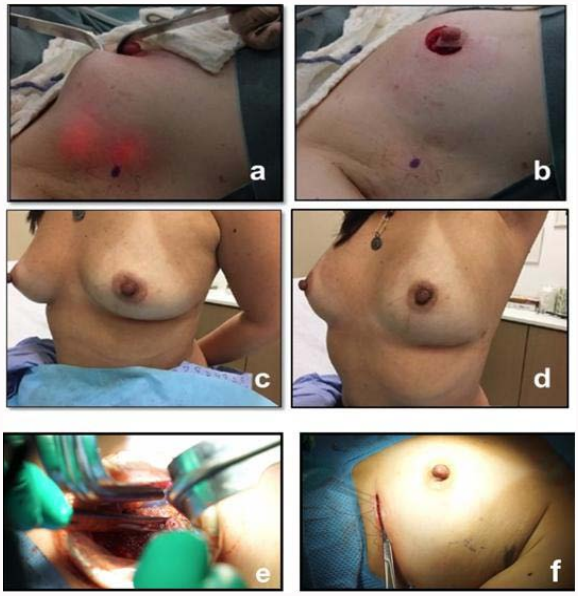


**Figure 2:** Periareolar incision (A and B) and Inframammary incision (C, D, E and F).

Guided by the oncoplastic concept, we propose this surgical approach through a single incision for the conservative treatment of early breast cancer patients who do not wish to undergo a bilateral breast plastic surgery and who are aesthetically satisfied with their breasts.

This study confirmed that the single-incision approach does not impair the ability to investigate the axillary lymph nodes axillary or the tumor removal with the surrounding tissue.

No patients had to be re-operated because free margins were achieved during the first approach in all cases. Furthermore, the single incision did not interfere with the amount of resected volume.

As for the axillary lymph nodes investigation, we could dissect the axillary lymph nodes (average of 3, 6 lymph nodes) without any difficulty. Besides the cases where the sentinel lymph nodes were dissected, axillary clearance in level I and II was performed in 8 cases through the unique incision.

Considering the time spent in surgery, better procedure times were obtained after a long learning curve. In spite of this, we consider our surgical time as suboptimal, because we believe, after carrying out many surgeries, that the absence of a second incision should be conducive to shorter surgery times. It is a fact that this type of approach provides for easier breast reassembly and only one skin suture. In our study, the median time was 2:40 min, but it is worth noting that intraoperative radiotherapy was delivered in some cases and additionally, that in some cases axillary lymph node dissection (level I and II) was performed, increasing regular surgical time. It is also necessary to include the time spent by the pathologist to analyze the tumor margins [17,18,19].

We believe that performing conservative surgeries through a single incision is possible and allows for good cosmetical and oncological outcomes. It is clear to us that this approach demands special training and specific materials (long valves, special glasses, good lighting, etc.), but it is well worth the effort.

This study has several limitations: It evaluated a limited number of patients as a retrospective series and lacked a group control. However, our endpoint was reached; all surgeries were feasible and showed oncological safety.

The next step is to compare this technique (one incision) with the "conventional" conserving surgery without bilateral plastic breast surgery (double incision) with an appropriate questionnaire for cosmetic evaluation and applying the same variables analyzed in this study.

This next study will show if we are in the right direction.

The single surgical incision technique is highly feasible and a good option to treat early breast cancer in cases where the patients are fully satisfied with their breasts and prefer not to undergo a bilateral plastic breast surgery during their surgical treatment. This minimally invasive approach reinforces the oncoplastic concept in breast cancer treatment.

## References


1. Gass J, Mitchell S, Hanna M. How do breast cancer surgery scars impact survivorship? Findings from a nationwide survey in the United States. BMC Cancer. 2019;19(1):342.
2. Losken A, Pinell-White X, Hodges M, Egro FM. Evaluating outcomes after correction of the breast conservation therapy deformity. Ann Plast Surg. 2015;74(Suppl 4):S209-13.
3. Lovasik BP, Seidel RL, Novello M, Torres MA, Losken A, Rizzo M. Single incision for oncologic breast conserving surgery and sentinel node biopsy in early stage breast cancer: A minimally invasive approach. Breast J. 2019;25(1):41-6.
4. Mok CW, Lai HW. Evolution of minimal access breast surgery. Gland Surg. 2019;8(6):784-93.
5. Canady JW, D'Amico RA, McGuire MF. Discussion. Oncoplastic breast surgery: Past, present, and future directions in the United States. Plast Reconstr Surg. 2009;124(3):973-4.
6. Bromberg SE, Giordano R. Prime incision and modified moving window: A minimally invasive access for breast cancer surgical treatment. World J Plast Surg. 2016;5(3):252-8.
7. Bromberg SE, Moraes PRAF, Ades F. Prime incision: A minimally invasive approach to breast cancer surgical treatment-A cohort retrospective comparison with conventional breast conserving surgery. PLoS One. 2018;13(1):e0191056.
8. Al-Ghazal SK, Blamey RW, Stewart J, Morgan AA. The cosmetic outcome in early breast cancer treated with breast conservation. Eur J Surg Oncol. 1999;25(6):566-70.
9. Thompson TA, Pusic A, Kerrigan CL, Sargeant R, Slezak S, Chang BW, et al. Surgeon perspectives on surgical options for early-stage breast cancer. Plast Reconstr Surg. 2000;105(3):910-8.
10. Greenberg JA. Alexis® O C-section retractor. Rev Obstet Gynecol. 2008;1(3):142-3.
11. Jay M, Creelman B, Baliski C. Patient reported outcomes associated with surgical intervention for breast cancer. Am J Surg. 2020;219(5):816-22.
12. Joseph FJ, van Oepen A, Friebe M. Breast sentinel lymph node biopsy with imaging towards minimally invasive surgery. Biomed Tech (Berl). 2017;62(6):547-55.
13. Knuttel FM, van den Bosch MAAJ, Young-Afat DA, Emaus MJ, van den Bongard DHJG, Witkamp AJ, et al. Patient preferences for minimally invasive and open locoregional treatment for early-stage breast cancer. Value Health. 2017;20(3):474-80.
14. Olfatbakhsh A, Mehrdad N, Ebrahimi M, Alavi N, Hashemi E, Kaviani A, et al. Evaluation of factors impacting cosmetic outcome of breast conservative surgery: A study in Iran. Asian Pac J Cancer Prev. 2015;16(6):2203-7.
15. Vrouwe SQ, Somogyi RB, Snell L, McMillan C, Vesprini D, Lipa JE, et al. Patient-reported outcomes following breast conservation therapy and barriers to referral for partial breast reconstruction. Plast Reconstr Surg. 2018;141(1):1-9.
16. Ozmen T, Polat AV, Polat AK, Bonaventura M, Johnson R, Soran A. Factors affecting cosmesis after breast conserving surgery without oncoplastic techniques in an experienced comprehensive breast center. Surgeon. 2015;13(3):139-44.
17. Noguchi M, Inokuchi M. “Moving window” operation for breast-conserving surgery. Breast Cancer. 2010;17(1):56-60.
18. Bartelink H, Rutgers E, Wesseling J. Cavity shave margins in breast cancer. N Engl J Med. 2015;373(22):2186-7.
19. De La Cruz L, Blankenship SA, Chatterjee A, Geha R, Nocera N, Czerniecki BJ, et al. Outcomes after oncoplastic breast-conserving surgery in breast cancer patients: A systematic literature review. Ann Surg Oncol. 2016;23(10):3247-58.
20. Klinger M, Giannasi S, Klinger F, Caviggioli F, Bandi V, Banzatti B, et al. Periareolar approach in oncoplastic breast conservative surgery. Breast J. 2016;22(4):431-6.
21. Hennigs A, Biehl H, Rauch G, Golatta M, Tabatabai P, Domschke C, et al. Change of patient-reported aesthetic outcome over time and identification of factors characterizing poor aesthetic outcome after breast-conserving therapy: Long-term results of a prospective cohort study. Ann Surg Oncol. 2016;23(5):1744-51.
22. Atisha DM, Rushing CN, Samsa GP, Locklear TD, Cox CE, Hwang ES, et al. A national snapshot of satisfaction with breast cancer procedures. Ann Surg Oncol. 2015;22(2):361-9.
23. Losken A, Kapadia S, Egro FM, Baecher KM, Styblo TM, Carlson GW. Current opinion on the oncoplastic approach in the USA. Breast J. 2016;22(4):437-41.