



Malignant Mesothelioma - Without Asbestos Exposure

Parikshit HT*

Department of Pulmonary Medicine, Dr. PDMMC, India

Abstract

Malignant Mesothelioma is an aggressive primary malignant tumor of the pleura, usually caused by prolonged asbestos exposure. The prognosis of malignant pleural mesothelioma is very poor and median survival ranges from 8 to 14 months from diagnosis. There is a long latency period of development of the cancer from asbestos exposure. The absence of an explicit asbestos exposure is another diagnostic problem.

Keywords: Asbestos; Mesothelioma; Pleural effusion

Case Report

A 60-year-old female, farmer by occupation, non-smoker, presented with chief complain of right sided chest pain for 2-month, breathlessness for 1-month, dry cough for 1 month. No significant past history and family history. No history suggestive of asbestos exposure.

Examination: General Examination - Grade 2 Clubbing. Respiratory examination reveals decrease chest movement, stony dull on percussion, grossly diminished breath sound on right hemi thorax with slightly deviated mediastinum to contralateral side.

Investigation: Complete blood hemogram normal except leukocytosis.

CXR: Right moderate pleural effusion.

USG: Right moderate pleural effusion with pleural thickening with normal abdomen pelvis.

CECT Thorax: Multiple heterogenous enhancing pleural nodular thickening of mediastinal and right parietal and diaphragmatic pleura which takes enhancement with right gross pleural effusion.

Pleural fluid cytology: Lymphocytosis and no malignant cell. Biochemical test found low ADA exudative with high LDH.

USG Guided Biopsy: Cardiophrenic pleural thickening and

Histopathology: Confirms malignant mesothelioma.

OPEN ACCESS

*Correspondence:

Parikshit H Thakare, Department of Pulmonary Medicine, Dr. PDMMC, Amravati, Maharashtra, India

Received Date: 03 Nov 2023

Accepted Date: 14 Nov 2023

Published Date: 18 Nov 2023

Citation:

Parikshit HT. Malignant Mesothelioma - Without Asbestos Exposure. *Ann Clin Radiol.* 2023; 5(1): 1021.

Copyright © 2023 Parikshit HT. This is an open access article distributed under the Creative Commons Attribution License, which permits unrestricted use, distribution, and reproduction in any medium, provided the original work is properly cited.

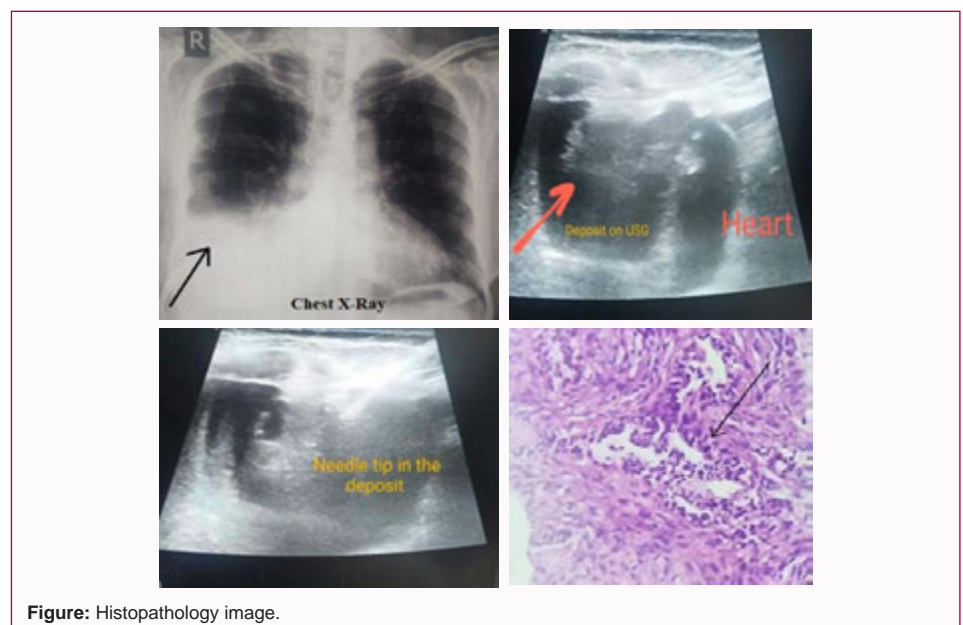


Figure: Histopathology image.

Immunohistochemistry: Positive for calretinin. Patients referred to oncology department for further management.

usually associated with inhalation exposure to asbestos. About 20% of the patients have no demonstrable exposure to asbestos.

Conclusion

Malignant mesothelioma is an uncommon pleural neoplasm and