Annals of Clinical Radiology

Case Report
Published: 24 May, 2018

Lower Urinary Tract Symptoms in Boys – The Role of Voiding Cystourethrography as a Diagnostic Tool

Stanislaw Warchol[1], Teresa Dudek-Warchol[1], Przemyslaw Bombinski[2], Michal Brzewski[2]*

[1]Department of Pediatric Surgery and Urology of Medical University of Warsaw, Warsaw, Poland

[2]Department of Pediatric Radiology of Medical University of Warsaw, Warsaw, Poland

Abstract

Voiding cystourethrography (VCUG) is well accepted study do detect vesicoureteral reflux and posterior urethral valves; however, there is no uniform approach to use this diagnostic procedure in cases of lower urinary tract symptoms. We present 2 different cases of 12 yr and 9 yr older boys with voiding dysfunction as a leading clinical symptom, in whom VCUG was used as one of diagnostic work-up studies. The results of cystography determined and helped for proper diagnosis and further treatment.

Keywords: Voiding cystourethrography; Lower urinary tract symptoms; Voiding dysfunction; Posterior urethral valves; Anterior urethral valves

Introduction

Voiding cystourethrography (VCUG) is well accepted and frequently performed study to detect various urological conditions in children, especially vesicoureteral reflux (VUR) and posterior urethral valves (PUV) [1-4]. In 2016 in Journal of Pediatric Urology and in Pediatrics were published articles presenting the current VCUG protocol to create a consensus how to perform this procedure, according to American Academy of Pediatric Section on Radiology and Section on Urology [5,6]. However, there is still no uniform approach to use VCUG as a standard diagnostic procedure in boys with voiding dysfunction as a leading clinical symptom and still is debate about the value of diagnostic tests to assess the cause of infravesical obstruction in boys [1,7-11]. We present 2 different cases of boys with voiding dysfunction as a leading clinical symptom, in whom VCUG was used helped to make diagnosis of infravesical obstruction as used as one of diagnostic work-up studies.

Case Report 1

A 12-year old boy was referred for urological evaluation because of symptoms of voiding dysfunction, including strain to void, poor stream of urine and prolonged micturition. The symptoms had gradually increased over the last 2 years. No urinary tract infections (UTI) were noted. Ultrasound scan (US) showed no dilatation of the upper urinary tract, however, significant urine retention after voiding was noted (Figure 1a, 1b). Uroflowmetry showed obstructive pattern of urine flow (Figure 2). To complete diagnostic work-up VCUG was performed. The results of cystography suggested the presence of possible anatomical obstruction localized between posterior and anterior urethra (Figure 3a,3b). The patient underwent then urethrocystoscopy which revealed anterior urethral valves, bladder neck hypertrophy and bladder wall trabeculation (Figure 4). Transurethral incision of valves was done using a cold knife (Figure 5) and Foley catheter was left for the next 4 days. After removal of Foley catheter normal urinary stream and micturition was noted. Control US study 2 weeks after valve ablation showed only minimal residual post-void urine retention (Figure 6a,6b). Further control studies (uroflowmetry, VCUG) are scheduled for this patient.

Case Report 2

A 9-year old boy was observed for the last 4 years because of persistent day time incontinence and recurrent UTIs, before urological diagnostic work-up was applied. US showed no upper urinary tract dilatation, but significant post-void residual volume. Urodynamic study revealed overactive and high pressure bladder and obstructive uroflowmetry pattern (Figure 7). The results of VCUG were suggestive of posterior urethral valves (PUV) with left reflux grade II (Figure 8a,8b). During urethrocystoscopy PUV type I were found, which were incised with the cold knife (Figure 9a,9b,9c). Gradual improvement of lower urinary tract symptoms were observed after valve ablation and

OPEN ACCESS

Correspondence:
Stanislaw Warchol PhD, MD, Department of Pediatric Surgery and Urology, Medical University of Warsaw, 63a Zwirki and Wigury Street, 2-091 Warsaw, Poland, Tel: +48 606 189 852; E-mail: swarchol@poczta.onet.pl

Received Date: *19 Dec 2017*
Accepted Date*: 17 May 2018*
Published Date*: 24 May 2018*

Citation:
Warchol S, Dudek-Warchol T, Bombinski P, Brzewski M. Lower Urinary Tract Symptoms in Boys – The Role of Voiding Cystourethrography as a Diagnostic Tool. Ann Clin Radiol. 2018; 1(1): 1005.

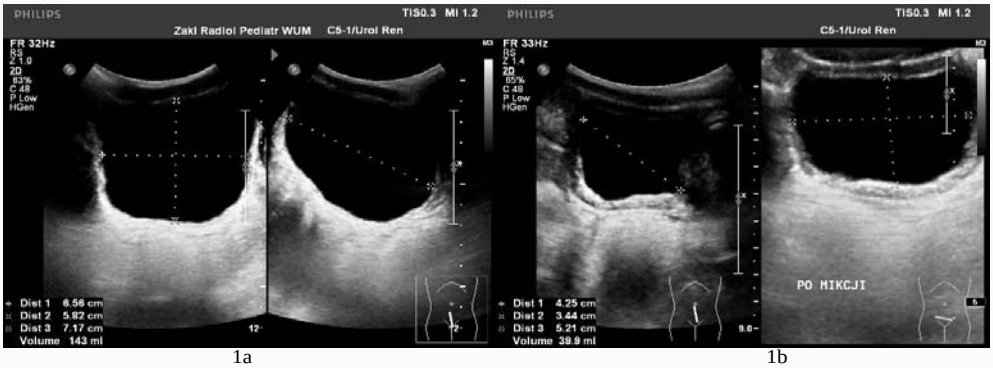

1a 1b

Figure 1: US: significant post-void urine retention: before voiding (a), after (b).

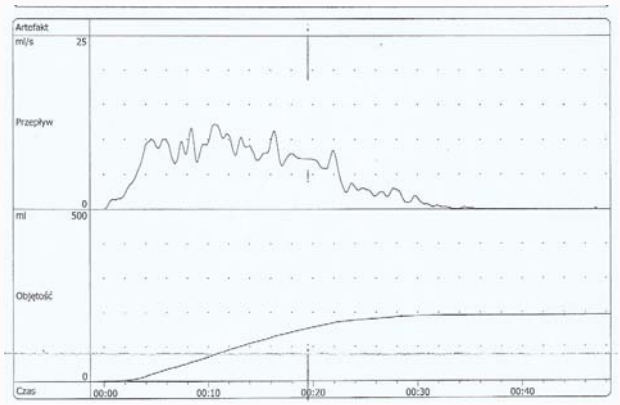

Figure 2: Uroflowmetry: obstructive pattern.

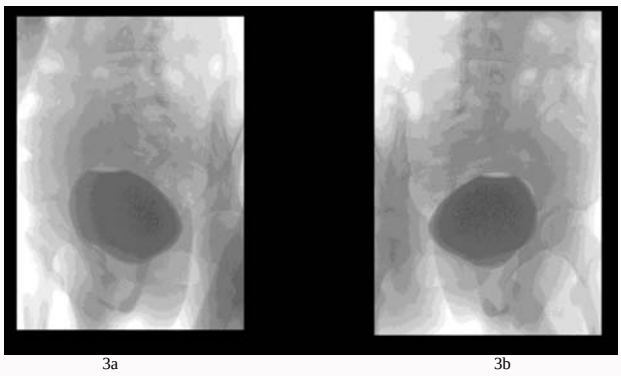

3a 3b

Figure 3: VCUG: no vesicoureteral reflux, significant difference in diameter between dilated posterior urethra and narrow anterior urethra.

Figure 4: Urethrocystoscopy: circumferential anterior urethral valves.

Figure 5: Urethrocystoscopy: cystoscopy view after anterior urethral valves ablation.

pharmacological treatment of bladder dysfunction.

Discussion

Infravesical obstruction in boys, mostly caused by posterior urethral valves, if unrelieved can result in progressive damage of bladder and upper urinary tract with subsequent deterioration of renal function [1,3,12,13].

Nowadays, PUV are usually diagnosed prenatally or within the newborn period, however, there is a group of boys in whom the diagnosis is made at a later age. In this subgroup of patients lower urinary tract symptoms with voiding dysfunction as a leading and only clinical problems are usually observed [14-16].

Anterior urethral valves (AUV) are very rare but known congenital anomaly, usually associated with urethral diverticulum, and also consequences of AUV on the upper urinary system can be important .Usually case reports of AUV are available in the literature [17-19].

Diagnosis of PUV in older boys and AUV is challenging and may be overlooked, because of a spectrum of symptoms and no uniform diagnostic algorithms are used. The presented case of 12-year old boy with final diagnosis of anterior urethral valve as a cause of observed lower urinary symptoms is the first in our practice. The described case of 9-year old boy with posterior urethral valves represents one of 10 boys with delayed diagnosis of PUV treated at our department.

6a 6b

Figure 6: Control US 2 weeks after anterior valves ablation: before voiding (a), minimal post-void urine retention (b).

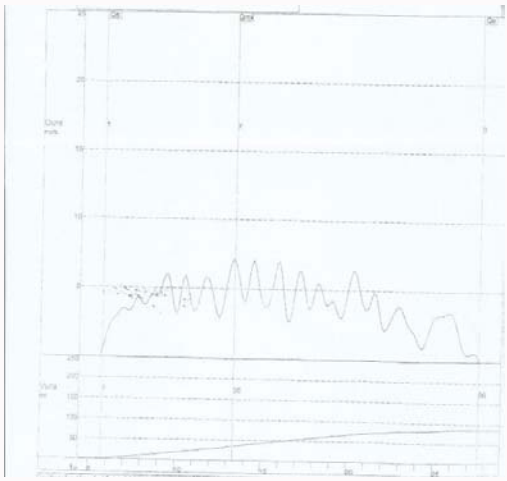

Figure 7: Uroflowmetry: obstructive pattern, signs of bladder hyperactivity.

8a 8b

Figure 8: VCUG: left vesicoureteral reflux grade II, bladder wall diverticulum, dilated posterior urethra.

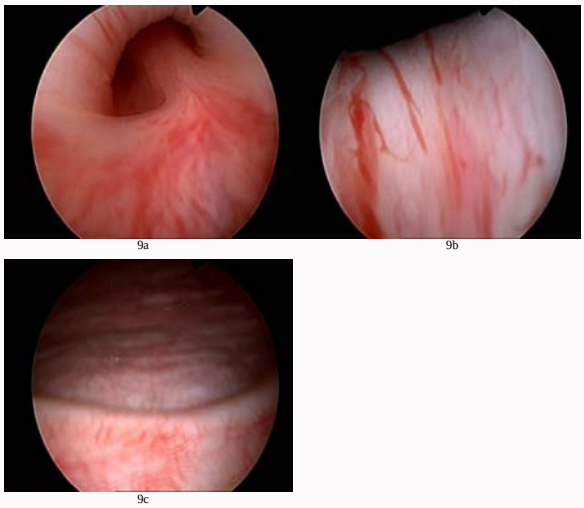

9a 9b 9c

Figure 9: Urethrocystoscopy: posterior urethral valves type I, bladder neck hypertrophy, trabeculated bladder wall.

The clinical symptoms in all of them included poor stream of urine, straining to void, dribbling of urine and day time incontinence. VCUG used as one of essential study together with ultrasound, uroflowmetry or urodynamic study and finally cystoscopy enables proper diagnosis and treatment.

References

1. Tegul S, Dogan HS, Hoebeke P, Kocvara R, Nijman JM, Radmayr C et al. Guidelines on Paediatric Urology 2016.
2. Khoury AE, Bagli DJ. Vesicoureteral reflux. In: Wein AJ, Kavoussi LR, Novick AC, Partin AW, Peters CA. editors. Campbell-Walsh Urology, 10th Edition. Elsevier, Saunders; 2012, 3267-3309.
3. Casale AJ. Posterior urethral valves. In: Wein AJ, Kavoussi LR, Novick AC, Partin AW, Peters CA. editors. Campbell-Walsh Urology, 10th Edition. Elsevier, Saunders; 2012, 3389-3410.
4. Okarska-Napierala M, Wasilewska A, Kuchar E. Urinary tract infection in children: diagnosis, treatment, imaging – comparison of current guidelines. J Pediatr Urol. 2017;13(6):567-573.
5. Frimberger D, Bauer SB, Cain M, Greenfield SP, Kirsch AJ, Ramji F, et al. Establishing a standard protocol for the voiding cystourethrography. J Pediatr Urol. 2016; 12 (6): 362-366.
6. Frimberger D, Mercado-Deane M-G. Establishing a standard protocol for the voiding cystourethrography. Pediatrics. 2016; 138 (5).
7. Palmer LS. Evaluation and targeted therapy of voiding dysfunction in children. Urology. 2016;92:87-94.
8. Hoebeke P, Bower W, Combs A, De Jong T, Yang S. Diagnostic evaluation of children with daytime incontinence. J Urol. 2010; 183 (2): 699-703.
9. De Kort LMO, Uiterwaal CSPM, Beek EJA, Jan Nievelstein RA, Klijn AJ, de Jong TP. Reliability of voiding cystourethrography to detect urethral obstruction in boys. Urology. 2004; 63(5): 967-71.
10. De Jong TP, Radmayr C, Dik P, Chrzan R, Klijn AJ, De Kort LM, et al. Posterior urethral valves: search for diagnostic reference standard. Urology. 2008;72(5): 1022-5.
11. Hennus PML, dr Kort LMO, Bosch JHL, de Jong TPVM, van der Heijden GJGM. A systematic review on the accuracy of diagnostic procedures for infravesical obstruction in boys. PLoS.One. 2014;9(2).
12. Lopez Pereira P, Martinez Urrutia MJ, Espinosa L, Jaureguizar E.

Long-term consequences of posterior urethral valves. J Pediatr Urol. 2013;9(5):590-6.

13. Ansari MS, Gulia A, Srivastava A, Kapoor R. J Pediatr Urol. Risk factors for progression to end-stage renal disease in children with posterior urethral valves. J Pediatr Urol. 2010;6(3):261-4.

14. Nakai H, Hyuga T, Kawai S, Kubo T, Nakamura S. Aggressive diagnosis and treatment for posterior urethral valve as an etiology for vesicoureteral reflux or urge incontinence in children. Investig Clin Urol. 2017; 58 (Suppl.1): S46-53.

15. Schober JM, Dulabon LM, Woodhouse ChR. Outcome of valve ablation in late-presenting posterior urethral valves. BJU Int. 2004; 94(4):616-9.

16. Nakamura S, Hyuga T, Kawai S, Kubo T, Nakai H. The endoscopic morphological features of congenital posterior urethral obstructions in boys with refractory daytime urinary incontinence and nocturnal enuresis. Eur J Pediatr Surg. 2016; 26:368-75.

17. Zia-ul-Miraj M. Anterior urethral valves: a rare cause of infravesical obstruction in children. J Pediatr Surg. 2000;35 (4):556-8.

18. Parmar JP, Mohan Ch, Vora MP. Anterior urethral valve: a rare but important cause of infravesical urinary tract obstruction. Pol J Radiol. 2016;81:209-211.

19. Prakash J, Dalele D, Goel A, Singh V, Kumar M, Garg M, et al. Congenital anterior urethral valve with or without diverticulum: a sinle-centre experience. J Pediatr Urol. 2013;9:1183-7.