Journal of Gynecological Oncology

Research Article
Published: 10 Jul, 2020

Intra-Operative Trans-Ureteric Stent Insertion during Cytoreductive Surgery for Ovarian Cancer: Update of a Novel Technique

Hannah E[1], Melissa B[1,2], O'Donnell RL[1,3,4] and Raj N[1]*

[1]Department of Gynecological Oncology, Queen Elizabeth Hospital, UK

[2]Department of Gynecological Oncology, Vall d'Hebron Hospital, Spain

[3]Translational and Clinical Research Institute, Newcastle University, UK

[4]Department of Gynecological Oncology, Newcastle Upon Tyne Foundation Trust, Royal Victoria Infirmary, UK

Abstract

Background: This observational study describes an extended cohort, from a single surgeon, reporting indications, technique and morbidity for a novel trans-ureteric approach to stent placement.

Methods: This retrospective observational study included all patients who underwent cytoreductive surgery, 2001 to 2017, with intra-operative stent insertion. Clinicopathological data, stent indication and morbidities were collated.

Results: 2,195 patients underwent laparotomy for ovarian cancer in the 16-year study period, of which 42 (2%) underwent intra-operative stent insertion. Indications included persistent hydroureter despite surgical decompression (15, 36%), prophylactically following extensive ureterolysis with concerns of post-operative ischemia/fistula formation (12, 29%), ureteric stricture (6, 14%), following partial ureteric excision to facilitate cytoreduction (6, 14%) or inadvertent injury (3, 7%). Complete, or near-optimal, surgical cytoreduction was achieved in 32 (76%) patients. All stents were inserted by a gyne-oncologist with no failed insertions and no stent-related complications.

Conclusion: Intra-operative trans-ureteric stenting by a gyne-oncologist is feasible, safe, can protect devascularized ureters after extensive retroperitoneal dissection and may serve to reduce peri-operative urological morbidity whilst allowing a more aggressive cytoreductive surgical approach.

Keywords: Ureteric stent; Ovarian cancer; Cytoreductive surgery; Trans-ureteric approach

OPEN ACCESS

Correspondence:
Rachel O'Donnell, Department of Gynecological Oncology, Newcastle Upon Tyne Foundation Trust, Royal Victoria Infirmary, NE1 4LP, Newcastle, UK, Tel: +44(0)-191-445-2445; E-mail: Rachel.O'Donnell@newcastle.ac.uk

Received Date: *14 Jun 2020*
Accepted Date*: 06 Jul 2020*
Published Date*: 10 Jul 2020*

Citation:
Hannah E, Melissa B, O'Donnell RL, Raj N. Intra-Operative Trans-Ureteric Stent Insertion during Cytoreductive Surgery for Ovarian Cancer: Update of a Novel Technique. J Gynecol Oncol. 2020; 3(4): 1039.

Introduction

Complete surgical cytoreduction has been long established as the most important prognostic factor in the management of ovarian cancer [1-4]. The use of neoadjuvant chemotherapy does not negate the need for radical surgery and it is broadly accepted that radical surgery, including bowel resection, is justified when complete cytoreduction can be achieved [5-8]. The same body of published literature, however, does not exist to guide the role of urological surgery or intervention in this setting.

Urological intervention, more specifically ureteric stenting, may be necessary either as a consequence of the disease process itself or of the surgery necessary to achieve complete cytoreduction. Routine systematic retroperitoneal dissection should be avoided in the absence of bulky nodes [9] but extensive intraperitoneal or retroperitoneal disease can cause ureteric obstruction, either by extrinsic compression or by infiltration of the peri-ureteric tissue. In some circumstances, perhaps more commonly in the setting of relapsed disease, tumor can also infiltrate the ureter itself. To achieve cytoreduction, extensive pelvic and retroperitoneal dissection may be needed, which increases the risk of urological injury or devascularization from extensive ureterolysis. At present, there is no evidence-based guideline regarding indications for ureteral stent insertion in ovarian cancer surgery. Evidence from other cancer sites suggests that pre-operative prophylactic placement of ureteral stents may facilitate ureteral identification and/or recognition of injury but there is also potential for iatrogenic injury and complications of insertion [10-13]. If there are concerns of ureteric complications during laparotomy stents can be inserted prior to removing the pelvic or retroperitoneal disease to enhance identification of the ureter or, alternatively, following

extensive ureterolysis to aid tissue healing and minimize the risk of post-operative fistula formation.

In 2009, we described our own small series of a novel technique for the intra-operative trans-ureteric insertion of silastic 'pigtail' ureteric stents in advanced stage ovarian cancer [14]. This approach avoids the need for intra-operative repositioning for a retrograde cystoscopic approach and can be performed independent of specialist urology. To our knowledge, no further studies have assessed the value of this procedure during extensive cytoreductive surgery in ovarian cancer and we therefore present an expanded cohort of our data evaluating the largest case series of intra-operative trans-ureteric stent insertion published to date.

Methods

This retrospective study, approved by the Institutional Review Board, included patients who had a ureteric stent inserted intra-operatively, 2001 to 2017, within a single UK institution during primary surgery for ovarian cancer by a single surgeon. This included upfront and interval surgery for International Federation of Gynecology and Obstetrics (FIGO) stages III and IV disease as well as those undergoing secondary cytoreduction at relapse. A single surgeon series was selected to reduce inter-surgeon variability in caseload and urological procedure experience. Complete cytoreduction was defined as the presence of no visible macroscopic residual disease following surgery, near-optimal cytoreduction when the residual disease was less than 1 cm and sub-optimal if residual disease was more than 1 cm [15]. Surgical complexity was classified using a modification of the Mayo Clinic surgical scoring system [16].

Frequency of stent insertion and indications were reported alongside basic descriptive statistics of the study population. Peri-operative and long-term morbidity frequencies were reported from the prospectively collected departmental morbidity database. Univariate associations were examined using Chi2 or Fisher's exact test, as appropriate. See supplementary methods for description of the stent insertion technique.

Supplementary methods: Intra-operative ureteric stent insertion

Following ureterolysis to ensure adequate visualization of the course of the ureter from the kidney to the bladder, a 5 mm to 8 mm longitudinal incision in the ureter at the level of the pelvic brim was made. A 6 or 8 French Bard® Silicone Ureteral Coil Stent (C.R. Bard Inc., Covington, GA, USA) was used in all cases and inserted to the renal hilum over a guidewire. The double-J stent consists of a straight tube with anchoring "pigtail" loops at either end, making it resistant to migration. The stent was straightened and inserted over a guidewire, Figure 1A and 1B, Supplementary Figures 1A-1E. Removal of the guidewire causes both ends to curl into their natural anchoring conformation. The distal stent was passed into the bladder using the same guidewire technique and position confirmed with palpation ± intra-operative imaging. The incision was then closed transversely with interrupted sutures to avoid ureteric stricture. Stent insertion was covered with prophylactic antibiotics, in line with local policy, and removal/replacement arranged for 3 months post-operatively cystoscopically.

Results

Between 2001 and 2017, 2195 laparotomies were performed for patients with ovarian cancer, of which 442 were performed between

Figure 1A: Intra-operative trans-ureteric insertion of 6 French Bard® Silicone Ureteral Coil Stent (C.R. Bard Inc., Covington, GA, USA) through a longitudinal incision, closed transversely. A) Bilateral stents in situ within persistently dilated ureters following extensive ureterolysis and surgical decompression during cytoreductive surgery for recurrent ovarian cancer.

Figure 1B: Intra-operative trans-ureteric insertion of 6 French Bard® Silicone Ureteral Coil Stent (C.R. Bard Inc., Covington, GA, USA) through a longitudinal incision, closed transversely. B) Post-operative plain abdominal X-ray to demonstrate position of bilateral stents.

Supplementary Figures

Figure 1A: Intra-operative trans-ureteric insertion of 6 French Bard® Silicone Ureteral Coil Stent (C.R. Bard Inc., Covington, GA, USA) through a longitudinal incision. A) Persistently dilated right ureter following extensive ureterolysis during cytoreductive surgery for recurrent ovarian cancer.

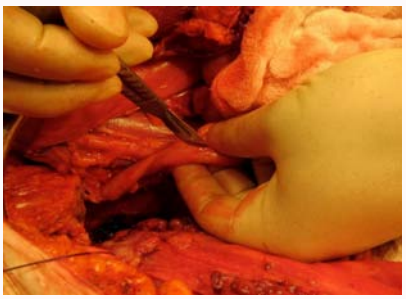

Figure 1B: Intra-operative trans-ureteric insertion of 6 French Bard® Silicone Ureteral Coil Stent (C.R. Bard Inc., Covington, GA, USA) through a longitudinal incision. B) 6 mm longitudinal incision is made on the anterior aspect.

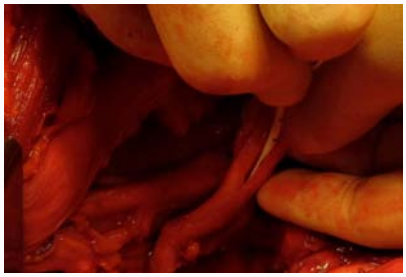

Figure 1C: Intra-operative trans-ureteric insertion of 6 French Bard® Silicone Ureteral Coil Stent (C.R. Bard Inc., Covington, GA, USA) through a longitudinal incision. C) Over a semi-rigid guidewire, the stent is caudally and palpated to be correctly placed within the pelvic hilum before re-positioning the guidewire to insert the distal end into the bladder.

Figure 1D: Intra-operative trans-ureteric insertion of 6 French Bard® Silicone Ureteral Coil Stent (C.R. Bard Inc., Covington, GA, USA) through a longitudinal incision. D) The guidewire is removed to leave the stent securely held in position by the double pigtail ends.

Figure 1E: Intra-operative trans-ureteric insertion of 6 French Bard® Silicone Ureteral Coil Stent (C.R. Bard Inc., Covington, GA, USA) through a longitudinal incision. E) Interrupted 3-0 vicryl closes the incision transversely to avoid stricture formation.

2001 and 2007 (as reported in our first series [14]) and 1753 between 2008 and 2017.

42 (1.9%) patients underwent insertion of a ureteric stent by a single surgeon (RN) at the time of laparotomy, of which 28 (66.7%) underwent primary cytoreductive procedures, 5 (11.9%) had Interval Debulking Surgery (IDS) following Neoadjuvant Chemotherapy (NACT) and 9 (21.4%) patients underwent secondary cytoreductive surgery for recurrent ovarian cancer.

The median age of patients undergoing intra-operative ureteric stent insertion was 70.2 years (41.8 to 88.5 years). A unilateral stent was inserted in 37 (88.1%) cases with bilateral stents inserted in the other 5 cases resulting in 47 ureteric stents in 42 patients in total. All 33 patients undergoing primary or interval surgery had FIGO stage III or IV ovarian cancer, see Table 1 for demographics. Table 2 illustrates the indications for an intra-operative stent insertion in this cohort where 14 (33.3%) patients underwent intra-operative ureteric stenting for the presence of unresolved hydroureter of greater than 20 mm diameter at laparotomy following removal of pelvic and retroperitoneal disease. 12 (28.6%) underwent stenting to protect a skeletonized, devascularized ureter following extensive ureterolysis and 6 (14.3%) following identification of a ureteric stricture. Surgery in a further 6 (14.3%) patients resulted in a partial ureteric defect/excision in order to remove bulky disease directly adherent to, or invading, the ureteric wall with excision of disease thereby necessitating excision of a section of ureter. Stenting was undertaken due to inadvertent ureteric injury in 3 (7.1%). 4 (9.5%) patients underwent re-anastomosis of transected/resected ends over a stent, and in 1 (2.4%) case, due to the proximity of the defect/injury to the bladder, formal reimplantation was undertaken.

In all cases, the operating gynecological oncology surgeon inserted the ureteric stent although a specialist urology surgeon attended for two patients. In the first of these 2 cases, radical surgery including rectosigmoid colectomy (with end colostomy formation), splenectomy, peritonectomy in addition to hysterectomy and bilateral salpingo-oophorectomy, was needed to achieve complete cytoreduction in a patient undergoing primary cytoreductive surgery for FIGO stage IIIC HGSC. Extensive bilateral ureterolysis was necessary and the left ureter was inadvertently injured. A localized ureteric resection with primary anastomosis over a prophylactic ureteric stent was performed. In the second case, undergoing interval surgery for FIGO Stage IIIC mucinous ovarian cancer, specialist urology attended to assess a ureteric stricture close to the bladder base. Resection and re-implantation over a stent were undertaken.

In the 15 patients who underwent stenting for intra-operative hydroureter, only 6 had some degree of hydroureter or hydronephrosis on pre-operative imaging (Table 2).

The median surgical radicality score for primary and interval surgery in this cohort was 4 (2 to 13) with 19/33 (57.6%) patients undergoing radical surgery with a score of ≥ 4, 3 (9.1%) of which had a score of ≥ 8. In those undergoing surgery for recurrence, 4 (44.4%) had a radicality score of ≥ 4.

In the 42 cases in this series there were 23 (54.8%) large or small bowel resections, with primary anastomosis in 6 (26.1%) and stoma formation in 17 (73.9%), omentectomy (35, 83.3%), pelvic and/or para-aortic lymphadenectomy (8, 19.0%), pelvic and/or abdominal peritoneal stripping (7, 16.7%), diaphragmatic stripping (2, 4.8%), splenectomy (2, 4.8%), tail of pancreas resection (1, 2.4%) and appendectomy (6, 14.3%). Complete or near-optimal cytoreduction was achieved in 32 (76.2%) patients, whilst 10 (23.8%) had a suboptimal outcome. Suboptimal cytoreduction was more common in the non-HGSC subtypes and in the setting of secondary cytoreductive surgery for recurrent disease.

In the same study period, we identified 20 patients who underwent pre-operative stent insertion for hydroureter, typically with deranged renal function. There were no failed intra-operative stent insertions in this time period. Excluding 4 patients who were palliated within 2 months to 4 months of surgery with progressive disease, all patients in this cohort were prospectively followed up for cystoscopic stent replacement or removal. Median overall follow-up from the index surgery was 18.1 months (range 3.2 to 231.0). In the existing literature, there is no consensus about the preferred time of stent removal and the median time for stent removal was 4 months (2

Table 1: Patient characteristics (n=42).

Demographic		Median (range)
Age (years)		70.2 (41.8-88.5)
		Frequency (%)
Histological subtype	High Grade Serous (HGS)	24 (57.1)
	Endometrioid	6 (14.3)
	Carcinosarcoma	3 (7.1)
	Low Grade Serous (LGS)	1 (2.4)
	Clear cell	1 (2.4)
	Granulosa cell	3 (7.1)
	Mucinous	1 (2.4)
	Other	3 (7.1)
FIGO Stage	I (recurrence)	3 (7.1)
	II (recurrence)	1 (2.4)
	III	32 (76.2)
	IV	6 (14.3)
Surgery	Primary	28 (66.7)
	Interval cytoreduction (after neoadjuvant chemotherapy)	5 (11.9)
	Secondary surgery for recurrence	9 (21.4)
Residual disease	Complete (no macroscopic disease)	9 (21.4)
	Optimal (< 1 cm in greatest dimension)	23 (54.8)
	Suboptimal (≥ 1 cm)	10 (23.8)
Radicality score (n=32: surgery in the first line treatment phase).	Low (≤ 3)	13 (40.6)
	Intermediate (4-8)	16 (50.0)
	Radical (≥ 8)	3 (9.4)
	Median (range)	4 (2 – 13)
ASA (n=34)	1	10 (29.4)
	2	12 (35.3)
	3	11 (32.4)
	4	1 (2.9)
ECOG (n=37)	0	9 (24.3)
	1	25 (67.6)
	2	3 (8.1)
	3	0 (0)

Table 2: Indications for intra-operative ureteric stent insertion (n=42).

		Frequency (%)
Laterality	Unilateral	37 (88.1)
	Right	17 (40.5)
	Left	20 (47.6)
	Bilateral	5 (11.9)
Indication	Unresolved hydroureter	15 (35.7)
	Extensive ureterolysis / Devascularized	12 (28.6)
	Ureteric stricture	6 (14.3)
	Defect following tumor excision	6 (14.3)
	Injury	3 (7.1)
Pre-operative hydronephrosis	Unilateral	6 (14.3)
	Bilateral	1 (2.4)

months to 15 months), with stent removal deferred in some cases until completion of adjuvant chemotherapy. Stents were replaced in the setting of a persistent stricture or fistula. There were no complications from stent insertion or removal, no complications of stent migration, problematic malposition and no post-operative ureteric fistulas.

This patient subgroup was high-risk and included 9 (21.4%) patients aged over 70 years, 9 (22.5%) patients undergoing secondary cytoreduction for recurrent disease and 28/37 (75.7%) patients with performance status of ECOG 1 or more. 24/34 (70.6%) patients had an ASA grade of ≥ 2. Median blood loss was 1500 ml (100 ml to 6000 ml) and 24 (57.1%) patients were electively admitted to Level 2 Care post-operatively. There were 4 patients with intra-operative morbidity, which included 3 bladder injuries and 1 vessel injury, all of which were repaired intra-operatively with no residual deficits. There were no surgical mortalities (<30 days of surgery) and 24 individual post-operative morbidities in 7 (16.7%) patients. These included 3 venous thromboembolisms, 2 superficial wound dehiscence's, 3 urinary tract infections and 1 episode of sepsis resulting from a lower respiratory tract infection causing pre-renal stage 2 Acute Kidney Injury (AKI). One further patient developed transient AKI and one patient underwent insertion of a permanent pacemaker post-operatively for new onset heart block. There was one post-operative rectovesical fistula, which resolved with conservative management.

Discussion

This study demonstrates that intra-operative ureteric stenting, using a trans-ureteric technique by a gynecologist is feasible and safe with no excess of urological morbidity. Stenting is needed infrequently in complex cytoreductive surgery in our institute and the reported rate of 1.9% is below many series reporting the incidence in routine benign gynecological procedures [17-19]. Since our first review [14], the incidence of stenting in our institution has remained stable. We present the largest series of ureteric stents in ovarian cancer, with an overall incidence of 2.4% of which 1.9% were inserted intra-operatively. This study supports the findings from the previous publication [14] and this expanded series confirms its safety. It is however, a retrospective review and we acknowledge that success is critically dependent upon technique and careful selection of patients. A close relationship with urology is needed to provide joint specialist care of this small subgroup.

Although, routine pre-operative imaging may in a proportion of cases identify hydroureter, hydronephrosis or the presence of infiltrative disease around the ureter, thereby alerting the surgeon to consider pre-operative stenting or urological intervention, pre-operative need is not always apparent and strategies for intra-operative stent insertion and management of urological complications are still necessary.

There is little debate that pre-operative stenting to correct obstructive renal failure is needed. However, published evidence regarding the value of pre-operative stent insertion in the absence of renal impairment is minimal and different hypotheses are proposed regarding its utility [20,21]. Although contentious, prophylactic stents may aid visualization of ureters during extensive retroperitoneal dissections and may help identification of accidental injury [20] but they do not decrease the rate of injury [22]. The alternative viewpoint is that a stent decreases the ureter's natural pliability, therefore, increasing the risk of inadvertent injury [23]. A recent study reviewed the value of stent insertion before cytoreductive surgery and hyperthermic intraperitoneal chemotherapy [24]. The authors suggested that stenting reduced the risk of operative ureteric complications without an increase in complications. Pre-operative insertion should, however, not be regarded as risk free. There are well documented complications associated with short- and long-term stent use [25,26]. Minor side-effects include hematuria, dysuria and pain, with major complications including vesicoureteric reflux, stent migration, infection, fistulation and a 'forgotten stent'. Ovarian cancer patients often have a pelvic mass, which is commonly responsible for ureteric obstruction or the tortuous path of the ureter and successful cystoscopic stent insertion, even for an experienced urologist, is a challenging procedure. Failure rates have been reported between 14% to 35% [27-30] and resolution of the obstruction is not guaranteed, therefore, necessitating conversion to an invasive percutaneous nephrostomy [31]. The decision to undergo pre-operative stenting, even with evidence of hydroureter, is further complicated by the fact that in a large proportion, the obstruction spontaneously resolves following removal of the pelvic mass and thus there is no need for stent insertion.

A decision to insert a stent intra-operatively should only be made following excision of all possible disease with adequate visualization of the ureter. As stent placement was performed by the trans-ureteric route intra-operatively, no additional equipment or re-positioning of the patient was required. The value of stent placement 'on demand' during laparotomy has previously been assessed in complex colorectal surgery showing it does not influence operating time nor cost [32]. This intra-operative technique may simplify the insertion of stents with the creation of a watertight tract between the kidney and bladder without need for patient re-positioning or re-instrumentation of the bladder, which further increases the risk of infection.

There are two distinct groups of patients within this series. Firstly, the group who required stenting for injury or ureteric defect and, secondly, the group who underwent stenting due to persistent hydroureter or devascularization following extensive ureterolysis ('prophylactically'). For the first subgroup, alternative approaches would include intra-operative attendance of a specialist urologist, located off-site, along with their specialist cystoscopic equipment. Cystoscopic retrograde stent insertion would necessitate patient repositioning and there is a small risk of failed insertion and of extension of the defect. In this circumstance, cystotomy for a further attempt of retrograde insertion or antegrade stenting *via* nephrostomy could be considered. In cases with an open abdomen and an identifiable ureteric defect, however, many urologists may choose to opportunistically use the defect as an entry point for the stent in the same way that we have described in this series. This avoids further iatrogenic injury, the need for repositioning and use of additional specialist equipment.

The second group of patients, in which stents were placed prophylactically, is perhaps more controversial, stimulating discussion around alternative approaches. Following extensive ureterolysis, with potential devascularization, or in the setting of persistent hydroureter despite decompression at laparotomy, a conservative approach could be adopted. This however, risks fistula formation, expected to occur 7 days to 10 days post-operatively following necrosis of devascularized tissues. A paucity of robust evidence surrounding this conservative approach means that there is no genuine understanding of the incidence of fistula formation in this specific circumstance. However, a recent population-based analysis, including 1,700 patients with

ureteric injury, showed a 10 fold increase in need for nephrostomy, a 6-fold increase in risk of sepsis, a 21-fold increase in urinary fistula comparing recognized and treated *vs.* unrecognized injuries, with increased odds of renal insufficient and death [33]. Management of a post-operative fistula is usually managed by diversion nephrostomy [34], with a variable success rate of 14% to 19% in published series [35-37]. In this circumstance, further delay in recovery and impact on delivery of adjuvant chemotherapy is likely. Delay or failure to complete adjuvant chemotherapy in ovarian cancer is known to have a detrimental impact on survival, hence, our more interventional approach aiming to actively minimize complication rates.

Conclusion

This study has demonstrated that trans-ureteric stenting by gyne-oncologist is feasible and we suggest that it may reduce morbidity associated with post-operative fistula formation in a high-risk subgroup of patients, ensuring optimal timing of adjuvant chemotherapy. Use of this novel approach, in the absence of specialist urological input, may equip gynecological oncology surgeons with the confidence to ensure maximal surgical effort in complex cases, further facilitating attainment of complete cytoreduction.

Author Contribution

HE: Data acquisition and curation, formal analysis, manuscript writing and review. MB: data acquisition and curation, manuscript review. ROD: Supervision, data curation and analysis, manuscript writing, review and editing. RN: conceptualization, study design, data analysis, manuscript review and editing.

References

1. National Institute for Health and Care Excellence. Ultra-radical (extensive) surgery for advanced ovarian cancer. Interventional Procedures Guidance [IPG470]. 2013.
2. Bristow RE, Rafael ST, Deborah KA, Edward LT, Montz FJ. Survival effect of maximal cytoreductive surgery for advanced ovarian carcinoma during the platinum era: A meta-analysis. J Clin Oncol. 2002;20(5):1248-59.
3. Al Rawahi T, Alberto DL, Robert EB, Andrew B, Ahmed E, Supratik C, et al. Surgical cytoreduction for recurrent epithelial ovarian cancer. Cochrane Database Syst Rev. 2013;2013(2):CD008765.
4. Vergote I, Claes GT, Frédéric A, Gunnar BK, Tom E, Nick J, et al. Neoadjuvant chemotherapy or primary surgery in stage IIIC or IV ovarian cancer. N Engl J Med. 2010;363(10):943-53.
5. Salani R, Marianna LZ, Antonio S, Robert LG, Robert EB. Survival impact of multiple bowel resections in patients undergoing primary cytoreductive surgery for advanced ovarian cancer: A case-control study. Gynecol Oncol. 2007;107(3):495-9.
6. Bidzinski M, Derlatka P, Kubik P, Ziolkowska-Seta I, A Dańska B, Gmyrek L, et al. The evaluation of intra- and postoperative complications related to debulking surgery with bowel resection in patients with FIGO stage III-IV ovarian cancer. Int J Gynecol Cancer. 2007;17(5): 993-7.
7. Aletti GD, Karl CP, Monica BJ, William AC. Role of rectosigmoidectomy and stripping of pelvic peritoneum in outcomes of patients with advanced ovarian cancer. J Am Coll Surg. 2006;203(4):521-6.
8. Cai HB, Zhou YF, Chen HZ, Hou HY. The role of bowel surgery with cytoreduction for epithelial ovarian cancer. Clin Oncol (R Coll Radiol). 2007;19(10):757-62.
9. Harter P, Jalid S, Domenica L, Alexander R, Ignace V, Christian M, et al. A randomized trial of lymphadenectomy in patients with advanced ovarian neoplasms. N Engl J Med. 2019;380(9):822-32.
10. Kyzer S, Gordon PH. The prophylactic use of ureteral catheters during colorectal operations. Am Surg. 1994;60(3):212-6.
11. Bothwell WN, Bleicher RJ, Dent TL. Prophylactic ureteral catheterization in colon surgery. A five-year review. Dis Colon Rectum. 1994;37(4):330-4.
12. Chahin F, Amit JD, Anil P, Wai C, Sunita A, Chadi C, et al. The implications of lighted ureteral stenting in laparoscopic colectomy. JSLS. 2002;6(1):49-52.
13. Coccolini F, Luca A, Sergio C, Riccardo S, Giuseppe M. The importance of ureteral stenting in major debulking surgery. Int J Gynecol Cancer. 2010;20(3):479.
14. Ang C, Naik R. The value of ureteric stents in debulking surgery for disseminated ovarian cancer. Int J Gynecol Cancer. 2009;19(5):978-80.
15. Elattar A, Andrew B, Brett AWR, Mohamed H, Raj N. Optimal primary surgical treatment for advanced epithelial ovarian cancer. Cochrane Database Syst Rev. 2011;2011(8):CD007565.
16. Aletti GD, Sean CD, Karl CP, William AC. Relationship among surgical complexity, short-term morbidity, and overall survival in primary surgery for advanced ovarian cancer. Am J Obstet Gynecol. 2007;197(6):676-7.
17. Visco AG, Taber KH, Weidner AC, Barber MD, Myers ER. Cost-effectiveness of universal cystoscopy to identify ureteral injury at hysterectomy. Obstet Gynecol. 2001;97(5 Pt 1):685-92.
18. Gilmour DT, Das S, Flowerdew G. Rates of urinary tract injury from gynecologic surgery and the role of intraoperative cystoscopy. Obstet Gynecol. 2006;107(6):1366-72.
19. Wu HH, Pei-Yin Y, Guang-Perng Y, Pan-Hsin C, Jui-Chang H, Kuo-Cherng L. The detection of ureteral injuries after hysterectomy. J Minim Invasive Gynecol. 2006;13(5):403-8.
20. Chou MT, Wang CJ, Lien RC. Prophylactic ureteral catheterization in gynecologic surgery: A 12-year randomized trial in a community hospital. Int Urogynecol J Pelvic Floor Dysfunct. 2009;20(6):689-93.
21. Coakley KM, Kevin RK, Stephanie MS, Tanushree P, Todd BH, Bradley RD. Prophylactic Ureteral Catheters for Colectomy: A National Surgical Quality Improvement Program-Based Analysis. Dis Colon Rectum. 2018;61(1):84-8.
22. Hassinger TE, Hunter JM, Matthew GM, Alex DM, Nathan RE, Shoshana TL, et al. Ureteral stents increase risk of postoperative acute kidney injury following colorectal surgery. Surg Endosc. 2018;32(7):3342-8.
23. Kuno K, Menzin A, Kauder HH, Sison C, Gal D. Prophylactic ureteral catheterization in gynecologic surgery. Urology. 1998;52(6):1004-8.
24. Coccolini F, Marco L, Roberto M, Fausto C, Carlo V, Pier Andrea DI, et al. Ureteral stenting in cytoreductive surgery plus hyperthermic intraperitoneal chemotherapy as a routine procedure: Evidence and necessity. Urol Int. 2012;89(3):307-10.
25. Ringel A, Richter S, Shalev M, Nissenkorn I. Late complications of ureteral stents. Eur Urol. 2000;38(1):41-4.
26. Joshi HB, Stainthorpe A, Keeley FX, MacDonagh R, Timoney AG. Indwelling ureteral stents: Evaluation of quality of life to aid outcome analysis. J Endourol. 2001;15(2):151-4.
27. Kim SH, Boram P, Jungnam J, Young J, Kyung SH, Jinsoo C, et al. Retrograde pyelography predicts retrograde ureteral stenting failure and reduces unnecessary stenting trials in patients with advanced non-urological malignant ureteral obstruction. PLoS One. 2017;12(9):e0184965.
28. Ganatra AM, Loughlin KR. The management of malignant ureteral obstruction treated with ureteral stents. J Urol. 2005;174(6):2125-8.
29. Izumi K, Atsushi M, Yuji M, Eitetsu K, Mikio N. Current outcome of patients with ureteral stents for the management of malignant ureteral obstruction. J Urol. 2011;185(2):556-61.

30. Kamiyama Y, Shinobu M, Masanori K, Yuko A, Shunichi T, Kazuyuki Y, et al. Stent failure in the management of malignant extrinsic ureteral obstruction: Risk factors. Int J Urol. 2011;18(5):379-82.

31. Chung SY, Robert JS, Douglas L, Benjamin JD, David CC, Ronald LH, et al. 15-year experience with the management of extrinsic ureteral obstruction with indwelling ureteral stents. J Urol. 2004;172(2):592-5.

32. Pokala N, Conor PD, Ravi PK, Jane B, Kenneth A, Victor WF. A randomized controlled trial comparing simultaneous intra-operative *vs.* sequential prophylactic ureteric catheter insertion in re-operative and complicated colorectal surgery. Int J Colorectal Dis. 2007;22(6):683-7.

33. Blackwell RH, Eric JK, Arpeet SS, Paul CK, Gopal NG, Thomas MTT. Complications of recognized and unrecognized iatrogenic ureteral injury at time of hysterectomy: A population based analysis. J Urol. 2018;199(6):1540-5.

34. Brandes S, Michael C, Noel A, Jack M. Diagnosis and management of ureteric injury: An evidence-based analysis. BJU Int. 2004;94(3):277-89.

35. Koukouras D, Theodore P, Evangelos L, Panagiotis K, Elias KS, Georgios A, et al. Percutaneous minimally invasive management of iatrogenic ureteral injuries. J Endourol. 2010;24(12):1921-7.

36. El Abd AS, Shawky AEA, Mohamed AEE, Ahmed MT, Mohamed GS, Mohamed AF, et al. Immediate and late management of iatrogenic ureteric injuries: 28 years of experience. Arab J Urol. 2015;13(4):250-7.

37. Png JC, Chapple CR. Principles of ureteric reconstruction. Curr Opin Urol. 2000;10(3):207-12.