World Journal of Vascular Surgery

Case Report
Published: 04 Jan, 2021

Intra-Aortic Misplacement of a Cement-Augmented Pedicle Screw after Surgical Stabilization of Thoracic Vertebral Fracture

Rothenbacher G[1]*, Brücher D[2] and Storck M[1]

[1]Department of Vascular and Thoracic Surgery, Städtisches Klinikum Karlsruhe, Germany

[2]Department of Trauma, Orthopedic and Hand Surgery, Germany

Abstract

A case of displacement of a vertebral pedical screw with penetration of the thoracic aortic wall is described in a 85 year old patient after traumatic fracture of the 9th vertebra. After considering all options, implantation of a thoracic stent graft (TEVAR) with surgical removal of the metal implant was suggested, but refused by the patient. After 30 months of observation there were no complications observed.

Keywords: Aortic injury; Vertebral fracture; Metal implant misplacement

Introduction

Serious vascular complications after orthopedic spine interventions are rare complications and need individual treatment strategies. We report on a rare case of screw misplacement into the descending thoracic aorta following stabilization of a thoracic vertebral fracture using an internal fixateur.

Case Presentation

An 85-year-old male patient with ankylosing spondylitis and multi segmental osteochondrosis was admitted to our trauma surgery department after falling on his back. There was a history of peripheral arterial occlusive disease, a known morbus Bechterew, and arterial hypertension. The right femoral bifurcation was surgically reconstructed 2 years ago.

Diagnostic imaging using CT scan showed a distraction injury to the thoracic spine with fracture of the 9 h thoracic vertebra and rupture of the anterior longitudinal ligament (type B according to Magerl classification). The injury was immediately stabilized by implantation of an internal fixateur reaching from thoracic vertebrae 7/8 to 10/11, with cement augmentation of the screw bearing. A postoperative CT check then showed an extraosseous placement of one of the cement-augmented screws, which at least significantly impressed the thoracic aorta at the level of TH 7, with probable mild penetration. There was no extravasation or an aortic wall hematoma and the patient was symptom-free.

The therapeutic options were discussed in an interdisciplinary setting. Although the aortic wall was not perforated in the acute situation, there was a significant risk of secondary aortic rupture due to permanent pulsatile shear forces in the thoracic aortic wall, which could lead to delayed dislocation of the screw with consecutive massive bleeding. An open surgical revision with thoracic aortic replacement was not recommended due to the age and reduced general condition of the patient, with an associated high perioperative risk. Another option was an endovascular approach with covered thoracic stent graft implantation (TEVAR). In this case, however, there would be the risk of mechanical injury of the PTFE layer of the prosthesis being perforated by the screw tip. In addition, the expansion force of the stent graft could lead to uncontrolled deeper penetration of the cemented screw from the aortic wall. Therefore, the screw and the cement would have to be removed before a stent graft implantation. Due to the surrounding cementation, this would most likely lead to a severe leakage of the aortic wall, which would result in massive bleeding.

However, surgical screw removal with simultaneous thoracic aortic stent graft implantation was suggested to the patient. After being informed, the patient refused this procedure, so that the findings are currently controlled by regular follow-up CTA examinations.

OPEN ACCESS

Correspondence:
Georg Rothenbacher, Department of Vascular and Thoracic Surgery, Städtisches Klinikum Karlsruhe, Moltkestrasse 90, D-76133 Karlsruhe, Germany,
E-mail: georg.rothenbacher@klinikum-karlsruhe.de

Received Date: *04 Dec 2020*
Accepted Date*: 30 Dec 2020*
Published Date*: 04 Jan 2021*

Citation:
Rothenbacher G, Brücher D, Storck M. Intra-Aortic Misplacement of a Cement-Augmented Pedicle Screw after Surgical Stabilization of Thoracic Vertebral Fracture. World J Vasc Surg. 2021; 4(1): 1027.

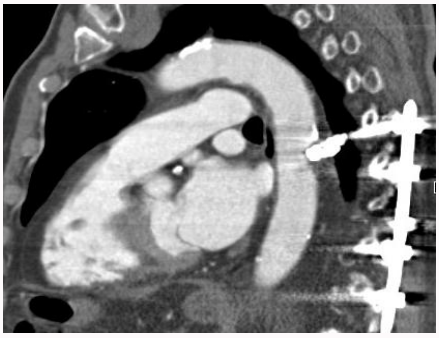

Figure 1: Saggital CT scan showing the pedical screw penetrating the dorsal aortic wall.

Figure 2: Transversal CT scan showing extraosseus and intra aortic position of the pedical screw tip.

30 months after implantation, the findings are still unchanged and the patient remains symptom-free.

Discussion and Conclusion

In this case report we describe a very rare complication following implantation of an internal thoracic fixateur with incorrect placement of a cemented pedicle screw in to the descending aortic wall. During the initial surgery, screw implantation was difficult on the one hand due to the existing severe ancylosis spondylitis and pronounced multi segmental osteochondrosis and on the other hand by the suspected bursting fracture of the 9th vertebral body, so that the screw bed had to be augmented by cement. The penetration of the thoracic aorta initially remained unnoticed intraoperatively and was only noticed during a routine postoperative CT examination. There is no available clinical data on the long-term course of such pathology, therefore the risk of late aortic complications like rupture, dissection or intramural hematoma cannot be predicted.

Literature review shows some individual reports of similar cases cases with aortic injury after spinal instrumentation. 27 publications regarding this kind of complication were identified in a literature search by Clairborne et al. [1]. Both open and endovascular therapy strategies are reported [1-6]. Thoracic stent graft placement either before or after screw placement is feasible.

It is clear that surgical treatment of this complication must take place in an interdisciplinary setting between vascular surgeons and spinal surgeons. In elderly and multimorbid patients, the open thoracotomy is a considerable burden, so an endovascular solution should be preferred.

In our case we suggested prophylactic treatment by removing the screw and simultaneous thoracic aortic stent graft implantation again after one year, but the patient still refused this procedure. The previous uncomplicated course shows that in the case of high perioperative risk in multimorbid elderly patients, conservative therapy with regular controls may well be feasible but is associated with an unknown risk of aortic rupture.

The follow-up period was uneventful so far over 30 months.

References

1. Claiborne P, Mallios A, Taubman K, Blebea J. Endovascular repair of thoracic aortic injury after spinal instrumentation. J Vasc Surg Cases. 2015;1(4):264-7.
2. Decker S, Omar M, Krettek C, Müller CW. Elective thoracotomy for pedicle screw removal to prevent severe aortic bleeding. World J Clin Cases. 2014;2(4):100-3.
3. Loh SA, Maldonado TS, Rockman CB, Lamparello PJ, Adelman MA, Kalhorn SP, et al. Endovascular solutions to arterial injury due to posterior spine surgery. J Vasc Surg. 2012;55(5):1477-81.
4. Kakkos SK, Shepard AD. Delayed presentation of aortic injury by pedicle screws: Report of two cases and review of the literature. J Vasc Surg. 2008;47(5):1074-82.
5. Hu HT, Shin JH, Hwang JY, Cho YJ, Ko GY, Yoon HK. Thoracic aortic stent-graft placement for safe removal of a malpositioned pedicle screw. Cardiovasc Intervent Radiol. 2010;33(5):1040-3.
6. Kokotsakis J, Misthos P, Sakellaridis T, Farsaris D, Anagnostakou V, Spiliotopoulos K. Emergent endovascular repair as damage control step of aortic injury after posterior spinal instrumentation. Ann Thorac Surg. 2010;89(4):1304.