Annals of Cardiology and Cardiovascular Medicine

Case Report
Published: 18 Feb, 2020

Infective Endocarditis and Giant Vegetation with Complicated Course

Madiha Iqbal*

Department of Internal Medicine, Aga Khan University Hospital, Pakistan

Abstract

A 45 year-old-female with no prior cardiac disease presented with a two month history of shortness of breath, intermittent fever and drowsiness. On examination she had pan systolic murmur on mitral area, purpuric lesions of both legs and splenomegaly. Laboratory workup showed leukocytosis, elevated C-reactive protein and first blood culture showed growth of streptococcus specie. Transthoracic echocardiograph showed mobile echogenic densities on both anterior and posterior mitral leaflets suggestive of vegetation. Computed tomography of brain showed multiple cerebral abscesses. During hospital stay patient developed right leg pain, on ultrasound Doppler showed echogenic thrombus in right popliteal artery was seen. Patient underwent mitral valve replacement surgery, per operative finding showed totally destroyed valve with large vegetation involving left atrium and annulus was found. This case is of major interest that she was early recognized for all possible complications of the disease and treated accordingly with difficult surgery and broad spectrum antibiotics.

Keywords: Infective endocarditis; Giant vegetation; Doppler

Introduction

Infective endocarditis leads to devastating course if not picked and treated on time and it can be life threatening. Mostly it affects diseased or artificial valve or certain birth defects but can involve native valve. It has acute (develops within days) or sub-acute (develops gradually and subtly) over a period of time. It can be caused by bacteria virus or fungi; most common pathogen is streptococcus viridian [1]. Systemic embolization is a known complication of infective endocarditis followed by congestive heart failure. Here we present a case of 45 year old lady with clinical symptoms of infective endocarditis with its complications and unusual per op finding of giant vegetation involving mitral valve and emphasizes prompt treatment with surgical intervention and antibiotic therapy that has proved to improve outcome in patient presenting with infective endocarditis and its complication.

Case Presentation

A 45 year-old-female married resident of Karachi, with no prior history of cardiac disease presented to emergency department with complains of fever, shortness of breath for last 2 months and drowsiness for last 10 days. Fever was low grade; undocumented not associated with rigors or chills and did not have any specific pattern. Shortness of breath was mostly exertion associated with

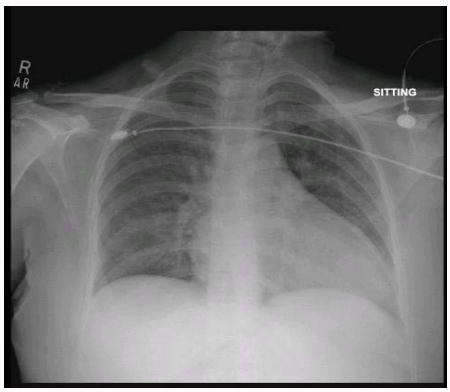

Figure 1: CXR PA view showing cardiomegaly.

OPEN ACCESS

Correspondence:
Madiha Iqbal, Department of Internal Medicine, Aga Khan University Hospital, Resident III, Pakistan;
E-mail: madiha.iqbal@aku.edu

Received Date: *24 Dec 2019*
Accepted Date*: 10 Feb 2020*
Published Date*: 18 Feb 2020*

Citation:
Iqbal M. Infective Endocarditis and Giant Vegetation with Complicated Course. Ann Cardiol Cardiovasc Med. 2020; 4(1): 1033.

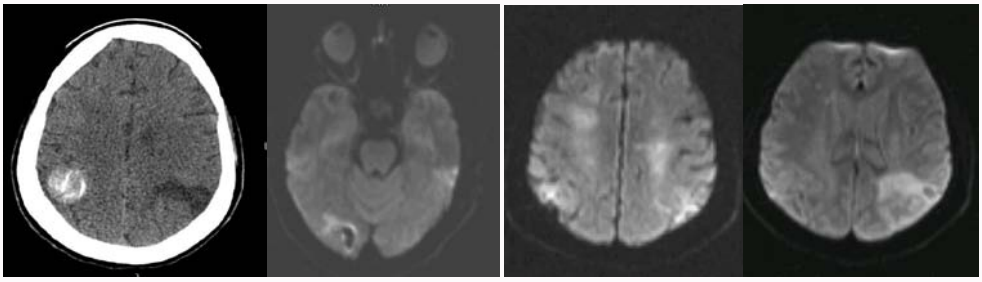

Figure 2: CT and MRI Brain (contrast) showing bilateral hyper intensive signals with calcified meningioma.

orthopnea and paroxysmal nocturnal dyspnea and was affecting her daily activities. Past medical or surgical history was not significant. Social history was unremarkable for any addictions. Presenting vital signs included blood pressures of 140/90 mmHg, heart rate of 89 beats per minute, respiratory rate of 26 breaths per minute and temperature was 37.9 Celsius. On general physical examination she was pale and purpuric rashes on bilateral legs were appreciated. On cardiovascular examination pan-systolic murmur grade III/VI could heard on mitral area radiating to back , decreases in intensity with Valsalva maneuver, no thrill or parasternal heave appreciated. Splenomegaly was appreciated on abdominal examination while respiratory examination was found to be unremarkable.

Neurological assessment showed no focal deficit, Glasgow coma scale was 15/15, normal speech, no sensory defect, cerebellar and cranial nerve examination was found to be normal.

Laboratory studies were concerning for leukocytosis of 11.9 K/uL, hemoglobin of 7.6 gm/dL, and platelet count of 126 K/uL CRP of 15.1 mg/dL (0 mg/dL to 0.5 mg/dL). Other laboratory abnormalities included serum creatinine of 5.2 mg/d/L (0.6 mg/dL to 1.1 mg/dL), and albumin of 2.2 g/d/L. Troponin was 0.112 ng/Ml (0 ng/mL to 0.04 ng/mL), chest X-ray showed cardiomegaly and urine detailed report was positive for >20 red blood cells/HPF (0 to 4 red blood cells/HPF). Transthoracic echocardiograph was done which showed severely dilated left atrium, severe mitral regurgitation and mobile echogenic densities on both anterior and posterior mitral leaflets which are consistent with vegetation (Figure 1).

She was being assessed for fever and empiric antibiotics started before sending two sets of blood cultures. For drowsiness neurology team was consulted and brain imaging was advised. Computed tomography of brain was done which showed multifocal ill-defined low-attenuation in left cerebral hemisphere representing infective foci and incidental finding of calcified meningioma for further evaluation magnetic resonant imaging was advised which showed multiple ill-defined heterogeneous areas in left cerebral hemisphere, consistent with cerebral abscess (Figure 2).

On 4th day of hospital stay patient developed pain in right leg on assessment right leg was found to be cold clammy and feeble distal pulses arterial Doppler showed echogenic thrombus filling the lumen of the right popliteal artery and is showing no color filling on color Doppler. Patient was stabilized with antibiotics and symptomatic treatment and listed for surgery. She underwent mitral valve replacement surgery on 7th day of hospitalization. Valve was found to be destroyed. Vegetation involving whole valve left atrium cavity and annulus. Mitral valve replaced with tissue valve. And patient was kept on surgical intensive care unit for 3 days. Post op rehabilitation was given and she improved and was discharged with full recovery (Figure 3).

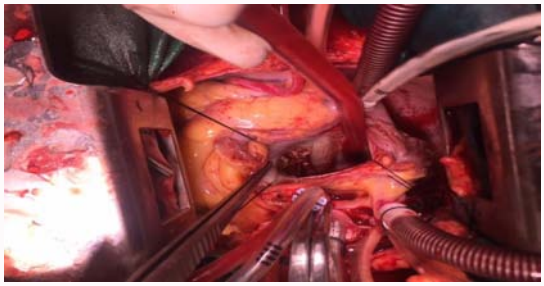

Figure 3: Large vegetation involving Mitral valve, annulus and wall of left atrium.

Discussion

Our case report discusses the unusual large size of vegetation per-operatively and complicated course of disease. Diagnosis of infective endocarditis is defined by Duke's criteria which include clinical findings, blood cultures growing organisms and cardiac imaging, echocardiography is a modality of choice, Duke's criteria does not factor in the size and location of vegetation [2]. Our patient's blood cultures did not show growth of any organism which is attributable to prior use of antibiotics, although echocardiographic findings showed large vegetation involving mitral valve and left atrium. Classical symptoms of IE include fever and associated weight loss and anorexia, in 90% of patients fever is the only presenting complain. Cardiac murmur is observed in 85% of patients which is supported by splenomegaly and cutaneous manifestation like splinter hemorrhages or petechial rash. Complications of E includes valvular insufficiency (50%), Embolic strokes or brain abscess (40%) [3]. Other possible complications include infarctions involving spleen, kidneys and other organs. Definitive diagnosis is made by cardiac imaging includes Transthoracic Echocardiography (TTE) or more sensitive Transesophageal Echocardiography (TEE) [4]. TEE detects pseudo aneurysm and leaflet perforation better than TTE. Large vegetation is associated with higher risk of early death. Association between vegetation size and in hospital mortality and risk of embolization is being shown by various studies. The EASE study has shown treatment of IE with early surgery was associated with lower risk of embolic complications, but no difference in 6 month mortality.

Our patient already developed major complications of IE i.e. septic brain abscess, petechial rashes, and heart failure. It is suggested from prior studies that paravalvular extension with complications urgently required surgery prior to completion of antibiotic therapy [5]. Surgical delay of about four weeks is advised in patients developing

hemorrhagic stroke while patient with brain abscesses may undergo surgery with relatable lower risk as early as possible and it has shown better outcomes and improvement in complication of IE. ESC Guidelines on the management of infective endocarditis published in 2015 proposed new features which include early diagnosis and refinement of surgical indications [6,7].

The patient underwent successful mitral valve replacement surgery and remained stable post op. Along with surgical intervention and supportive treatment with antibiotic and antithrombotic therapy patient showed marked improvement in symptoms and disease process. This highlights that early surgical intervention has better outcomes and improves embolic complications in patients with large vegetation.

References

1. Türkkan D, Yüksel F, Ak S. Central nervous system septic embolism due to infective endocarditis: Autopsy case report. J Inonu University Med Faculty. 2010;17(4):387-9.
2. Wang A, Holland TL, Sexton DJ. Overview of management of infective endocarditis in adults.
3. Murdoch DR, Corey GR, Hoen B, Miró JM, Fowler VG, Bayer AS, et al. Clinical presentation, etiology, and outcome of infective endocarditis in the 21st century: The International Collaboration on Endocarditis-Prospective Cohort Study. Arch Intern Med. 2009;169(5):463-73.
4. Evangelista A, Gonzalez-Alujas MT. Echocardiography in infective endocarditis. Heart. 2004;90(6):614-7.
5. Kang DH, Kim YJ, Kim SH, Sun BJ, Kim DH, Yun SC, et al. Early surgery versus conventional treatment for infective endocarditis. New England J Med. 2012;366(26):2466-73.
6. Habib G, Lancellotti P, Iung B. 2015 ESC Guidelines on the management of infective endocarditis: A big step forward for an old disease. Heart. 2016;102(13):992-4.
7. Bayer AS, Bolger AF, Taubert KA, Wilson W, Steckelberg J, Karchmer AW, et al. Diagnosis and management of infective endocarditis and its complications. Circulation. 1998;98(25):2936-48.