Journal of Dentistry and Oral Biology

Research Article
Published: 11 Feb, 2022

Histological Assessment of Debris in Isthmuses after Using Rotary and Reciprocating Single-File Instruments

Mustafa Gündoğar[1]*, Taha Ozyurek[2], Gianluca Plotino[3], Özgecan Gündoğar[4], Sibel Bektas[5], Hande Ozyürek[6], Gülşah Uslu[7], Guzide Pelin Sezgin[8] and Erhan Erkan[1]

[1]Department of Endodontics, Istanbul Medipol University, Istanbul, Turkey

[2]Department of Endodontics, Bahçeşehir University, Istanbul, Turkey

[3]Grande Plotino & Torsello - Studio di Odontoiatria, Rome, Italy

[4]Bahcelievler Public Hospital, Istanbul, Turkey

[5]Department of Pathology, Istanbul Gaziosmanpasa Training & Research Hospital, Saglık Bilimleri University, Istanbul, Turkey

[6]Private practice, Kocaeli, Turkey

[7]Department of Endodontics, Canakkale Onsekiz Mart University, Canakkale, Turkey

[8]Department of Endodontics, Biruni University, Istanbul, Turkey

Abstract

It was aimed to investigate the presence and amount of debris in isthmuses of mesial root canals of mandibular molar teeth after use of XP-endo Shaper (XPS), One Curve (OC), and Reciproc Blue (RPC Blue) single-file systems histologically. In total, 36 roots having isthmuses between mesial canals were instrumented using XPS, OC, and RPC Blue files (n=12 isthmus/group). Specimens were examined histologically, and the percentage of debris was measured in all canal thirds. Two-way analysis of variance and post-hoc Tukey test were used to analyze the data at 5% significance level. The percentage of debris was significantly lowest in the RPC Blue group at all root canal levels ($P<0.05$). There was no significant difference between XPS and OC groups ($P>0.05$). More debris was found in the apical third than other thirds in all groups ($P<0.05$). Debris in isthmuses after using RPC Blue files was significantly lower than XPS, and OC groups. Final debris in isthmus can negatively alter the prognosis of endodontic treatment. Hence remaining debris after using different instruments should be known.

Keywords: Canal preparation; Dentine debris; Isthmus; Reciprocating motion; Rotary motion

OPEN ACCESS

****Correspondence:***
Mustafa Gündoğar, Department of Endodontics, Istanbul Medipol University, Istanbul, Turkey, Tel: +905065089807;
E-mail: mustafagundogar@msn.com

Received Date*: 05 Jan 2022*
Accepted Date*: 01 Feb 2022*
Published Date*: 11 Feb 2022*

Citation:
Gündoğar M, Ozyurek T, Plotino G, Gündoğar O, Bektas S, Ozyürek H, et al. Histological Assessment of Debris in Isthmuses after Using Rotary and Reciprocating Single-File Instruments. J Dent Oral Biol. 2022; 7(1): 1189. ***ISSN: 2475-5680***

Introduction

Complete preparation and cleaning of the root canal system is challenging, especially for narrow and curved canals [1]. Root canal preparation using rotary file systems did not completely clean the root canal [2]. The presence of residual dentine debris and pulp tissue may be medium for microorganisms and contributed to the failure of root canal treatment [3].

Single-file NiTi systems are widely used in root canal preparation. The first single-file systems on the market featured reciprocating motion [4], but following metallurgical developments in NiTi, the single-file approach was extended to rotary files [5]. XP-endo Shaper (XPS; FKG Dentaire SA, La Chaux-de-Fonds, Switzerland) is thermally treated NiTi file called MaxWire alloy and can be used in rotary motion at an optimal speed of 800 rpm [6]. When the ambient temperature changes from room to intra-canal temperature, the instrument passes from a martensitic phase to an austenitic phase [6].

One Curve (OC; Micro-Mega, Besancon, France) a single file system used in rotary motion, is made with C-Wire heat treatment technology and features improved fatigue resistance as compared with its old generation files such as OneShape (Micro-Mega) and 2 Shape (Micro-Mega) [5]. Reciproc Blue (RPC Blue; VDW, Munich, Germany) files with reciprocating motion is thermally treated, which gives the files blue color and improved flexibility and fatigue resistance as compared with M-Wire Reciproc (RPC; VDW) files [7,8].

An isthmus is a confined and deep extension between root canals. Cleaning is challenging in isthmus because it is frequently clogged with hard and soft tissue debris during instrumentation

with NiTi file systems [9]. Uncleaned isthmuses are dangerous for the success of the treatment, as the debris residues remaining in the isthmus contain pulp tissue and microorganisms [10]. The incidence of isthmus frequently located in the apical part of the root canals has been reported to be approximately 54.8% in the mesial roots of mandibular molar teeth [11].

Several methods have been used for the evaluation of debridement efficacy, such as sectioning techniques [12], micro-Computed Tomography (μCT) [13], and histological evaluations [14], to date, no studies have histologically evaluated the debridement efficacy of XPS (FKG Dentaire SA), OC (Micro-Mega) and RPC Blue (VDW) files. Thus, the aim of the present study was to evaluate and compare the debridement efficacy of these three file systems in isthmuses of mesial roots of mandibular molar teeth using a histological analysis method. The null hypothesis tested in the present study was that there would be no significant difference among the groups in terms of isthmuses cleaning efficacy.

Materials and Methods

Sample size determination

A power calculation was done using the one-way ANOVA test family (G*Power 3.1 software; Heinrich Heine University, Dusseldorf, Germany), including α=0.05 and β=0.95 based on a previous study [3]. Required sample size was determined in each group to be a minimum of 12 teeth.

Sample selection

After ethical committee approval (10840098-604.01.01-E.4563), human mandibular first and second molars extracted from the volunteers aged between 45 to 60 years old due to periodontal reasons having vital pulps were immersed in 6% NaOCl (CanalPro; Coltene, Whaledent Switzerland) for 5 min and then stored in a 0.1% thymol solution at 4°C until usage. Residues on the root surface were removed using hand scalers. Root integrity and the number of existing canals were examined by taking X-rays from different angles. Under 12x magnification (Olympus BX43; Olympus Co, Tokyo, Japan) and using digital radiography, endodontically treated and previously restored teeth, as well as teeth with calcified canals or cracks and internal or external resorption did not include in the study and replaced with other teeth. When evaluated by radiography, teeth with moderately curved mandibular molar mesial roots were preferred for standardization [15]. Canals with buccolingual diameter 2.5 times or more wide than the mesiodistal diameter at a coronal distance of 5 mm from the apex were classified as oval-shaped canals.

CASP crests were flattened for stable reference points and access cavities were prepared. Mesial root canals were scouted with size 15 C-Pilot files (VDW) and samples having larger apical diameter than size 15 C-Pilot file were replaced with new ones. Size 15 C-Pilot file was introduced and advanced in the canal until it was visible in the apical foramen and the working length was determined to be 0.5 mm shorter than this distance. Working lengths longer than 20 ± 1 mm were replaced with new samples. The teeth were then stored in thymol solution at 4°C for the duration of the experiment.

μCT scanning (SkyScan 1172; Bruker microCT, Kontich, Belgium) with 10 μm/pixel resolution and 100 KV and 100 μA power were performed in order to evaluate the presence and classify of any isthmus in the mesial root of mandibular molar teeth [16]. Thirty-six teeth with isthmus in their mesial root canals were selected as a result of scanning. Roots having only isthmuses classified as type II according to Hsu and Kim [17] were used. The specimens were allocated to one of three groups (n=12) using a computer algorithm (http://www.random.org). Anatomical matching between groups confirmed evaluating data normality (Shapiro-Wilk) and homogeneity (two-way ANOVA) between groups as regards to root length and curvature degree (P>0.05).

Sample preparation

The root canals were first covered with aluminium foil and embedded in acrylic resin at 3 mm apical distance from the Enamel-Cementum Junction (CEJ). After the acrylic resin completely polymerized, the roots were removed from the resin and the foil. To simulate the periodontal ligament, silicone impression material (Express XT Light Body Quick; 3M ESPE, Neuss, Germany) was placed in the foil cavity and the specimens were placed back into the resin blocks until the CEJ filled with impression material before it set [18].

Root canal preparations were performed by immersing the roots up to the CEJ in a warm water bath at 37°C, as it may affect the mechanical and physical properties of the files [5,8] and to better reflect the clinical conditions [19].

Twelve mesial roots and 24 root canals (12 mesio-buccal and 12 mesio-lingual) in each group were instrumented using XPS (tip size 30, .01 taper, expandable to 0.04) (group 1), OC (tip size 25, 0.06 taper) (group 2) and RPC Blue R25 files (tip size 25.08 taper in apical 3 mm and regressive variable taper up to the shaft) (group 3) using a Gold Reciproc torque-control endodontic motor (VDW) according to the manufacturer's recommendation (group 1: 1 Ncm and 800 rpm; group 2: 2.5 Ncm and 300 rpm; group 3: RECIPROC ALL setting) on bench top set up. Each instrument was used to prepare only two root canals and then replaced with a new instrument.

XPS; a glide path was established using the size 15 stainless steel K-file (FKG Dentaire SA) and the XPS file was used with light strokes until resistance was felt. After five strokes, the instrument was then removed, and the flutes were cleaned with gauze. The root canal was irrigated, and recapitulation was done using a size 10 stainless steel hand K-file to check the apical patency. The XPS file was used again to proceed to the working length. The instrument was never forced, and it was always kept spinning and moving while in the canal. The instrument was introduced again for 15 additional long gentle strokes to the working length.

OC; after a glide path was established using a size 15 stainless-steel K-file (Micro-Mega), the OC file was used with gentle apical pressure and a brushing motion according to the manufacturer. When resistance was felt, the instrument was removed from the canal, and the flutes were cleaned with gauze. Irrigated and recapitulation using a straight size 10 stainless steel hand K-file to confirm the apical patency was performed. The instrument was used again until the instrument reached to the working length.

RPC Blue; RPC Blue R25 file was used with three in-and-out pecking motions and gentle apical pressure and a brushing motion. When the resistance was encountered the instrument was removed, flutes cleaned and the root canals irrigated. Recapitulation was then performed using a size 10 stainless steel hand K-file to control the patency. The preparation of the apical third was completed using the RPC R25, with the same technique described previously, until the working length was reached.

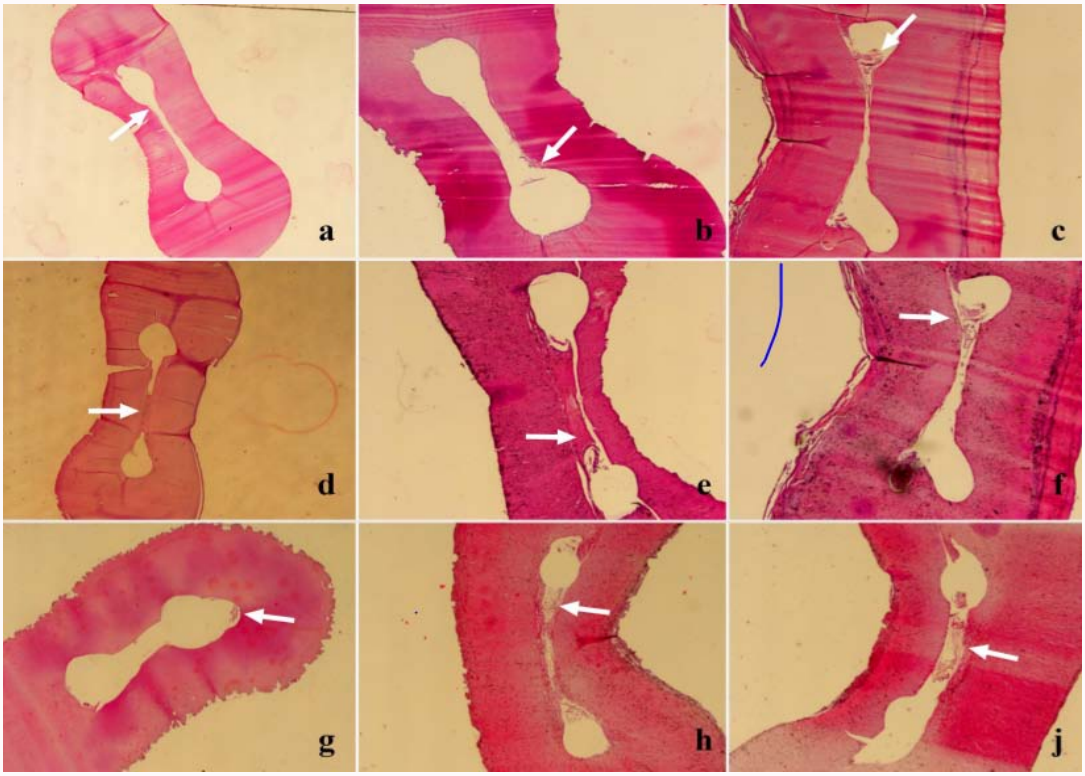

Figure 1: Representative root sections showing debris remnants in the isthmus region at the apical (**a, d, g**), middle (**b, e, h**) and coronal (**c, f, j**) root level after preparation with different single-file nickel titanium instruments: XP-endo Shaper (**a, b, c**), One Curve (**d, e, f**) and Reciproc Blue (**g, h, j**). The white arrows show the residual debris in the samples.

Each root canal was irrigated with a total of 10 mL of sodium hypochlorite solution at 3% concentration (CanalPro; Coltene-Whaledent, Allstetten, Switzerland) and using a 31-gauge double side-vented needle (NaviTip Sideport; Ultradent Products Inc., South Jordan, UT, USA) inserting to 1 mm from the predetermined working length. Final irrigation was performed using 5 mL of ethylenediaminetetra acetic acid at 17% concentration (CanalPro; Coltene-Whaledent) for 2 min (CanalPro; Coltene-Whaledent) followed by 5 ml of 3% sodium hypochlorite (CanalPro) and 5 mL of sterile distilled water. The irrigating solutions were kept at 37°C inserting syringe in a water bath at 37°C before using. An experienced endodontist in root canal instrumentation using the tested files carried out all the procedures.

Histological analysis

After the instrumentation, the specimens were removed from the resin blocks. The specimens were immediately fixed in 10% neutral buffered formalin for 48 h to process histologically. The roots were then demineralized in a solution of equal parts of 22.5% formic acid (vol/vol) and 10% sodium citrate (wt/vol) for 4 wk under constant agitation. Decalcification was evaluated radiographically, and then each specimen was dehydrated in increasing concentrations of ethyl alcohol, clarified in xylene and embedded in paraffin (melting point: 56°C).

The specimens were then divided into three parts: Apical, middle and coronal (5 mm long each). Using a microtome set at 4 µm, a series of approximately 50 slices of 4-µm sections was produced, and one section of every five was stained with hematoxylin and eosin and examined using light microscopy (Leica DM500; Leica Microsystems, Heerbrugg, Switzerland) for searching tissue remnants. A single experienced operator who was blinded to the experiment and the groups performed all the histological and staining procedures. The same operator took images of the specimens using a digital camera (Nikon, Tokyo, Japan) at 2x and 5x magnification. Binarization of the slide images obtained from the different canal thirds was performed with ImageJ software (US National Institutes of Health, Bethesda, USA), and the area occupied by the dentine debris was calculated as a percentage (%) in relation to the total canal area, as based on previous studies [15,20]. Five slices of 4-µm sections were analyzed for each canal third.

Statistical analysis

The Shapiro-wilk test was used to check if the data were normally distributed. Afterwards, the data were analyzed via statistical software package (SPSS 21.0; IBM-SPSS Inc., Chicago, IL, USA) using 2-way analysis of variance and post hoc Tukey tests at 5% significance level.

Results

Table 1 list the mean and standard deviation of the percentage of dentine debris in each group. The analysis of the histological sections taken from the different canal levels revealed that the percentage of residual dentine debris was significantly lower in the RPC Blue group (21.60 ± 0.31) as compared with that in the XPS (25.33 ± 0.47) and OC group (25.33 ± 0.48) at all levels ($P<0.05$) (Table 1). Whereas there was no difference in the percentage of residual dentine debris in the XPS group versus that in the OC group ($P>0.05$) (Figure 1). When the root canal thirds were assessed, the percentage of residual dentine debris was significantly greater in the apical third (24.36 ± 0.32) as compared with that in the middle (20.67 ± 0.37) and coronal thirds (19.78 ± 0.32) ($P<0.05$), whereas there was no significant difference in the percentage of residual dentine debris between the middle and

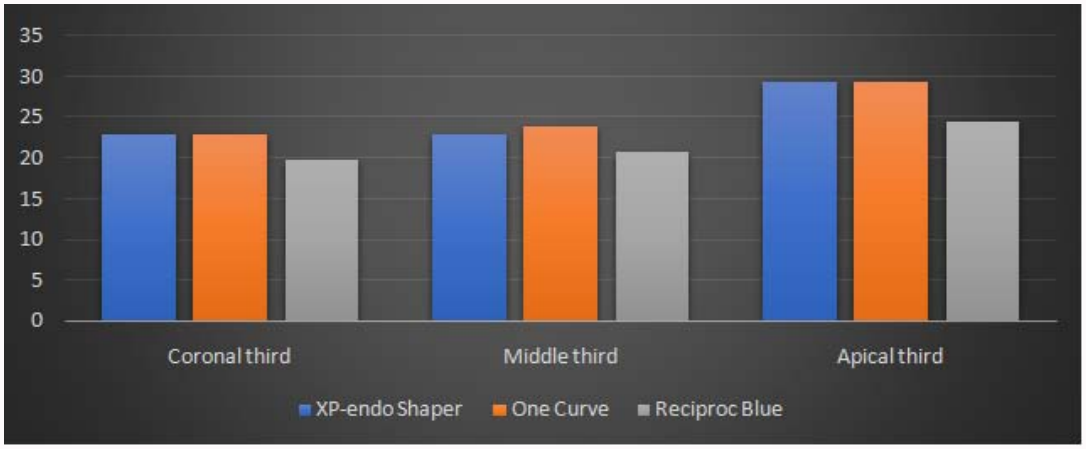

Figure 2: Percentage (%) of Remaining debris for the different groups at the different root levels.

Table 1: Mean ± Standard deviation of the percentage (%) of debris for groups at the different root canal levels.

Groups	Coronal third	Middle third	Apical Third	Total
XP-endo Shaper	22.91 ± 0.48^{ax}	22.82 ± 0.51^{ax}	29.25 ± 0.54^{ay}	25.33 ± 0.47^{a}
One Curve	22.82 ± 0.51^{ax}	23.85 ± 0.37^{ax}	29.31 ± 0.61^{ay}	25.33 ± 0.48^{a}
Reciproc Blue	19.78 ± 0.32^{bx}	20.67 ± 0.37^{bx}	24.36 ± 0.32^{by}	21.60 ± 0.31^{b}

*Different upper letters show statistically significant difference at 5% level (^{a,b} for columns and ^{x,y} for rows)

apical thirds (P>0.05).

Discussion

Accurate and effective biomechanical preparation may influence the success of root canal treatment. Roots and root canals have anatomical variations, such as isthmuses and root canal branches, which represent hard-to-clean regions [10]. In the present study, mesial root canals of mandibular molars were chosen, as its complexity and curvatures of these teeth can make it difficult to clean these regions during chemo-mechanical root canal preparation [9].

According to the results of this study, the debris in isthmuses was significantly lower in the RPC Blue group among the three groups. Thus, the null hypothesis tested in this study was rejected. Various determinants may explain of RPC Blue files' higher cleaning efficiency. These determinants maybe it's S-shaped cross-section, which may enhance the files' cutting efficiency and debris removal ability coronally [21]. The enhanced debridement efficacy may also be due to the higher taper at the tip section of the files and possibly the files' reciprocating motion [22], Bürklein et al [23], previously reported that the cleaning efficiency of Mtwo (VDW) and RPC files was better than that of WO (Dentsply Sirona Endodontics) and ProTaper (Dentsply Sirona Endodontics) NiTi files in the apical third and attributed this to the S-shaped cross-section and small core diameter of the file. In a µCT study, Busquim et al. [24] reported that the cutting efficiency of RPC (VDW) files was superior to that of BioRaCe (FKG) files because of the S-shaped cross-section and positive cutting angle of the file.

Residual debris after root canal instrumentation and irrigation was calculated as a percentage of the area occupied by the debris related to the total root canal area using a histological sectioning method in the present study. The method used has been employed in previous studies to assess the debridement efficacy of NiTi files [25,26]. None of the NiTi single-file systems evaluated in the present study were able to make completely free of debris of mesial root canal isthmuses of mandibular molar teeth, as previously reported in similar studies using different file systems and methodologies [3,24,27,28]. No previous studies have evaluated the cleaning efficiency of OC and RPC Blue files using the histological sectioning method applied in the present study. This evaluation method was adopted due to the technical difficulty in splitting roots with moderate curvature and two canals in sectioning procedures and the cost and disadvantage of µCT (i.e., it does not allow direct observations of specimens).

Belladonna et al. [29] evaluated the root canal cleaning efficiency of RPC and RPC Blue files in mesial roots of mandibular molar teeth using µCT and found no difference between two file systems. Although these two instruments are manufactured using different heat treatments, their similar cleaning efficiencies are likely due to their similar design, tip size, taper and kinematics. Using both µCT and histological sectioning methods, Lacerda et al. [28] reported no significant differences in root canal cleaning obtained with Self-Adjusting File (ReDent-Nova, Ra'anana, Israel), TRUShape (Dentsply Sirona Endodontics) and XPS (FKG Dentaire SA) file systems (Figure2). In an µCT and bacteriological study on mesial root canals of mandibular molars, Siqueira et al. [30] reported no significant differences in root canal cleaning obtained using three different file systems: SAF, Reciproc and Twisted Files (SybronEndo, Orange, CA, USA). In contrast, Guimaraes et al. [31] found that the root canal cleaning efficacy of RPC was lower than that of TRUShape. They concluded that TRUShape and RPC files may promote more contact with the canal walls because of their design properties.

In all three groups of the present study, more residual debris was observed in the apical third of the root canal as compared with that in the middle and coronal thirds. This finding is in similar with that reported in previous studies [23,32,33]. Previous histological evaluations of endodontically treated teeth with apical periodontitis revealed bacterial colonization in the apical region in unprepared areas [34,35], Plotino et al. [36] evaluated canals after root canal treatment using scanning electron microscopy and found a significantly

higher amount of debris in the apical region as compared with that in other regions. The reduced debridement efficacy in the apical region may be related to complex anatomical variations and residual debris (microorganisms) in this region, both of which may have implications for treatment outcomes [37]. Also, the dissolution ability of the sodium hypochlorite is associated with tissue contact. Despite a flexible irrigation needle being used to improve the effectiveness of the irrigation [38,39], a possible limitation of the present study may be that the diameter of the needle (31-gauge) was too large for fluid flow and this may be the main explanation why more residual debris were found in the present study in apical section.

Conclusion

Within the limitations of the present study, the debridement efficacy of the RPC Blue files in the isthmus region between two canals of mesial roots of mandibular first molars were significantly better than that of the XPS and OC files. Significantly more debris was found in the apical third in all the groups as compared with that in the middle and coronal thirds.

References

1. Peters OA. Current challenges and concepts in the preparation of root canal systems: A review. J Endod. 2004;30(8):559-67.
2. Zhao D, Shen Y, Peng B, Haapasalo M. Root canal preparation of mandibular molars with 3 nickel-titanium rotary instruments: A micro-computed tomographic study. J Endod. 2014;40(11):1860-4.
3. Siqueira JF, Araujo MC, Garcia PF, Fraga RC, Dantas CJS. Histological evaluation of the effectiveness of five instrumentation techniques for cleaning the apical third of root canals. J Endod. 1997;23(8):499-502.
4. Yared G. Canal preparation using only one Ni-Ti rotary instrument: preliminary observations. Int Endod J. 2008;41(4):339-44.
5. Staffoli S, Grande NM, Plotino G, Özyürek T, Gündoğar M, Fortunato L, et al. Influence of environmental temperature, heat-treatment and design on the cyclic fatigue resistance of three generations of a single-file nickel–titanium rotary instrument. Odontology. 2019;107(3):301-7.
6. Uslu G, Özyürek T, Yılmaz K, Gündoğar M, Plotino G. Apically extruded debris during root canal instrumentation with reciproc blue, HyFlex EDM, and XP-endo shaper nickel-titanium files. J Endod. 2018;44(5):856-9.
7. Özyürek T, Uslu G, Yılmaz K, Gündoğar M. Effect of glide path creating on cyclic fatigue resistance of reciproc and reciproc blue nickel-titanium files: A laboratory study. J Endod. 2018;44(6):1033-7.
8. Plotino G, Grande NM, Testarelli L, Gambarini G, Castagnola R, Rossetti A, et al. Cyclic fatigue of reciproc and reciproc blue nickel-titanium reciprocating files at different environmental temperatures. J Endod. 2018;44(10):1549-52.
9. Paqué F, Laib A, Gautschi H, Zehnder M. Hard-tissue debris accumulation analysis by high-resolution computed tomography scans. J Endod. 2009;35(7):1044-7.
10. Nair PN, Henry S, Cano V, Vera J. Microbial status of apical root canal system of human mandibular first molars with primary apical periodontitis after "one-visit" endodontic treatment. Oral Surg Oral Med Oral Pathol Oral Radiol Endod. 2005;99(2):231-52.
11. De Pablo OV, Estevez R, Peix Sanchez M, Heilborn C, Cohenca N. Root anatomy and canal configuration of the permanent mandibular first molar: A systematic review. J Endod. 2010;36(12):1919-31.
12. Grande NM, Plotino G, Butti A, Messina F, Pameijer CH, Somma F. Cross-sectional analysis of root canals prepared with NiTi rotary instruments and stainless steel reciprocating files. Oral Surg Oral Med Oral Pathol Oral Radiol Endod. 2007;103(1):120-6.
13. Sinibaldi R, Pecci R, Somma F, Penna SD, Bedini R. A new software for dimensional measurements in 3D endodontic root canal instrumentation. Ann Ist Super Sanita. 2012;48(1):42-8.
14. Vera J, Siqueira Jr JF, Ricucci D, Loghin S, Fernández N, Flores B, et al. One-versus two-visit endodontic treatment of teeth with apical periodontitis: A histobacteriologic study. J Endod. 2012;38(8):1040-52.
15. Schneider SW. A comparison of canal preparations in straight and curved root canals. Oral Surg Oral Med Oral Patho. 197l;32(2):271-5.
16. Neelakantan P, Khan K, Li K, Shetty H, Xi W. Effectiveness of supplementary irrigant agitation with the finisher GF brush on the debridement of oval root canals instrumented with the gentlefile or nickel titanium rotary instruments. Int Endod J. 2018;51(7):800-7.
17. Hsu Y, Kim S. The resected root surface: The issue of canal isthmuses. Dent Clin North Am. 1997;41(3):529-40.
18. Yılmaz K, Özyürek T. Apically extruded debris after retreatment procedure with Reciproc, ProTaper next, and twisted file adaptive instruments. J Endod. 2017;43(4):648-51.
19. Azim AA, Piasecki L, da Silva Neto UX, Cruz AT, Azim KA. Shaper XP. A novel adaptive core rotary instrument: Micro-computed tomographic analysis of its shaping abilities. J Endod. 2017;43(9):1532-8.
20. De-Deus G, Souza EM, Barino B, Maia J, Zamolyi RQ, Reis C, et al. The self-adjusting file optimizes debridement quality in oval-shaped root canals. J Endod. 2011;37(5):701-5.
21. Plotino G, Giansiracusa Rubini A, Grande NM, Testarelli L, Gambarini G. Cutting efficiency of Reciproc and WaveOne reciprocating instruments. J Endod. 2014;40(8):1228-30.
22. Plotino G, Ahmed HM, Grande NM, Cohen S, Bukiet F. Current assessment of reciprocation in endodontic preparation: A comprehensive review - Part II: Properties and effectiveness. J Endod. 2015;41(12):1939-50.
23. Bürklein S, Hinschitza K, Dammaschke T, Schäfer E. Shaping ability and cleaning effectiveness of two single-file systems in severely curved root canals of extracted teeth: Reciproc and WaveOne versus Mtwo and ProTaper. Int Endod J. 2012;45(5):449-61.
24. Busquim S, Cunha RS, Freire L, Gavini G, Machado ME, Santos MDA. A micro-computed tomography evaluation of long-oval canal preparation using reciprocating or rotary systems. Int Endod J. 2015;48(10):1001-6.
25. Arruda MP, Carvalho Junior JR, Miranda CE, Paschoalato C, Silva SRC. Cleaning of flattened root canals with different irrigating solutions and nickel-titanium rotary instrumentation. Braz Dent J. 2009;20(4):284-9.
26. da Frota MF, Filho IB, Berbert FLCV, Sponchiado Jr EC, Marques AAF, Garcia LDFR. Cleaning capacity promoted by motor-driven or manual instrumentation using ProTaper Universal system: Histological analysis. J Conserv Dent. 2013;16(1):79-82.
27. De-Deus G, Garcia-Filho P. Influence of the NiTi rotary system on the debridement quality of the root canal space. Oral Surg Oral Med Oral Pathol Oral RadiolEndod. 2009;108(4):e71-6.
28. Lacerda MFLS, Marceliano-Alves MF, Perez AR. Cleaning and shaping oval canals with 3 instrumentation systems: A correlative micro-computed tomographic and histologic study. J Endod. 2017;43(11):1878-84.
29. Belladonna FG, Carvalho MS, Cavalcante DM, Fernandes JT, de Carvalho Maciel AC, Oliveira HE, et al. Micro-computed tomography shaping ability assessment of the new blue thermal treated reciproc instrument. J Endod. 2018;44(7):1146-50.
30. Siqueira JF Jr, Alves FR, Versiani MA, Rôças IN, Almeida BM, Neves MA, et al. Correlative bacteriologic and micro-computed tomographic analysis of mandibular molar mesial canals prepared by self- adjusting file, Reciproc, and Twisted File systems. J Endod. 2013;39(8):1044-50.
31. Guimaraes L, Gomes CC, Marceliano-Alves MF, Cunha RS, Provenzano

JC, Siqueira Jr JF. Preparation of oval-shaped canals with TRUShape and Reciproc systems: A micro–computed tomography study using contralateral premolars. J Endod. 2017;43(6):1018-22.

32. Haapasalo M, Endal U, Zandi H, Coil JM. Eradication of endodontic infection by instrumentation and irrigation solutions. Endod Topics. 2005;10(1):77-102.

33. Hülsmann M, Gressmann G, Schäfers F. A comparative study of root canal preparation using FlexMaster and HERO 642 rotary Ni-Ti instruments. Int Endod J. 2003;36(5):358-66.

34. Ricucci D, Siqueira JF Jr, Bate AL, Pitt Ford TR. Histologic investigation of root canal-treated teeth with apical periodontitis: A retrospective study from twenty-four patients. J Endod. 2009;35(4):493-502.

35. Ricucci D, Siqueira JF Jr. Biofilms and apical periodontitis: Study of prevalence and association with clinical and histopathologic findings. J Endod. 2010;36(8):1277-88.

36. Plotino G, Özyürek T, Grande NM, Gündoğar M. Influence of size and taper of basic root canal preparation on root canal cleanliness: A scanning electron microscopy study. Int Endod J. 2019;52(3):343-51.

37. Siqueira JF Jr, Rôças IN. Clinical implications and microbiology of bacterial persistence after treatment procedures. J Endod. 2008;34(11):1291-301.

38. Abou-Rass M, Piccinino MV. The effectiveness of four clinical irrigation methods on the removal of root canal debris. Oral Surg Oral Med Oral Pathol. 1982;54(3):323-8.

39. Chow TW. Mechanical effectiveness of root canal irrigation. J Endod. 1983;9(11):475-9.