



Histogram Analysis of ADC Values to Differentiate Glioblastoma Multiforme and Metastasis

Shesnia Salim Padikkalakandy Cheriya^{*} and Rishal Reshin Brayin Pokkantakath

Radio-diagnosis and Nuclear Medicine, Dalian Medical University, Dalian, People's Republic of China

Abstract

A histogram analysis of apparent diffusion coefficient parameters namely minimum intensity, maximum intensity, median intensity, mean value, standard deviation, volume count, voxel value sum, root mean square, skewness, kurtosis, relative deviation, uniformity, range, mean deviation and variance (obtained from Omni kinetics software) was performed on the entire tumor region of diffusion weighted images of 21 Glioblastoma Multiforme (GBM) and 11 Metastatic Tumor (MET) patients (derived from Functool 2 software). The results showed volume count and voxel value sum as statistically significant and more sensitive and specific parameters (based on p-value and receiver operator characteristics curve analysis respectively) in differentiating GBM and MET.

Keywords: Glioblastoma multiforme; Metastatic tumor; Resonance imaging

Introduction

The differences in metabolism, vasculature, cells, micro environmental factors, structure and function make quantitative estimation of tumor heterogeneity necessary to improve drug discovery, treatment planning and therapeutic response. The 2 most common malignant brain tumors that appear similar on medical imaging but follow different treatment protocols are Glioblastoma Multiforme (GBM) and Metastatic Tumor (MET) [1]. Various Magnetic Resonance Imaging (MRI) techniques (DCE-MRI, DWI, DTI, SWI) have been used over the years to study tumor heterogeneity using Apparent Diffusion Coefficient (ADC) maps. However, there haven't been successful studies conducted to differentiate them on the basis of entire tumor region using all the histogram parameters of the ADC maps [2,3].

OPEN ACCESS

*Correspondence:

Shesnia Salim Padikkalakandy Cheriya^{*}, Radio-diagnosis and Nuclear Medicine, Dalian Medical University, Dalian, People's Republic of China, E-mail: shesniasalim@hotmail.com

Received Date: 17 Feb 2022

Accepted Date: 04 Mar 2022

Published Date: 14 Mar 2022

Citation:

Cheriya SSP, Pokkantakath RRB. Histogram Analysis of ADC Values to Differentiate Glioblastoma Multiforme and Metastasis. *Ann Clin Radiol.* 2022; 4(1): 1018.

Copyright © 2022 Shesnia Salim Padikkalakandy Cheriya^{*}. This is an open access article distributed under the Creative Commons Attribution License, which permits unrestricted use, distribution, and reproduction in any medium, provided the original work is properly cited.

Objectives

The purpose of this study is to analyze GBM and MET using histogram parameters of ADC on the entire tumor region and thereby uses its diagnostic value to differentiate them.

Methods and Materials

A retrospective study was carried out at the Department of Medical Imaging at first affiliated hospital of Dalian Medical University. The MRI particularly Diffusion Weighted Images (DWI) of 21 patients with GBM and 11 patients with MET previously confirmed by pathology were evaluated and ADC maps using ADW 4.6 workstation Functool 2 software were recorded, then with Omni kinetics software ADC parameters namely minimum intensity, maximum intensity, median intensity, skewness, kurtosis, mean deviation, relative deviation, standard deviation, range, voxel value sum, Root Mean Square (RMS), uniformity, variance, mean value and volume count of all the 3D merged Region of Interest (ROI) images that included both the entire tumor and peripheral edema were reported. Further, Shapiro Wilk test was performed to determine if the data was normal or not and if found normal, independent sample t-test was performed and if not normal, non parametric U Mann-Whitney test was done for statistical analysis (spss19.0). Receiver Operator Characteristic (ROC) curve tests were also performed to calculate Area under Curve (AUC) and thereby determine the diagnostic value of each significant parameter. The efficacies of the parameters were assessed in terms of cut-off values, sensitivity and specificity. $P < 0.05$ was considered statistically significant (Figure 1).

Results

1. According to the derived data, the mean \pm std. deviation values of max intensity, median intensity, mean value, standard deviation, skewness, volume count, uniformity, range and relative deviation related to GBM cases are higher while those of min intensity, variance, kurtosis, voxel

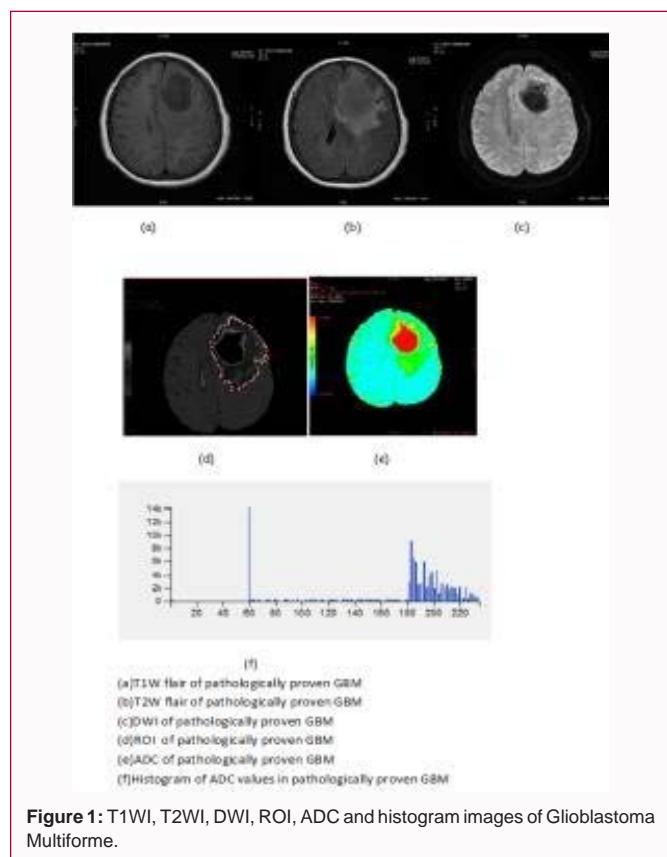


Figure 1: T1WI, T2WI, DWI, ROI, ADC and histogram images of Glioblastoma Multiforme.

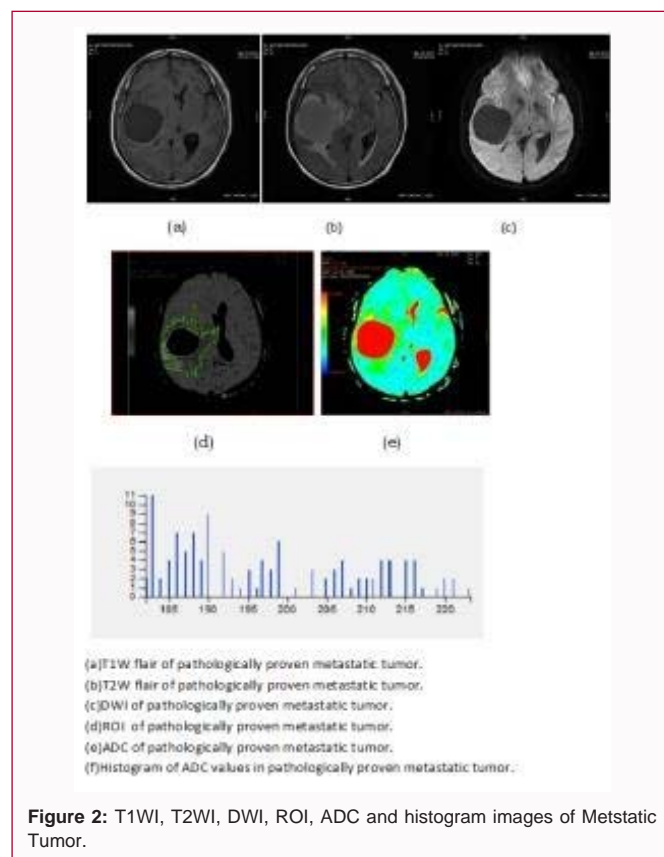


Figure 2: T1WI, T2WI, DWI, ROI, ADC and histogram images of Metastatic Tumor.

value sum, RMS and mean deviation corresponding to MET cases are greater (Table 1).

2. It can also be noted that volume count, voxel value sum and RMS show $p < 0.05$ and are statistically significant while minimum intensity, maximum intensity, median intensity, mean value, standard deviation, skewness, uniformity, range, variance, kurtosis, voxel value sum, mean deviation and relative deviation parameters are not statistically significant (Table 1).

3. Furthermore in Table 1.2, the ROC curve analysis shows satisfactory results of AUC values for voxel value sum and volume count and unsatisfactory results for RMS based on cut-off, sensitivity and specificity data.

Discussion

1. Histogram analysis is an image post processing technique that reflects the disturbance of all ADC values within the ROI further demonstrating tumor heterogeneity. In this study, ROIs encompassed the tumor parenchyma and peripheral edema that included cystic, necrosis and hemorrhagic areas characteristic of GBM and MET.

2. Based on the obtained diffusion measurements of GBM's and MET's, our hypothesis that there might be a distinct differentiation between the two tumor types was satisfactorily verified by A) Volume Count i.e. the total volume within the ROI of the parameter map significantly higher in GBM described by its larger volume; B) Voxel Value Sum i.e. the sum of voxels within the ROI of the parameter map—significantly higher in MET explained by its faster growth rate and increased invasive properties; C) Root Mean Square i.e. the square-root of the mean of the squares of the values in the image ROI and is another measure of the magnitude of the image

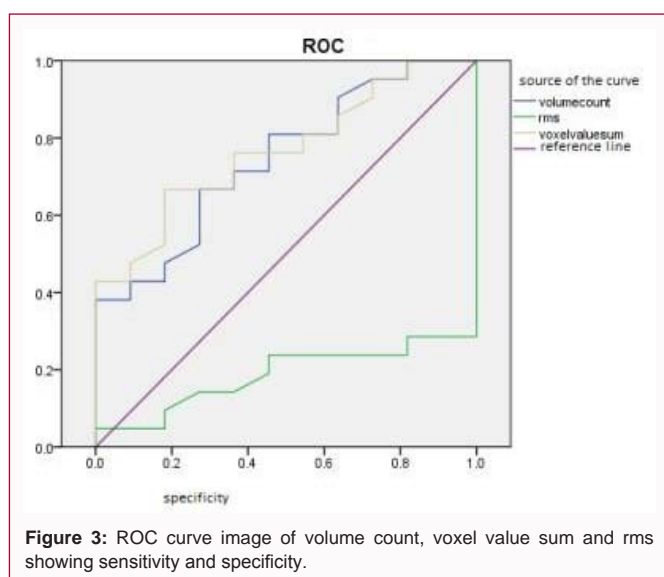


Figure 3: ROC curve image of volume count, voxel value sum and rms showing sensitivity and specificity.

values—significantly higher in MET.

3. The ROC curve analysis points out that voxel value sum and volume count are the true sensitive and specific parameters for the diagnostic evaluation of this study.

4. GBM's as well as MET's showing tumor heterogeneity with necrotic and cystic regions facilitating more diffusion of water molecules compared to the diffusion in normal areas and the effect of their surrounding edema on the directionality of water diffusion would be an explanation as to why there is minimal difference in the un-significant ADC values of GBM's and MET's.

Table 1: Values of histogram parameters expressed as mean \pm std. deviation.

Parameter	GBM (mean \pm std.dev)	Metastasis (mean \pm std. dev)	P value
Min intensity	44 \pm 67.89	57.63 \pm 61.40	0.277
Max intensity	233.14 \pm 6.45	230.72 \pm 10.70	0.209
median intensity	186.37 \pm 30.50	178.92 \pm 39.73	0.087
Mean Value	183.99 \pm 25.24	176.42 \pm 30.70	0.258
Std.deviation	29.82 \pm 18.43	29.42 \pm 21.99	0.336
Variance	1212.9 \pm 1294.77	1305.92 \pm 1587.51	0.827
Volume count	72747.38 \pm 6509.47	27681.90 \pm 32016.07	0.043
Skewness	-1.53 \pm 1.76	-2.09 \pm 4.35	0.677
Kurtosis	11.65 \pm 8.67	28.87 \pm 63.81	0.796
Voxelvaluesum	136 \times 33 \times 10 ⁵ \pm 122.48 \times 10 ⁵	437.54 \times 10 ⁴ \pm 498.48 \times 10 ⁴	0.015
rms	55.07 \pm 89.30	180.88 \pm 25.05	0.002
uniformity	0.819 \pm 0.15	0.80 \pm 0.19	0.827
Range	189.09 \pm 71.85	173.09 \pm 61.28	0.187
Mean deviation	71.01 \pm 25.23	78.55 \pm 30.68	0.258
Relative deviation	27611.10 \pm 26182.51	21441.93 \pm 40854.26	0.065

Table 2: ROC curve analysis of volume count, voxel value sum and rms.

Parameter	AUC	P value	Cutoff value	Sensitivity	Specificity
Volume count	0.745	0.025	39.5 \times 10 ³	0.667	0.727
Voxelvaluesum	0.766	0.015	85.7 \times 10 ⁴	0.667	0.812
rms	0.186	0.04	204.295	0.00	1.00

Conclusion

Hence, the above results indicate that histogram analysis of ADC values based on entire tumor regions help in differentiating GBM and MET in a better way than the earlier methods of using ADC maps on specific regions.

References

1. Tsougos I, Svolos P, Kousi E, Fountas K, Theodorou K, Fezoulidis I, et al. Differentiation of glioblastoma multiforme from metastatic brain tumor using proton magnetic resonance spectroscopy, diffusion and perfusion metrics at 3 T. *Cancer Imaging*. 2012;12(13):423-36.
2. Chena XZ, Yinb XM, Aia XM, Chenc Q, Li SW, Dai JP. Differentiation between brain Glioblastoma multiforme and solitary metastasis: Qualitative and quantitative analysis based on routine MR Imaging. *Am J Neuroradiol*. 2012;33(10):1907-12.
3. Pierre L, Silvia PM, James TP, Lucia F, Salinas CL. Gradient of apparent diffusion coefficient values in peritumoral edema helps in differentiation of glioblastoma from solitary metastatic lesions. *Am J Roentgenol*. 2014;203(1):163-9.