Annals of Plastic and Reconstructive Surgery

Case Report
Published: 18 Jun, 2019

Double Flap for Trochanteric Pressure Sore Reconstruction: A Case Report

Luca Negosanti[1], Sara Tedeschi[2], Fabio Filippo Trapani[2], Luca Gaiani[3], Massimo Palmonari[3], Donatella Brillanti Ventura[1], Rita Capirossi[1], Micaela Battilana[1] and Rossella Sgarzani[4]*

[1]Department of Plastic Surgery, Montecatone Rehabilitation Institute, Italy

[2]Division of Infectious Diseases, S. Orsola-Malpighi University Hospital, Italy

[3]Division of Orthopedics Surgery, S. Maria della Scaletta Hospital, Italy

[4]Department of Plastic Surgery, AUSL Romagna, Italy

Abstract

Introduction: Trochanteric pressure sores can be quite difficult to treat; especially in case of large bone involvement that requires a wide debridement. The residual wound is large, deep and the reconstruction must ensure a complete fill of all death spaces then it must be covered with an adequate tissue to allow the healing and reduce the risk of recurrence.

Case Presentation: We report the case of a spinal cord injured patient affected by a trochanteric pressure sore. The reconstruction was achieved using a combination of a muscle and a muscle cutaneous flap from the thigh. The result was a complete healing of the wound with no recurrence at 18 months.

Conclusion: In this cases muscle or musculocutaneous flaps are the better choice because they permits to use a good volume of viable tissue. In some cases that flap can be combined to obtain a better result.

Keywords: Trochanteric pressure; Musculocutaneous flaps; Adequate tissue

OPEN ACCESS

Correspondence:
Luca Negosanti, Department of Plastic Surgery, Montecatone Rehabilitation Institute, Via Mazzini 2/2, 40138, Bologna, Italy, Tel: 0039051391884; E-mail: luca.negosanti81@gmail.com

Received Date: *17 May 2019*
Accepted Date*: 14 Jun 2019*
Published Date*: 18 Jun 2019*

Citation:
Negosanti L, Tedeschi S, Filippo Trapani F, Gaiani L, Palmonari M, Brillanti Ventura D, et al. Double Flap for Trochanteric Pressure Sore Reconstruction: A Case Report. Ann Plast Reconstr Surg. 2019; 3(2): 1029.

Introduction

Trochanteric pressure sores can be quite difficult to treat because the debridement must be wide in order to remove all infected or unviable tissues. The gold standard is the gilderstone arthroplasty [1]. The residual wound is usually very large, deep and the reconstruction must ensure a complete fill of all death spaces and a cover with an adequate tissue to allow the healing and reduce the risk of recurrence.

We report a case of complex trochanteric wound repaired by a combination of a muscle and a musculocutaneous flaps in a spinal cord injured patient.

Case Presentation

A 50 years old male patient affected by a spinal cord injury was referred to us for the treatment of a trochanteric pressure sore. The wound was characterized by purulent exudate and bone exposure. Imaging reported the presence of an inflammatory process on the great trochanter and the femoris head. We planned a two time surgical procedure. The first surgery consisted in a wide debridement of the wound. Through a horizontal incision we expose all the wound edges and all soft tissue macroscopically unviable were removed. Bone excision involved the great trochanter and a part of the femoris head that appeared unviable (Figure 1). Specimens of soft and bone tissues were histologically and microbiologically analyzed in order to assess the presence of infection.

After hemostasis the wound was treated with topical negative pressure therapy with polyurethane foam and a negative pressure of 120 mmHg. The initial empiric antibiotic therapy was Piperacillin/Tazobactam 4, 5 g 3 times each day. The analysis reported the presence of osteomyelitis and no modification of the antibiotic therapy were required according the results.

After 1 month we planned the reconstructive procedure. We decided to combine two flaps: A rectus femoris muscle flap and a vastus lateralis musculocutaneous flap in order to obtain a complete fill of the cavity and an adequate cover [2-5].

Figure 1: Right trochanter pressure sore after debridement.

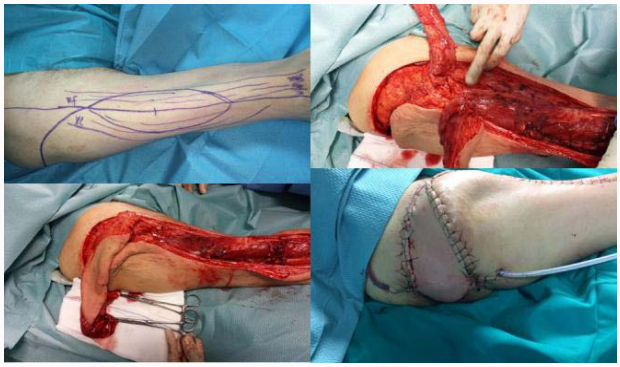

Figure 2: Second surgery: Drawn on the thigh; the two flaps were harvested and then transposed to cover the defect; final result.

We draw on the thigh a line between the anterior superior iliac spine and the lateral border of the patella and an incision was made on the intermuscular septum between the rectus femoris and the vastus lateralis. The rectus was exposed and dissected; the distal insertion was cut and the muscle was elevated proximally until the pedicle was visualized. Then the skin paddle of 15 cm × 10 cm was harvested on the vastus lateralis and left attached to it. The muscle was divided from the vastus intermedius and from the distal insertion. Then the composite flap was elevated until the pedicle was exposed. That was not necessary to dissect the two vascular pedicles because the arc of rotation was sufficient to reach the defect.

The rectus flap was used to fill the deep surface of the wound and fixed around the residual femoris. The vastus lateralis flap was used to cover the wound, its deep surface was fixed to the rectus flap; the muscle was then fixed to the wound edges and the skin paddle covers the flap (Figure 2). Three drains were inserted and removed after 1 week, while stitches after 3 weeks. During this period the patient did not stay on the right side and did not sit on chair. The antibiotic therapy continued for 8 weeks. After stitches removal we started sitting the patient 1 hour for 1 week and then increase 1 h each week to 4 hours. A continue monitoring of the wounds was made. No complications occurred. After 18 months of follow up the trochanteric region is completely heal with no signs of recurrence (Figure 3).

Discussion

Trochanteric pressure sores are difficult to treat because are frequently complicated by osteomyelitis involving the great trochanter and often extended to the femoris. In these cases a wide

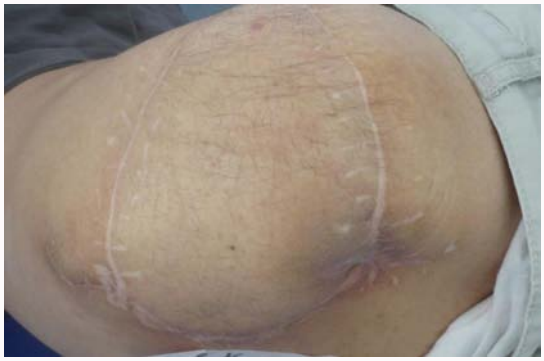

Figure 3: Result after 18 months.

debridement must be performed and the residual defect is large and deep. To obtain a good reconstruction is necessary to fill death spaces and cover wound surface with adequate tissues in order to ensure healing and to reduce the risk of recurrences. In case of infected wounds we preferred to perform a surgical approach in two times. In the first one we perform the debridement and in the second one the reconstruction.

In these cases, muscle or musculocutaneous flaps can be the better choice in order to reconstruct the defect [6]. The procedure also allows reconstructing the defect with a good volume to ensure a reduction of the risk of recurrence. In spinal cord injured patients the leg muscles are generally atrophic and a single flap may not provide enough bulk. The presence of death spaces can lead to complications, as seroma and hematoma.

Rectus femoris and vastus lateralis are two muscle with nearly pedicle, easy to dissect and can also be harvested as musculocutaneous flap using a large skin paddle. The dissection of both flaps is made through a single incision on the thigh, and the donor site is easily closed by direct suture. The arc of rotation allow to reach the deep surface of the defect, with no tension, and the combination of a muscle flap positioned deeply and covered with a musculocutaneous flap permits to fulfill the defect and cover the surface with a skin paddle. This approach is easy and can be apply in all the cases of trochanteric sores.

Conclusion

Trochanteric pressure sores are quite difficult to treat because it frequently results in large and deep wound to cover. The reconstruction must ensure a complete fill of all death spaces and an adequate cover to reduce the risk of recurrence. In these cases we believe that a two time surgical approach can be useful. In the first time the debridement allow to remove all unviable tissues. Then an antibiotic treatment permits to treat the infection and the reconstruction can be performed on a "clean" wound. In this cases muscle or musculocutaneous flaps are the better choice because they permits to use a good volume of viable tissue. In some cases that flap can be combined to obtain a better result.

References

1. Gilderstone GR. The Classic: Acute pyogenic arthritis of the hip: An operation giving free access and effective drainage. Clin Orthop Relat Res. 1982;170:3-7.

2. Bell MS, Earnshaw PH. Rectus femoris musculocutaneous flaps for trochanteric ulcers. Can J Surg. 1981;24(5):496-7.

3. Drimmer MA, Krasna MJ. The vastus lateralis musculocutaneous flap. Plast Reconstr Surg. 1987;79:560-6.

4. Schmidt AB, Fromberg G, Ruidisch MH. Applications of the pedicled vastus lateralis flap for patients with complicated pressure sores. Spinal Cord. 1997;35:437-42.

5. Larson DL, MAchol JA, King DM. Vastus lateralis flap reconstruction after girdlestone arthroplasty: Thirteen consecutive cases and outcomes. Ann Plast Surg. 2013;71(4):398-401.

6. Acartuk TO. Treatment of large ischial ulcers communicating with the hip joint with proximal femoral resection and reconstruction with a combined vastus lateralis, vastus intermedius and rectus femoris musculocutaneous flap. J Plast Reconstr Aesthet Surg. 2009;62(11):1497-502.