



Dermoscopy of Targetoid Hemosiderotic Hemangioma

Lei Zhu and Xianbiao Zou*

Department of Dermatology, Fourth Medical Center, General Hospital of PLA, Beijing, China

Clinical Image

A female Patient, 26 years old. A black papule on the right upper back for 15 months in the early stages of her pregnancy, her husband found that she had the lesion on her back with no pain or itching. She has not paid attention to it for more than a year, because of her pigmented nevus in other parts of her body. In the past 4 months. There have been purple-red ecchymosed around it, which gradually expanded and the color is sometimes dark and sometimes light. The pigmented nevus in other parts of the body did not appear similar, so the patient came to our hospital for diagnosis.

The illustrated a single targetoid hemosiderotic hemangioma (hobnail hemangioma) lesion with a diameter of 5 mm is from the back of a 26-year-old girl. A target-shaped lesion was seen on the back, with a purple papule in the center and a reddish ring around it (Figure 1). Dermatoscopy revealed multiple purple-red lacunar structures in the center, orange rings around it, and reddish rings of varying colors on the outside (Figure 2).

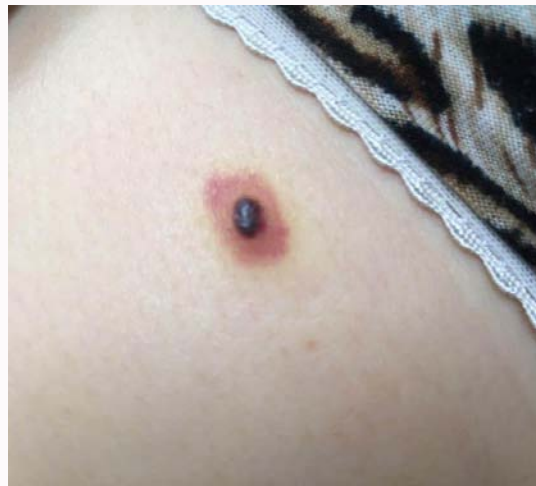

Figure 1:

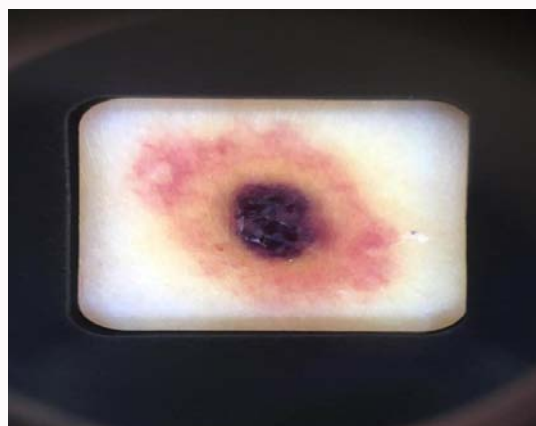


Figure 2:

OPEN ACCESS

*Correspondence:

Xianbiao Zou, Department of Dermatology, Fourth Medical Center, General Hospital of PLA, Beijing, China, E-mail: xbzou@126.com

Received Date: 14 May 2019

Accepted Date: 14 Jun 2019

Published Date: 18 Jun 2019

Citation:

Zhu L, Zou X. Dermoscopy of Targetoid Hemosiderotic Hemangioma. *Ann Clin Case Rep.* 2019; 4: 1671.

ISSN: 2474-1655

Copyright © 2019 Xianbiao Zou. This is an open access article distributed under the Creative Commons Attribution License, which permits unrestricted use, distribution, and reproduction in any medium, provided the original work is properly cited.