Annals of Plastic and Reconstructive Surgery

Case Report
Published: 15 Oct, 2019

Delayed CSF Leak in Intensity-Modulated Radiation Therapy for a NPC Patient

*Wen-Xiang Gao[1], Wu Jian[2], Jian Bo Shi[1] and Yin-Yan Lai[1]**

[1]Department of Otolaryngology, Sun Yat-sen University, China

[2]Department of Otolaryngology, Guangzhou Red Cross Hospital, China

Abstract

Introduction: Radiation Therapy (RT) is primary treatment for Nasopharyngeal Carcinoma (NPC). Although Intensity-Modulated Radiotherapy (IMRT) can reduce the amount of radiation to normal tissues around the lesion, the amount of radiation to the lesion area is not significantly reduced. Skull base Osteoradionecrosis (ORN) is one of the most serious complications of RT and can even lead to death. This is the first published case report to our knowledge of cerebrospinal fluid leakage induced by post-RT skull base osteoradionecrosis.

Case Presentation: A 60-year-old man, who diagnosed NPC staged as T1N1M0 in 2003 and received 68GY30 times RT for primary tumor, was diagnosed as "Cerebrospinal Fluid (CSF) rhinorrhea (left side); Purulent meningitis" in 2017. We did an emergency repair of the cerebrospinal fluid leakage by nasal endoscope approach and found two small dural defects where located in the lateral wall of the left sphenoid sinus just as the pre-operated CT scan. No rhinorrhea meningitis complained in the follow 2 years. But in 2019 spring, the patient complained a recurrent rhinorrhea by no incentives. We arranged CT scan and an MRI hydrography examination for the patient and found ethmoid-like defect change in bottom of the right sphenoid sinus bone this time and no tumor recurrence was observed. So we did a second time right-side endoscopic transsphenoidal approach CSF leakage repair operation. Then the patient recovered and regular endoscope follow-up showed no evidence of cerebrospinal fluid rhinorrhea. Since the patient has no history of trauma, we speculate that cerebrospinal fluid rhinorrhea is caused by bone necrosis after radiotherapy. This is a very rare case. Bone necrosis and osteoporosis after radiotherapy lead to bone defect in bilateral sphenoid sinuses at different stages leading to cerebrospinal fluid rhinorrhea. This case report is helpful for clinical study of adverse reactions of intensity modulated radiation therapy.

Conclusion: Radiation Therapy (RT) is one of the most effective treatments for NPC; however, the risk of cerebrospinal fluid leakage should be considered by the use of Intensity-Modulated Radiotherapy (IMRT). Emergency surgical treatment is required when CSF leakage is identified because the leakage will not be healed with conservative treatment.

Keywords: Cerebrospinal fluid; Radiation therapy; Skull base osteoradionecrosis; NPC

OPEN ACCESS

***Correspondence:**
Yin-Yan Lai, Department of Otolaryngology, The First Affiliated Hospital, Sun Yat-sen University, 58 Zhongshan Road II, Guangzhou, Guangdong 510080, China, E-mail: laiyy3@mail.sysu.edu.cn

Received Date: *17 Sep 2019*
Accepted Date*: 07 Oct 2019*
Published Date*: 15 Oct 2019*

Citation:
Gao W-X, Jian W, Bo Shi J, Lai Y-Y. Delayed CSF Leak in Intensity-Modulated Radiation Therapy for a NPC Patient. Ann Plast Reconstr Surg. 2019; 3(4): 1040.

Introduction

Cerebrospinal Fluid (CSF) rhinorrhea can be occurred when there is defected in the skull base. Unusually, trauma, tumor and surgery are the most common causes of the skull base defected [1]. But here, we found a case that skull base defect was raised directly by the Intensity-Modulated Radiotherapy (IMRT), and Cerebrospinal Fluid (CSF) rhinorrhea followed. Radiation Therapy (RT) is the primary treatment for Nasopharyngeal Carcinoma (NPC). But RT can exert both acute and chronic effects on the tissues surrounding the nasopharynx. In the past 20 years, Intensity Modulated Radiotherapy (IMRT) has replaced the traditional radiotherapy and used for Nasopharyngeal Carcinoma (NPC). Although intensity-modulated radiotherapy can reduce the amount of radiation to normal tissues around the lesion, the amount of radiation to the lesion area is not significantly reduced. As a result, side effects are inevitable. Early complications such as mucositis and the peak of skin reaction start in the first few weeks of radiotherapy. Severe and acute side effects are more frequent in high dose radiation patients. Skull base Osteoradionecrosis (ORN) is one of the most serious complications of RT and can even lead to death. A review data reported by Xiaoming Huang showed that the incidence of skull base ORN was 1.04% [2]. The average latency interval from the completion of RT to the diagnosis of skull base ORN was 45.57 months [2]. Although the skull base



Figure 1: Case data of the patients treated NPC in Sun Yat-sen University Cancer Center in 2003. a) The discharge summary of the patients, including patient diagnosis and radiotherapy program. b) Pathological diagnosis of the patients. c) The diagnosis report of the enhanced CT scan of neck and nasopharynx. d) The diagnosis report of the enhanced MRI of nasopharynx.

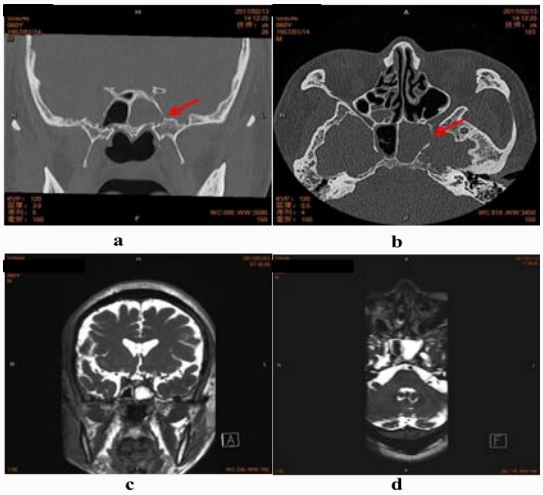

Figure 2: The coronal and horizontal position CT and MRI scan of the patient in the first time of CSF rhinorrhea in 2017. a,b) CT scan showed bone defect in the lateral wall of the left side sphenoid sinus (Red arrow). c,d) MRI showed T2WI hydrography high signal in the left sphenoid sinus cavity.

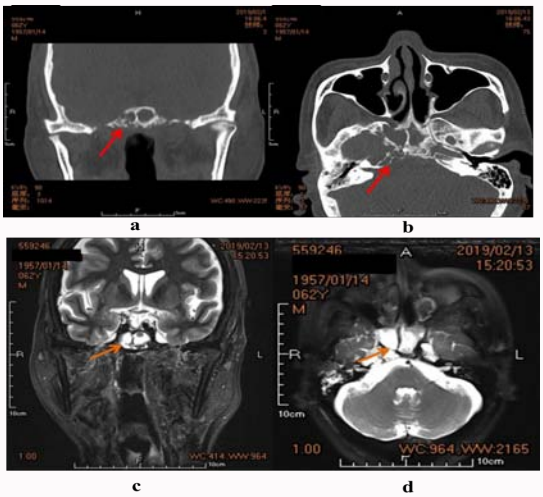

Figure 3: The coronal and horizontal position CT and MRI scan of the patient in the second time of CSF rhinorrhea in 2019. a,b) CT scan showed in the bottom of the right side sphenoid sinus, bone were ethmoid-like defect (Red arrow). c,d) MRI showed T2WI high signal connect the intradural and the sphenoid (Orange arrow).

ORN was not rarely seen in post-RT patient, the Cerebrospinal Fluid (CSF) directly caused by ORN after was seldom seem in clinic. We present a rarely case of skull base defect which remarkably was simply caused by iatrogenic radiation, lead to Cerebrospinal Fluid (CSF) rhinorrhea leakage occurred.

Case Presentation

A 60-year-old man, who diagnosed NPC (Pathological types was poorly differentiated squamous cell carcinoma) staged as T1N1M0 in 2003 and received 68GY30 times IMRT for primary tumor and 50GY35 times RT for regional lymph nodes in Sun Yat-sen University Cancer Center, first visited our clinic complaining of a headache in his forehead and had high fever for 3 days in 2017. He showed us the Computed Tomography (CT) scan and Magnetic Resonance Imaging (MRI) report which did in 2003 proved the right side of nasopharyngeal carcinoma. But according to the report's description, no obvious bone destruction was found in the skull base and no tumor invasion and bone destruction was found in the walls of sphenoid sinus (Figure 1).

Then immediately CT scan was performed and we found suspicious bone defect of lateral wall of the left sphenoid sinus (Figure 2a and 2b). But no evidence of NPC recurrence was found. Similar results were found on magnetic resonance imaging (Figure 2c and 2d), suggesting that T2 weighting high signal of cerebrospinal fluid were connected to intracranial lesions at the bone defect site. The patient was diagnosed as "Cerebrospinal Fluid (CSF) rhinorrhea (left side); purulent meningitis". Since the patient has no history of trauma or surgery, we speculate that cerebrospinal fluid rhinorrhea is caused by bone necrosis after radiotherapy. Emergency repair of CSF leakage was performed by an endoscopic transnasal approach. Under careful endoscopic observation, efflux of CSF synchronizing with pulsation was identified from two small dural defects where in the lateral wall of the left sphenoid sinus just as the pre-operated CT scan. Fat tissue was widely patched over the defects and fixed in place with fibrin glue. No rhinorrhea was recognized after the surgery. The patient fully recovered his condition 1 month after the surgery and had a regular follow-up. No rhinorrhea and meningitis complained in the follow 2 years.

But in 2019 spring, the patient complained a recurrent rhinorrhea by no incentives. Interestingly, we inquired about the patient's condition in detail and found that it's a right side Cerebrospinal Fluid (CSF) rhinorrhea this time. The patient even suffered from aspiration pneumonia. We arranged CT scan and an MRI hydrography examination for the patient and found ethmoid-like defect change in bottom of the right sphenoid sinus bone this time and no tumor recurrence was observed (Figure 3). We can see cerebrospinal fluid signal communicated intracranial and extracranial in ethmoid defect bone (Figure 3a and 3b). Biochemical detection of rhinorrhea further confirmed cerebrospinal fluid rhinorrhea. So this is a very rare case. Bone necrosis and osteoporosis after radiotherapy lead to bone defect in bilateral sphenoid sinuses at different stages leading to cerebrospinal fluid rhinorrhea. So we did a second time right-side endoscopic transphenoid approach CSF leakage repair operation.

a b c

Figure 4: The endoscopic repair of Cerebrospinal Fluid (CSF) leakage in the right sphenoid sinus in 2019. a) The endoscopic appearance of the right sphenoid cavity, submucosal effusion of sphenoid sinus can be seen (Red arrow). b) Endoscopic appearance of ethmoid-like bone changes in the right sphenoid sinus (Black arrow). c) Electric coagulation to created fresh wounds before repair.

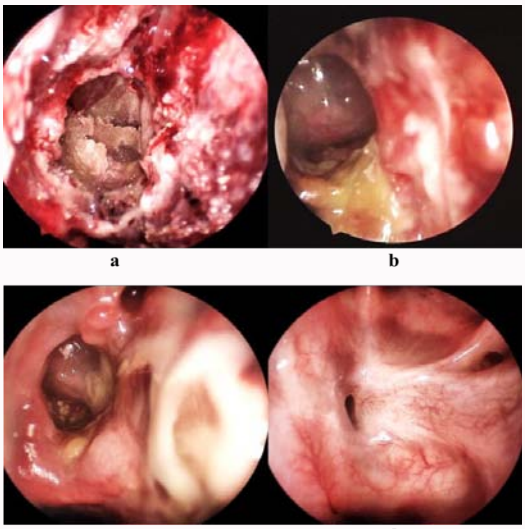

a b c d

Figure 5: The nasal endoscopic follow-up after operation. a) 7 days after repair, residual gelatin sponge can be seen in the right sphenoid sinus. b) 14 days after operation, fat tissue can be seen but no sphenoid sinus effusion. c) 3 months follow-up, transplanted graft grew well and right sphenoid sinus becomes epithelialization. d) the orifice of the left sphenoid sinus, no sign of cerebrospinal fluid rhinorrhea was seen during follow-up after the first repair operation.

Just as the first time, after we fully contoured the sphenoid sinus, we found the sub mucosal edema in the right sphenoid sinus cavity. Then we remove the edematous mucosa and seethe ethmoid-like bone defect in the bottom of the right sphenoid cavity (Figure 4). This is a very good hint. It shows that the sphenoid sinus mucosa is perfect and the occurrence of cerebrospinal fluid rhinorrhea is not caused by trauma, but by spontaneous bone necrosis of the sphenoid sinus. The cerebrospinal fluid flows out of this bone defects. Instead of rushing to repair defects, we use electric coagulation to burn the surrounding mucosa to create fresh wounds. This could help the graft tissue survive. Then we took the autologous muscle tissue and separated it into small pieces for filling. The advantage of using small pieces of muscle tissue for filling is that it is dense, does not float on cerebrospinal fluid, and grows well. Fascia and fibrin glue were covered in the external layer and the operation was done. In one month and half year follow-up, we found that the transplanted graft grew well and no evidence of cerebrospinal fluid rhinorrhea was found in bilateral nasal cavity (Figure 5).

Discussion

CSF rhinorrhea might occur either spontaneously or secondary to accidental trauma or iatrogenic injury. Frontal sinus, ethmoidal roof, ethmoidal fossa, sphenoid sinus and lateral recess are common sites of cerebrospinal fluid rhinorrhea. Direct invasion of tumors, trauma and sinus operation are three common reasons. However, cerebrospinal fluid rhinorrhea caused by skull base Osteonecrosis (ORN) after radiotherapy for nasopharyngeal carcinoma has not been reported. Skull base ORN is a serious complication of NPC and can cause pathologic fractures and lead to serious complications, such as internal carotid artery hemorrhage [3,4]. The damage to vascular endothelial cells in bone after radiation [5] and reducing the activity of osteoblasts and enhancing absorption of the bone matrix is the main pathophysiology of ORN. All of these effects can be observed by imaging long before clinical symptoms emerge [6]. There is a lack of consensus on diagnosis and management, so there have been few studies on the incidence and associated factors of skull base ORN. Skull base ORN was correlated with T stage and was 2.4% in T4 patients, which was greater than that in T1 to T3 patients (0.5%) [2]. These results may occur because T4 patients often have invasion into the skull base, and when the tumor disappears after RT, the bone surface loses its normal mucosa and becomes ischemic and hypoxic due to a lack of microcirculation, eventually leading to ORN [7]. Furthermore, the risk of skull base ORN increased with the RT dose [8]. In our case, the patient received 68 Gy/30 times of radiotherapy for the primary tumor in the right pharyngeal recess, with an average dose of 2.27 Gy per time. The latest technology Intensity-Modulated Radiotherapy (IMRT) technology was used in the radiotherapy at that time. Regular follow-up was performed in every year and no recurrence was found. But interestingly, 14 years later, spontaneous cerebrospinal fluid rhinorrhea occurred successively in the left and right sphenoid sinuses which may also be related to the intensity modulation technology in 2003. The bone of the right sphenoid sinus floor showed ethmoidal changes, which was a typical osteonecrosis phenotype after radiotherapy. This is the first report of cerebrospinal fluid rhinorrhea caused by skull base osteonecrosis after radiotherapy for nasopharyngeal carcinoma in the world. As osteoporosis becomes more serious with age, the bone of sphenoid sinus slope may appear necrosis and ethmoid defect again. We have used large fascia to cover the sphenoid sinus floor extensively during the operation, but we do not have good experience to draw lessons from. The main reason for pedicled nasal septum mucosal flap was not chosen for repair was that the vascular might be atherosclerotic after radiotherapy. Because covering the defect in the bottom wall of sphenoid sinus needs to be twisted at a larger angle, it would likely affect the blood supply of the flap. What' more, the nasal septum flap was too large to the sinus cavity. But we can't guarantee that the patient will have cerebrospinal fluid rhinorrhea again. Once it happens, the only way to treat may be another operation. This case suggests that cerebrospinal fluid rhinorrhea caused by skull base necrosis after radiotherapy of nasopharyngeal carcinoma may be one of the delayed complications of intensity modulated radiotherapy of nasopharynx. Now that Intensity-Modulated Radiotherapy (IMRT) has been widely used in nasopharynx, more similar pathologies may occur in the future. Further study about the incidence and treatment of cerebrospinal fluid rhinorrhea caused by skull base necrosis after radiotherapy for nasopharyngeal carcinoma may be necessary.

Since the patient lost the CT and MRI images taken in 2003, we can only present his history of nasopharyngeal cancer treatment in the form of Chinese cases and reports. This may be our limitation.

Conclusion

The risk of CSF leakage caused by NPC IMRT was low but noteworthy. Emergency surgical treatment is required when CSF leakage is identified because the leakage will not be healed with conservative treatment.

References

1. McMains KC, Gross CW, Kountakis SE. Endoscopic management of cerebrospinal fluid rhinorrhea. Laryngoscope. 2004;114(10):1833-7.
2. Han P, Wang X, Liang F, Liu Y, Qiu X, Xu Y, et al. Osteoradionecrosis of the skull base in nasopharyngeal carcinoma: Incidence and risk factors. Int J Radiat Oncol Biol Phys. 2018;102(3):552-5.
3. Wang HC, Hwang JC, Peng JP, Hsieh CH, Liliang PC. Tension pneumocephalus a rare complication of radiotherapy: A case report. J Emerg Med. 2006;31(4):387-9.
4. Jimenez-Jimenez E, Marti SS, Villas MV. Tension pneumocephalus related to radiotherapy for nasopharyngeal carcinoma. Case Rep Oncol Med. 2014;2014:327380.
5. Chen Y, Liu MZ, Liang SB, Zong JF, Mao YP, Tang LL, et al. Preliminary results of a prospective randomized trial comparing concurrent chemoradiotherapy plus adjuvant chemotherapy with radiotherapy alone in patients with locoregionally advanced nasopharyngeal carcinoma in endemic regions of China. Int J Radiat Oncol Biol Phys. 2008;71(5):1356-64.
6. Lyons A, Ghazali N. Osteoradionecrosis of the jaws: Current understanding of its pathophysiology and treatment. Br J Oral Maxillofac Surg. 2008;46(8):653-60.
7. Abdel Khalek Abdel Razek A, King A. MRI and CT of nasopharyngeal carcinoma. AJR Am J Roentgenol. 2012;198(1):11-8.
8. Law SC, Lam WK, Ng MF, Au SK, Mak WT, Lau WH. Reirradiation of nasopharyngeal carcinoma with intracavitary mold brachytherapy: An effective means of local salvage. Int J Radiat Oncol Biol Phys 2002;54(4):1095-113.