



## Current and Emerging Therapies in Functional Rhinoplasty

Henry LE<sup>1\*</sup> and Friedman OL<sup>2</sup>

<sup>1</sup>Department of Medicine, University of Pennsylvania, USA

<sup>2</sup>Department of Otorhinolaryngology, University of Pennsylvania, USA

### Abstract

**Purpose of Review:** This article reviews the anatomy and physiology of the nasal valves as well as current and emerging techniques to correct nasal valve collapse.

**Overview of Findings:** Functional rhinoplasty has been shown to significantly improve quality of life in patients with nasal valve collapse. There are several techniques available to perform this procedure and the decision as to how to proceed is usually determined by physician preference and patient presentation. Given this individualized approach, this review details a number of options available in the field as well as the advantages and disadvantages of the most commonly used techniques. Emerging therapies for treatment of nasal valve collapse utilize innovative materials for nasal valve repair but continue to focus on quality of life improvement.

**Summary:** This article seeks to provide physicians performing functional rhinoplasty with an updated review of the various techniques to correct nasal valve collapse.

**Keywords:** Functional rhinoplasty; Nasal airway obstruction; Nasal vestibular stenosis

### Introduction

Nasal airway obstruction is a common condition that can be caused by several structural and mucosal abnormalities within the nose. In recent years, nasal valve collapse has been increasingly recognized as a major contributor to such obstruction [1-3]. Furthermore, addressing nasal valve collapse has been shown to significantly improve patient quality of life [4-6]. As such, functional rhinoplasty is now a commonly performed procedure and has consequently evolved in technique. Amidst this evolution, it is now expected that functional considerations are included in all types of rhinoplasty.

There are currently several approaches and grafts that can be used for the repair of nasal vestibular stenosis (nasal valve collapse) and the decision as to how to proceed generally depends on patient presentation and surgeon preference. Given this individualized approach, it is essential that surgeons performing functional rhinoplasties are well-informed on these different techniques as well as future directions within the field. This review will address the anatomic and physiologic underpinnings of nasal valve collapse as well as the current and emerging methods to treat this condition to better inform patient care and continue to improve quality of life outcomes after this procedure.

### Anatomic and Physiologic Overview

Airflow dynamics within the nose are mediated by a system of valves. Apaydin noted that this system includes the septal valve (nasal septum), turbinal valve (inferior turbinates), and the internal and external valves [7]. The internal and external valves are slit-like segments within the nose that mediate air flow through the nasal passage. The nasal valve area is bounded by the septum, the caudal aspect of the upper lateral cartilages (ULC) and lower lateral cartilages (LLC), the lateral nasal wall, the nasal floors and sometimes the head of the inferior turbinate (Figure 1) [8].

As air passes into the nose during inspiration, it accelerates through the nasal valves given their small cross-sectional area. This acceleration causes a decrease in intraluminal pressure and, if this negative pressure overcomes the anatomic rigidity of the nasal side wall during ventilation, collapse will occur [3,9,10]. Flow rates of 30 liters per minute within a nostril have been shown to cause partial collapse [10-12]. An understanding of the anatomy and physiology of the nasal valves is

### OPEN ACCESS

#### \*Correspondence:

Laura E. Henry, Department of Medicine, Perelman School of Medicine, University of Pennsylvania, 3400 Civic Center Boulevard, Philadelphia, PA 19104, USA, E-mail: Laura.Henry@pennmedicine.upenn.edu

Received Date: 14 Sep 2018

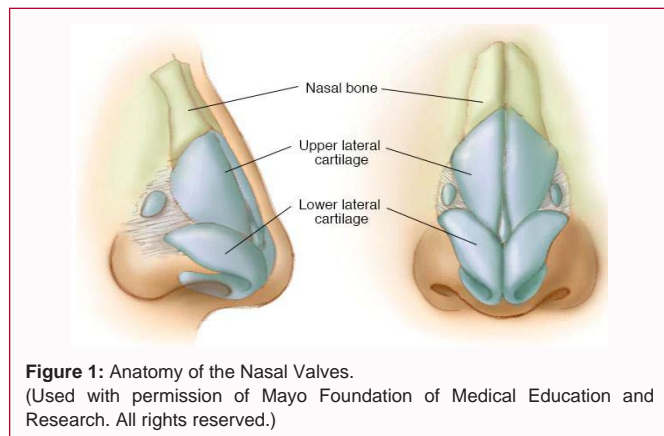
Accepted Date: 09 Oct 2018

Published Date: 11 Oct 2018

#### Citation:

Henry LE, Friedman OL. Current and Emerging Therapies in Functional Rhinoplasty. *Ann Plast Reconstr Surg*. 2018; 2(3): 1020.

Copyright © 2018 Henry LE. This is an open access article distributed under the Creative Commons Attribution License, which permits unrestricted use, distribution, and reproduction in any medium, provided the original work is properly cited.



paramount in recognizing nasal valve collapse and creates a better appreciation for the mechanisms of the various techniques.

### The internal nasal valve

The boundaries of the internal nasal valve (INV) include the ULC, the septum, the floor of the nose, and possibly the anterior head of the inferior turbinate [13]. The INV is the narrowest portion of the nasal airway with a cross-sectional area of 55 mm<sup>2</sup> to 83 mm<sup>2</sup> and an angle of 10 to 15 degrees [8,13]. With such a small radius across the valve, airflow can reach 125 mph within this chamber during heavy inspiration [14]. These dimensions make the INV the primary determinant of nasal air flow, accounting for approximately 50% of nasal resistance, and a major contributor to nasal obstruction [15,16].

Based on the physiology described above, any insult to the rigidity of the lateral side wall can cause INV compromise. INV collapse is often characterized as either a static or dynamic process. Static compromise most often results from narrowing of the middle third of the nose [17,18]. The most common cause of this narrowing is previous nasal surgery. Over-resection of the dorsal hump and division of the ULCs from the septum without reconstructing the attachment are the main contributors to this iatrogenic cause [19]. Other causes include incisional intranasal scars as well as congenital side wall flaccidity, aging, and trauma [19,20]. Dynamic internal nasal valve collapse is characterized by narrowing of the ULC and middle third of the nose that only occurs with active inspiration and is not visible externally in the absence of inspiration [17].

### The external nasal valve

The external nasal valve (ENV), commonly referred to as the nasal inlet, is bound medially by the medial crus of the LLC and inferiorly by the nasal spine and the soft tissues over the nasal floor [9]. The ENV area may be subcategorized into zones 1 and 2 when discussing lateral wall instability, a common contributor to nasal valve pathology. Zone 1 encompasses the inferior border of the LLC and scroll area. Zone 2 corresponds to the boundaries traditionally associated with the external nasal valve described above [20].

External nasal valve collapse is a dynamic process whereby the alar margin of the nose collapses, which is visible externally [3,8]. Main causes of ENV collapse are anatomic and iatrogenic in nature. Anatomic causes include narrow pyriform aperture, nasal tip ptosis, and thinned nasal sidewalls due to cephalically malpositioned LLC [8]. Anatomic changes associated with aging, predominately the weakening of the fibrous attachments of the scroll region and the interdomal ligaments, have also been implicated in ENV collapse

[21]. Surgical causes of ENV collapse include over-resection of the lower lateral cartilages during rhinoplasty and post-operative soft tissue contraction [9].

## Current Surgical Techniques

Given its role as a major contributor to airway obstruction, nasal valve disorders have been managed with a number of medical and surgical treatments in recent years [22-33]. Functional rhinoplasty describes a series of techniques used to correct this collapse. Functional rhinoplasty has been shown to substantially improve quality of life in patients who report nasal valve obstruction and have evidence of nasal valve collapse on physical exam [4,34,35]. While a number of different approaches to the functional rhinoplasty exist, all aim to address nasal function without sacrificing cosmesis [17]. The primary difference in the various techniques used for functional rhinoplasty is the type of graft that is used, which is often dictated by the specific region affected. While many studies demonstrate positive post-operative outcomes with a variety of techniques, very few studies exist comparing these methods head-to-head [1,30,35-42]. Indications for particular techniques derive from the valve that is compromised (internal or external), the cause of the collapse, and whether it is a static or dynamic impairment to airflow.

### Surgical techniques for the internal valve

Both static and dynamic problems can lead to INV collapse. Static collapse is due to a narrowing of the middle third of the nose at rest. Dynamic collapse occurs during inspiration as a result of narrowing of the ULC and middle third.<sup>21</sup> Grafts used to correct INV collapse strengthen the medial crura or expand the nasal valve angle by repositioning the lateral cartilages [8].

**Batten graft:** For patients with decreased structural integrity congenitally or after previous surgery, a batten graft is useful for correcting the deficiency. These grafts, fashioned from septal or auricular cartilage, can be inserted into a pocket at the site of lateral nasal wall collapse with a limited intercartilaginous endonasal incision. Often, the graft is also fixed with mattress sutures to the ULC. The use of this technique is limited by its inability to correct deformities of the middle vault and the valve angle [8].

**Spreader graft:** First described by Sheen in 1984, a spreader graft has been a mainstay of therapy to correct static obstruction caused by narrowing of the valve angle or the middle vault [43]. A spreader graft can be placed unilaterally or bilaterally between the dorsal septum and ULCs via an open or endonasal approach [8,20,43]. While spreader grafts are generally accepted to be effective in improving airflow, they can negatively impact patient aesthetics by widening the nasal dorsum [44].

**Autospreader graft:** Autospreader grafts, first introduced in the 1990's by Oneal and Berkowitz, utilize the redundant dorsal portion of the upper lateral cartilage following dorsal hump reduction, folding it inwards to act as a spreader and correct middle third narrowing [45]. An advantage to this graft is that it does not require harvesting of septal cartilage. The efficacy of the autospreader graft remains uncertain, with some studies demonstrating improvement in Nasal Obstruction Symptom Evaluation (NOSE) scores while others showing no significant difference with or without autospreaders [46,47].

**Butterfly graft:** The butterfly graft, crafted from auricular cartilage, has become increasingly popular in recent years. This

technique has been well-studied for both primary and secondary rhinoplasty and has been shown to improve nasal function and cosmesis [8,17,48]. This graft is placed over the dorsum of the nose using an endonasal or external approach and is secured with a suture to the ULC on each side, therefore acting as a spring and widening the nasal valve angle [48]. The potential for visible widening of the middle third has been addressed by beveling the edges of the graft or shaving down the dorsal septum [3].

**Dorsal onlay graft:** A dorsal onlay spreader graft, as described by Alsarraf and Murakami, can also be used for correction of the middle vault [49]. This graft is sutured to the upper lateral cartilages to widen the INV angle.

**Flaring sutures:** Flaring sutures are occasionally used to correct INV collapse. Flaring sutures are horizontal mattress sutures that fulcrum over the ULCs that are often used in conjunction with other corrective techniques [22,27,50,51]. Disadvantages of this technique, when certain techniques are used, include the need for external incisions, drilling anchor locations, and potential relaxation of the suture [3,8]. As such, this technique is often times reserved for patients who are poor candidates for rhinoplasty.

### Surgical techniques for the external valve

Correction of external nasal valves requires increasing the cross-sectional area and restoring rigidity and strength to the lateral sidewall. This restoration is most commonly achieved with a variety of cartilage grafts.

**Alar batten graft:** An alar batten graft, derived from septal or auricular cartilage, can be inserted through a marginal incision or a limited alar-facial stab approach to restore the integrity of the lateral crura. A marginal incision approach utilizes an opening along the caudal margin of the lower lateral cartilage with a pocket for the graft extending towards the alar-facial groove. In the alar-facial stab approach, an incision is made in the alar-facial groove and a pocket is made through the alar fibrofatty tissue extending to the soft tissue triangle of the alar rim [21]. The potential disadvantage of this graft is aesthetic in nature as there can be noticeable fullness at the graft site [52].

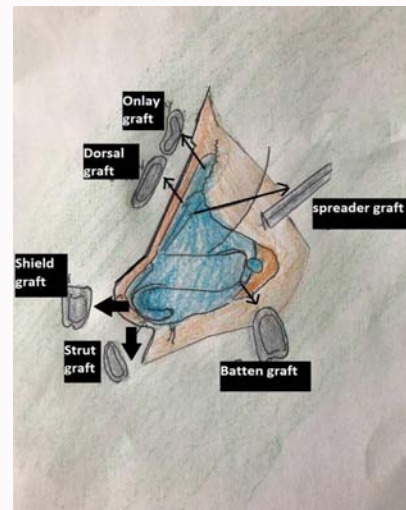
**Alar rim graft:** The alar rim graft, most often placed in patients with cephalic malposition of the lower lateral cartilage with poor alar support, can be used for static or dynamic collapse of the external nasal valve [53]. Cartilage is grafted from the septum or rib and formed into a 1 mm to 3 mm strip. The graft is then placed in a pocket along the alar rim [54].

**Lateral crura graft:** Lateral crura strut grafts and lateral crura transposition techniques can be used in cases of dynamic external valve collapse when the lateral crura are malpositioned [3,8]. While this technique has been shown to improve functionality, cosmetic outcomes are variable, especially in thin-skinned patients. If the graft is applied as an overlay, the area can appear bulky and, if placed as an underlay, it can have visible edges that actually crowd the nasal vestibule [3].

**Lateral crus pull-up suture:** The lateral crus pull-up suture is occasionally used for external nasal valve collapse. The sutures rotate the lateral crus of the LLC in the superolateral direction to provide rigidity to the lateral wall [8,33].

### Emerging Techniques

In 2014, Gassner et al. introduced the stairstep graft as an



**Figure 2:** Graft Options for Functional Rhinoplasty. (Original work by B.B. Friedman)

alternative to the alar strut graft for the correction of ENV collapse [55]. Placement of this graft utilizes a transvestibular approach to ultimately create a pocket lateral to the piriform crest. Auricular or septal cartilage is shaped so that it spans the lateral two-thirds of the lateral crus and overlays the piriform crest. This graft has been shown to improve functionality and aesthetics in a small sample size of patients [55].

In 2014, Craig et al. published a cadaveric study demonstrating the use of an upper lateral strut graft to improve INV patency [56]. In this study, the upper lateral strut grafts were placed in subperichondrial pockets along the ULC and over the piriform apertures in 6 cadavers. Grafts were secured to the dorsal septum. While this study was limited by small sample size, they demonstrated statistically significant improvement in mean cross-sectional area of pre-operationally narrowed INVs.

Bioabsorbable implants are emerging as a possible therapy for patients with severe Nasal Obstruction Symptom Evaluation (NOSE) scores due to lateral wall insufficiency. These implants, made of bioabsorbable polymers, have been recently studied in patients with or without concurrent septoplasty or turbinate reduction. Stolovitzky et al. showed that patients receiving the implant had considerable reduction in NOSE scores [57]. The most significant complications associated with the implant are related to retrievals.

### Conclusion

Nasal valve collapse has emerged as a prominent contributor to the pervasive problem of nasal obstruction. Myriad surgical approaches exist with no single technique considered superior, and measurement of post-operative outcomes relies on subjective patient surveys. As such, it is paramount that rhinoplasty surgeons possess a solid understanding of the anatomic and physiologic fundamentals of nasal valve collapse as well as the multitude of grafts and surgical techniques for functional rhinoplasty (Figure 2). Choice of technique relies on the specific needs of the patient as determined by preoperative evaluation and intraoperative considerations.

### References

1. Constantian MB, Clardy RB. The relative importance of septal and nasal valvular surgery in correcting airway obstruction in primary and secondary

- rhinoplasty. *Plast Reconstr Surg.* 1996;98(1):38-54.
2. Cannon DE, Rhee JS. Evidence-Based Practice. Functional Rhinoplasty. *Otolaryngol Clin North Am.* 2012;45(5):1033-43.
  3. Barrett DM, Casanueva FJ, Cook TA. Management of the Nasal Valve. *Facial Plast Surg Clin North Am.* 2016;24(3):219-34.
  4. Saleh AM, Younes A, Friedman O. Cosmetics and function: Quality-of-Life changes after rhinoplasty surgery. *Laryngoscope.* 2012;122(2):254-9.
  5. Rhee JS, Poetker DM, Smith TL, Bustillo A, Burzynski M, Davis RE. Nasal Valve Surgery Improves Disease-Specific Quality of Life. *Laryngoscope.* 2005;115(3):437-40.
  6. Spielmann PM, White PS, Hussain SSM. Surgical techniques for the treatment of nasal valve collapse: a systematic review. *Laryngoscope.* 2009;119(7):1281-90.
  7. Apaydin F. Nasal Valve Surgery. *Facial Plast Surg.* 2011;27(2):179-91.
  8. Ghosh A, Friedman O. Surgical Treatment of Nasal Obstruction in Rhinoplasty. *Clin Plast Surg.* 2016;43(1):29-40.
  9. Constantian MB. The Incompetent External Nasal Valve. *Plast Reconstr Surg.* 1994;93(5):919-31.
  10. Bridger GP, Proctor DF. Maximum Nasal Inspiratory Flow and Nasal Resistance. *Ann Otol Rhinol Laryngol.* 1970;79(3):481-8.
  11. Haight JS, Cole P. The site and function of the nasal valve. *Laryngoscope.* 1983;93(1):49-55.
  12. Howard BK, Rohrich RJ. Understanding the nasal airway: Principles and practice. *Plast Reconstr Surg.* 2002;109(3):1128-46.
  13. Papel Ira D, Frodel JL, Holt GR, Larrabee WF, Park SS, Styles JM, et al. *Facial Plastic and Reconstructive Surgery.* 4<sup>th</sup> ed. Thieme Medical Publishers, Incorporated; 2006:1024.
  14. Teichgraeber JF, Gruber RP, Tanna N. Surgical Management of Nasal Airway Obstruction. *Clin Plast Surg.* 2016;43(1):41-6.
  15. Anand VK, Isaacs R. Nasal Physiology and Treatment of Turbinate Disorders. *Aesthetic Plast Surg.* 1994;20.
  16. Kimmelman CP. The problem of nasal obstruction. *Otolaryngol Clin North Am.* 1989;22(2):253-64.
  17. Friedman O, Coblens O. The Conchal Cartilage Butterfly Graft. *Facial Plast Surg.* 2016;32(1):42-8.
  18. Weissman JD, Most SP. Trends in functional rhinoplasty. In: *Advanced Aesthetic Rhinoplasty: Art, Science, and New Clinical Techniques.* New York: Springer. 2013;12:137.
  19. Friedman O, Cekic E, Gunel C. Functional Rhinoplasty. *Facial Plast Surg Clin North Am.* 2017;25(2):195-199.
  20. Motamedi KK, Stephan SJ, Ries WR. Innovations in nasal valve surgery. *Curr Opin Otolaryngol Head Neck Surg.* 2016;24(1):34-6.
  21. Deroe AF, Younes AA, Friedman O. External nasal valve collapse repair: The limited alar-facial stab approach. *Laryngoscope.* 2011;121(3):474-9.
  22. Park SS. The flaring suture to augment the repair of the dysfunctional nasal valve. *Plast Reconstr Surg.* 1998;101(4):1120-2.
  23. Gassner HG, Friedman O, Sherris DA, Kern EB. An alternative method of middle vault reconstruction. *Arch Facial Plast Surg.* 2006;8(6):432-5.
  24. Rohrich RJ, Raniere J, Ha RY. The alar contour graft: Correction and prevention of alar rim deformities in rhinoplasty. *Plast Reconstr Surg.* 2002;109(7):2495-505.
  25. Byrd HS, Meade RA, Gonyon DL. Using the autospreader flap in primary rhinoplasty. *Plast Reconstr Surg.* 2007;119(6):1897-902.
  26. Friedman M, Ibrahim H, Lee G, Joseph NJ. A simplified technique for airway correction at the nasal valve area. *Otolaryngol Head Neck Surg.* 2004;131(4):519-24.
  27. Paniello RC. Nasal valve suspension: An effective treatment for nasal valve collapse. *Arch Otolaryngol - Head Neck Surg.* 1996;112(12):1342-6.
  28. Akcam T, Friedman O, Cook TA. The effect on snoring of structural nasal valve dilatation with a butterfly graft. *Arch Otolaryngol - Head Neck Surg.* 2004;130(11):1313-8.
  29. Vaiman M, Shlamkovich N, Kessler A, Eviatar E, Segal S. Biofeedback training of nasal muscles using internal and external surface electromyography of the nose. *Am J Otolaryngol.* 2005;26(5):302-7.
  30. Toriumi DM, Josen J, Weinberger M, Tardy ME. Use of alar batten grafts for correction of nasal valve collapse. *Arch Otolaryngol Head Neck Surg.* 1997;123(8):802-8.
  31. Sen C, Iscen D. Use of the spring graft for prevention of midvault complications in rhinoplasty. *Plast Reconstr Surg.* 2007;119(1):332-6.
  32. Mendelsohn MS, Golchin K. Alar expansion and reinforcement: A new technique to manage nasal valve collapse. *Arch Facial Plast Surg.* 2006;8(5):293-9.
  33. Menger D. Lateral crus pull-up: a method for collapse of the external nasal valve. *Arch Facial Plast Surg.* 2006;8(5):333-337.
  34. Most SP. Analysis of outcomes after functional rhinoplasty using a disease-specific quality-of-life instrument. *Arch Facial Plast Surg.* 2006;8(5):306-9.
  35. Rhee JS, Poetker DM, Smith TL, Bustillo A, Burzynski M, Davis RE. Nasal Valve Surgery Improves Disease-Specific Quality of Life. *Laryngoscope.* 2005;115(3):437-40.
  36. Khosh MM, Jen A, Honrado C, Pearlman SJ. Nasal valve reconstruction: Experience in 53 consecutive patients. *Arch Facial Plast Surg.* 2004;6(3):167-71.
  37. Chambers KJ, Horstkotte KA, Shanley K, Lindsay RW. Evaluation of improvement in nasal obstruction following nasal valve correction in patients with a history of failed septoplasty. *JAMA Facial Plast Surg.* 2015;17(5):347-50.
  38. Rhee JS, Arganbright JM, McMullin BT, Hannley M. Evidence supporting functional rhinoplasty or nasal valve repair: A 25-year systematic review. *Otolaryngol Head Neck Surg.* 2008;139(1):10-20.
  39. Constantinides M, Galli SKD, Miller PJ. A simple and reliable method of patient evaluation in the surgical treatment of nasal obstruction. *Ear Nose Throat J.* 2002;81(10):734-7.
  40. Menger DJ, Swart KMA, Nolst Trenité GJ, Georgalas C, Grolman W. Surgery of the external nasal valve: The correlation between subjective and objective measurements. *Clin Otolaryngol.* 2014;39(3):150-5.
  41. Kalan A, Kenyon GS, Seemungal TA. Treatment of external nasal valve (alar rim) collapse with an alar strut. *J Laryngol Otol.* 2001;115(10):788-91.
  42. Hussein WK, Elwany S, Montaser M. Modified autospreader flap for nasal valve support: Utilizing the spring effect of the upper lateral cartilage. *Eur Arch Otorhinolaryngol.* 2015;272(2):497-504.
  43. Sheen JH. Spreader graft: A method of reconstructing the roof of the middle nasal vault following rhinoplasty. *Plast Reconstr Surg.* 1984;73(2):230-9.
  44. Antunes MB, Goldstein SA. Surgical approach to nasal valves and the midvault in patients with a crooked nose. *Facial Plast Surg.* 2011;27(5):422-36.
  45. Oneal RM, Berkowitz RL. Upper Lateral Cartilage Spreader Flaps in Rhinoplasty. *Aesthetic Surg J.* 1998;18(5):370-1.
  46. Yoo S, Most SP. Nasal airway preservation using the autospreader technique: Analysis of Outcomes Using a Disease-Specific Quality-of-Life Instrument. *Arch Facial Plast Surg.* 2011;13(4):231-3.
  47. Saedi B, Amaly A, Gharavis V, Yekta BG, Most SP. Spreader flaps do not

- change early functional outcomes in reduction rhinoplasty: A randomized control trial. *Am J Rhinol Allergy*. 2014;28(1):70-4.
48. Clark JM, Cook TA. The “butterfly” graft in functional secondary rhinoplasty. *Laryngoscope*. 2002;112(11):1917-25.
49. Alsarraf R, Murakami C. The saddle nose deformity. *Facial Plast Surg Clin North Am*. 1999;(7):303-310.
50. Schlosser RJ, Park SS. Surgery for the dysfunctional nasal valve. Cadaveric analysis and clinical outcomes. *Arch facial Plast Surg*. 1999;1(2):105-10.
51. Jalali MM. Comparison of effects of spreader grafts and flaring sutures on nasal airway resistance in rhinoplasty. *Eur Arch Otorhinolaryngol*. 2015;272(9):2299-303.
52. Eugene Tardy M, Garner ET. Inspiratory nasal obstruction secondary to alar and nasal valve collapse: Technique for repair using autogenous cartilage. *Oper Tech Otolaryngol Head Neck Surg*. 1990;1(3):215-7.
53. Boahene KD, Hilger PA. Alar rim grafting in rhinoplasty: Indications, technique, and outcomes. *Arch Facial Plast Surg*. 2009;11(5):285-9.
54. Guyuron B, Bigdeli Y, Sajjadian A. Dynamics of the alar rim graft. *Plast Reconstr Surg*. 2015;135(4):981-6.
55. Gassner HG, Maneschi P, Haubner F. The stairstep graft: An alternative technique in nasal valve surgery. *JAMA Facial Plast Surg*. 2014;16(6):440-3.
56. Craig J, Goyal P, Suryadevara A. Upper lateral strut graft: A technique to improve the internal nasal valve. *Am J Rhinol Allergy*. 2014;28(1):65-9.
57. Stolovitzky P, Sidle DM, Ow RA, Nachlas NE, Most SP. A Prospective Study for Treatment of Nasal Valve Collapse Due to Lateral Wall Insufficiency : Outcomes Using a Bioabsorbable Implant. *Laryngoscope*. 2018:1-7.