Annals of Plastic and Reconstructive Surgery

Research Article
Published: 16 Apr, 2020

# Extended Dorsal Preservation in a New Concept of Preservational Rhinoplasty

*António Sousa Vieir, Dunja Milicic*, Carlos Torrão Pinheiro, and Guilherme Carvalho*

*Department of Otorhinolaryngology, Hospital Lusiadas, SA Porto, Portugal*

## Abstract

**Background:** A dorsal preservation rhinoplasty concept was discussed and the benefits vs. contraindications and limitations were presented. In specific cases of severe nasal septal deformations associated with necessity of major septoplasty, focused on perpendicular plate, a New Concept of Extended Dorsal Preservation Rhinoplasty is presented (New Extended PR-D). PR-D is based on septoplasty, rhinosculpture and partial osteotomies.

**Goals:** The objective of this paper is to present a new approach in some cases of rhinoplasty named as extended dorsal preservation rhinoplasty.

**Methods and Results:** Partial and incomplete osteotomies were introduced as method to avoid disinsertion of nasal pyramid of glabellar area and to avoid bony step in areas off osteotomy cut. Rhinosculpture in its extended mode was promoted for modulation of bony structure with obtaining immediate aesthetic and structural results, minoring a surgical trauma.

**Conclusion:** The principles of Preservation Concept were respected in this New Extended PR-D Concept.

**Keywords: Preservation Rhinoplasty; Partial Osteotomies; Rhinosculpture; Dorsal preservation rhinoplasty**

## Introduction

Rhinoplasty is more than a surgery, it is not just a change of the shape of a nose, can be consider as a philosophy, a duty and a responsibility. Duty and responsibility to the patient, which aims to transform and shape.

Aesthetics is disputable. Aesthetic patterns are variable depending of the cultural, social and economic status. It is essential to listen, to understand what a specific person wants and try to approximate the final surgical result to their desires according to our individual surgical skills.

It is not just desirable it only to change features of a nose; but above all, interfere with patient's body image and self-esteem. Their life takes a turn over, sometimes accepted with delight and gratitude and sometimes more or less badly faced.

Surgical cutting should not be just the main factor, it is again and above the all the responsibility of this procedure and medical approach. It is desirable to preserve as much as surgeon can, structures and function, preserving and protecting patient's individuality and respecting his personality.

The uttermost important responsibility for the surgeon, as one more duty and another obligation, is professionalism. The professionalism includes the intellectual capability, the skillfulness and the knowledge.

The process of acquiring knowledge is never ending line, is a sinusoidal curve, with ups and downs, quoting Finocchi [1]. It has to be faced with a humble attitude and seriousness, understanding that every "bottom" of the curve is actually a possibility to grow, to learn and to get closer to perfection, instead a personal defeat.

The beauty must be the simplicity. It is important to admitted differences in concept and definition of beauty, but on the end of the line the patterns stay simple, even though adapted to anthropological concepts. The beauty is a respect, for structures and function.

As well as the beauty, the process of restoring and/or achieving it has to be kept simple. The transformation has to be done with minimal possible changes, reaching as much possible pleas able

**OPEN ACCESS**

***Correspondence:***
*Dunja Milicic, Department of Otorhinolaryngology, Hospital Lusíadas, SA Porto, Boavista Avenue 171, 4050-115 Porto, Portugal,*
*E-mail: guilherme.machado.carvalho@lusiadas.pt*

**Received Date**: *23 Mar 2020*
**Accepted Date***: 14 Mar 2020*
**Published Date***: 16 Apr 2020*

***Citation:***
*Vieir AS, Milicic D, Pinheiro CT, Carvalho G. Extended Dorsal Preservation in a New Concept of Preservational Rhinoplasty. Ann Plast Reconstr Surg. 2020; 4(2): 1055.*

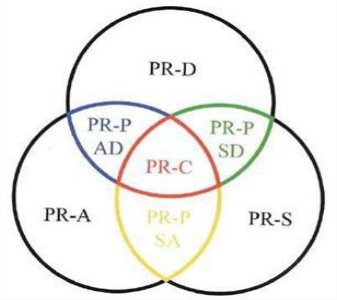


**Figure 1:** Definition of PR-C concept in Rhinoplasty by Rollin K Daniel [3].

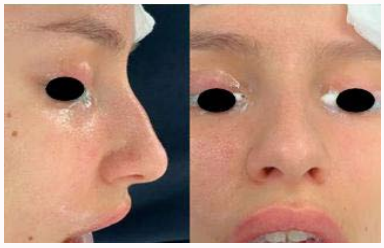

**Figure 2:** Tension nose example, best indication for PR-D (profile and frontal view).

**Figure 3:** Patient pre and immediate pos-op result by Extended PR-D (open Approach, profile view).

aesthetic and functional results [2].

The emerging and overwhelming concept of surgical preservation is related to structure, to anatomy and consecutively to the function, and is well defined in concept of Preservation Rhinoplasty (PR) [2].

By another definition, it could be divided in some different ways that are shown in Figure 1. The first is the PR-S, which can be defined by elevation of the Skin Tissue Envelope (STE). The second is the PR-D, which can be defined by the preservation of osseocartilaginous vault of the nasal dorsum. The third one is the PR-A, which can be defined by a minimal or no alar resection, sutures for reshaping the tip area [3]. All those preservation rhinoplasty types could be overlapping, combining different types of surgical preservation, unifying itself in complete Preservation Rhinoplasty (PR-C) [3].

The best indications for PR-D are very well defined in the medical literature [2,3]. PR-D is suitable to corrections a dorsal nasal pathology with classical nasal situations, as listed ahead [4]. Those situations are a straight nose with or without moderate hump (rhinion and kyphion); a short nasal bone with weak upper lateral cartilages; and a tension nose with compromised internal nasal valve shown in Figure 2.

Otherwise, the PR-D has some limitations, such as follows a big hump; or some irregularities on nasion, rinion and big kyphion of nasal pyramid; or a long nasal bones and/or thick nasal bones [3].

In a nasal surgery, the surgeon can reach very important difficulties in some special structural issues that make PR-D not a good approach, as severe or complex septal deviations; surgical indication to removal of the perpendicular plate of ethmoid bone [3]. This aspects needs to be highlighted.

Aesthetic and structural disadvantages frequent in this PR-D concept are infantilization of the profile aspect (possible incompatibility in some anthropological/ethnic groups); and the presence of the bones "step" in central nasion area after transverse osteotomies, performed at pushdown and letdown techniques [2,3].

Due to those mentioned limitations, problems and disadvantages were faced with difficulties in executing surgeries with complex pathology by principles of classical dorsal preservation rhinoplasty.

To be able to solve these issues, we decided to enlarge and modify the concept of PR-D by introducing an Extended Dorsal Preservation Rhinoplasty Concept (Extended PR-D Concept). This new concept consists of perform a classical Cottle Septoplasty, followed by rhinosculpture and finished with partial lateral osteotomies.

The goal of this paper is to present the Extended Dorsal Preservation Rhinoplasty Concept (Extended PR-D Concept).

## Results and Methods

The Extended Dorsal Preservation Rhinoplasty Concept (Extended PR-D Concept) was performed in 37 patients. Patients had nasal pyramid deformity such as slight dorsal deviation, big hump, long nasal bone with thick ones, asymmetry and irregularities on dorsal osseocartilaginous pyramid and broad nasal "bridge", isolated or combined.

To complete, all the patients had significant structural internal nasal deformity documented by nasal tomography (CT) scan and rhinodebitomanometry. Trauma etiology was found in only 2 patients and development deformation in the others 35 patients. All procedures were performed after informed written consent.

A New Extended PR-D Concept is performed only by open approach, most because the rhinosculpture needs a great surgical nasal bones exposure, both to have a good visualization of the surgical field and for place the surgical instruments used in this surgical step. The ultrasonic piezo-electric instrument was Piezotome M+ by COMEG® used in all patients, for osteotomies and for rhinosculpture.

Always started with a classical Cottle Septoplasty for a complete resolution of any structural and functional problem. Depending on the necessity of each patient, the resection of quadrangular cartilage and/or perpendicular plate of ethmoid bone was done, in smaller or wider extent way. The classical L strut of cartilage was always preserved. In some case reimplantation of the tissue, straight cartilage and bone, was performed as much as possible.

The rhinosculpture was performed by rasping the bony hump and/or irregularities on dorsal and lateral surface of nasal bones by piezo scrapping tip, also with hard and fine rasps (RHS1, RHS2HB and RHS2FB). This must be delicated, and consernig for not disturbing the K-stone area, even in patients with prominent hump following principles of preservation attitude [4, 5]. This example can be shown at Figure 3.

A "LOW-to-LOW" osteotomies was performed by piezo scrapping tip (RHS1), as shown in Figure 4. The oblique cut, of the bony surface, started on the border of the piriform aperture [4,5]. When reached

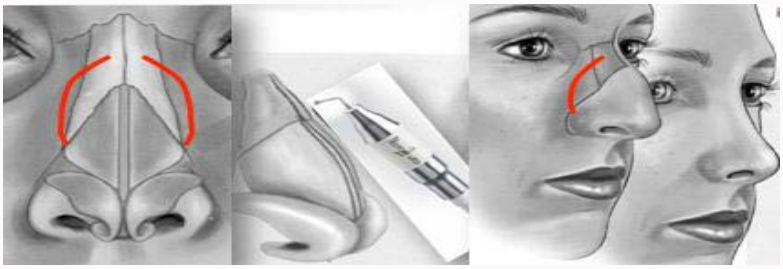

**Figure 4:** "*LOW-to-LOW*" osteotomies example performed by piezo scrapping tip (RHS1). Modificated from: Patient Information Series: Rhinoplasty, Visuluma Scientific Visualization, EAFPS 2019.

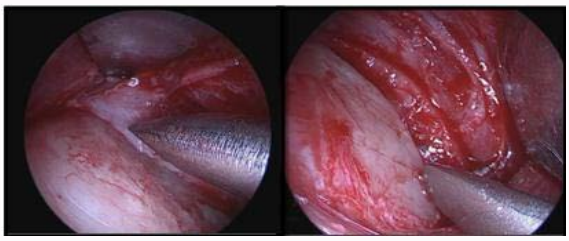

**Figure 5**: Partial Lateral osteotomy done with *Ultrasonic Piezotome* (endoscopic image, patient's left side). Right image show the bone *dorsum* and *glabella* area and note that the surgical instrument point to an incomplete osteotomy. Left image show the basal part of the osteotomy, close to the pyramid area. Note that the internal *periosteum* is preserved.


**Figure 6:** Different types of pyramid deformities (kyphosis) with the indication of which surgical concept is applicable in solving it (Classical concept *vs.* Extended PR-D).

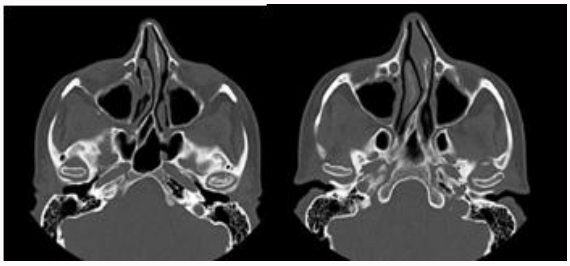

**Figure 7:** Axial nasal CT scan with severe septal deformity.

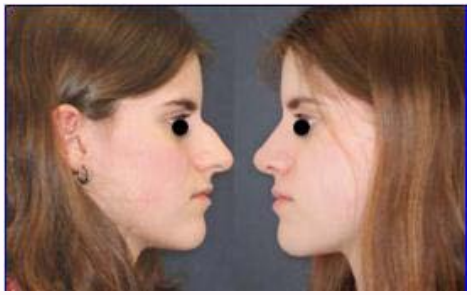

**Figure 8:** Pre and 1 year post-op result by Extended PR-D (open Approach, profile view).

the area of medial eye canthus area, 2 mm lower of it, the orientation needs to turn upwards in the direction of the maxillary-nasal suture that surpasses for 2 mm to 3 mm. The cut/osteotomies should end between 2 mm to 4 mm in front of the junction of the nasal bones (sutura internasalis) on the midline, and it is important to adapt to each patient´s anatomy [6]. This can be exampled in Figure 4 and 5.

Sometimes, it is necessary an intermediary osteotomies, that were performed in the cases of slight crooked nose on previous fracture line, up to 3 mm to 4 mm laterally of sutura internasalis, cranially of K-stone area [4,6]. It is important to highlight that there was no secondary deviation of the bone fragments in the follow up of 1-2 years in all patient.

## Discussion

Nasal pyramid deformities implicate different clinical situations and solving as shown in Figure 6 [7,8]. A nasal pyramid deformity, deviated and/or irregular, can be checked as a simple and "superficial" observation in physical examination and maybe the surgical planning can look relatively easy. However, in some cases, a surgical planning is not so linear.

The boundaries between those patients are actually a severe septal deviation presented on CT scan, similar to shown in Figure 7. This kind of septal deformity does not allow the classical removal of a strip of high septal cartilage and perpendicular plate [2]. So, a structural inner nasal deformity is a "challenging" surgical issue [9].

In these situations, a severe nasal septal deviation is present with the functional necessity to remove the perpendicular plate of ethmoid bone in order to establish normal respiratory function. So, it is important to highlight that in a nasal surgery, the surgeon can reach very important difficulties in some special structural issues that make PR-D not a good approach, as severe or complex septal deviations; Necessity to remove the perpendicular plate of ethmoid bone [3].

There is a tendency of superficial approach underestimating the "septal" surgical relevance. The tendency is to consider it as minor surgical procedure, with no importance and easy to perform, especially by young trainees. There is no preoccupation with the structure, airflow, and pressure or air resistance. This attitude is maybe one of the principal iatrogenic causes of nasal pyramid deformity.

Frequently forgotten, the fact is that structural deformities of interior of the nose, cartilaginous and osseous, as in any other

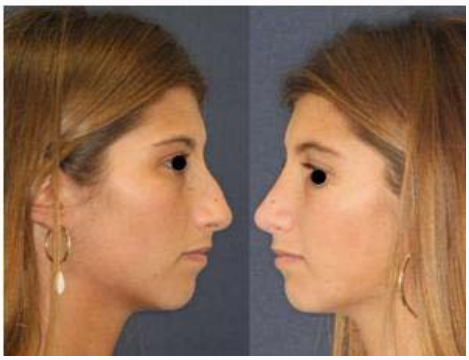

**Figure 9:** Pre and 1 year post-op result by Extended PR-D (open Approach, profile view).

**Figure 10:** Pre and 1 year post-op result by Extended PR-D (open Approach, profile view).

constructional and mechanical system, define the outer and external deformities and it is very important and obligatory to be corrected. These types of patients have the best and correct indication the New Extended concept of PR-D.

In the new concept of Extended PR-D, a structural correction of the inner nasal deformities, which includes major septoplasty with removal of perpendicular plate, and reestablishing a normal function of the nose, is a mandatory surgical goal. This functional correction attitude gives us the important aesthetic contributes, needing just a slight plastic retouch to achieve an almost perfect aesthetic.

Classical PR-D concept resolves minor deformities with otherwise balanced nose [2,3,4]. It needs the exact excision of infra dorsal septal (Vitruvian maneuver, Tetris concept) combined with lateral and transverse osteotomies, to obtain a perfect profile, with minimal surgical trauma and preservation of K-area [10]. This technique, by letdown and pushdown techniques, is separating the nasal pyramid of its insertion of maxillofacial skeleton on behalf of preserving the K-area [4,6,10].

In any procedures of straightening of the width of a nasal pyramid or repositioning of the deviated nose in the midline, osteotomies are conventionally used [9-18]. Changes introduced lately in osteotomy technique, improved dramatically postoperative results. In other words, a "perforating" line effect of 2 mm to 3 mm osteotomes which preserve periosteal connections and reduce the soft tissue damage in external percutaneous osteotomies [19-21].

With the new technology Ultrasonic Piezo-electric cut instruments, the surgical trauma was practically resolved and the

**Figure 11:** Pre and 15 months post-op result by Extended PR-D (open Approach, profile and frontal view).

precision was obtained, especially when done by open approach, with direct vision, as well as augmented security avoiding undesirable prolongations of the fracture line and the preservation of the inner periosteum [17-29].

The "bone step" as result of the any type of osteotomy (even with piezo-electric tools) is inevitable, except in some maneuvers as in described in the "slide down" manouver [5, 25].

In our experience, deformities initiate caudally of intercanthal line, which is in average 7 mm to 10 mm below of the sutura nasofrontalis [30]. It is a perfect place to locate a transverse osteotomy or 1 mm to 2 mm below [31].

The presumption of the concept of Classical Preservation Rhinoplasty is to have a strait septum or minor septal deformity easy to correct and it is essential to support disinserted structure, a "floating" nasal pyramid [3].

To prevent undesirable mobilization, it is required a cranial fixation of disinserted ("loose") pyramid or harmonization with camouflage procedure like free- diced cartilage [29,30]. This is not an easy and clear procedure as in Gubisch technique, due to a height, high localization, of the form and the cut itself [9,29,30].

In the case of severe structural deformity of nasal septum in its cartilaginous and/or bony part (quadrangular cartilage, vomer and perpendicular plate of ethmoid bone) it is practically impossible to maintain this concept.

From another point of view, a possible solution in this type of pathology, which needs structural support like in major septal deformities, but respecting the principles of preservation rhinoplasty, is the new concept of extended dorsal preservation rhinoplasty (Figures 7-11).

The most evident deformations of the nasal bone pyramid are located on the caudal border of the nasal bones (margo inferior ossi nasalis and rhinion) which denotes the K-stone area needing for its correction with rhinosculpture, plus lateral and intermediate osteotomies [4,6,32].

The damage of the K-stone area is avoided by using the rhino sculpture concept. The use of the scrapping tool from ultrasonic piezotome allows to reshape the dorsum and maxilla. The uncapping of the bone over the upper lateral cartilages is necessary; preserving always the dorsal integrity and this step is very important and happens in a lot of cases.

Minor osseous deformities and irregularities can also be restored by this method without a need to separate and/or break the nasal bones or the processus frontalis. Ultrasonic-piezo electric equipment permitted to shape and reshapes the bony part without the need to disrupt the osseocartilaginous connection of the K-Area and maintaining the upper lateral cartilage undamaged. The minor bony or even moderate bony humps were easily removed [22-25].

Afterwards, as described, a "LOW-to-LOW" osteotomies were performed after scrapping the maxillary bone, starting from perform aperture and without junction in the midline. In our patients, a forming of "floating" pyramid was prevented by the preserving a fragment of the nasal bones in millimeter distance (3 mm to 4 mm) of the sutura internasalis bilaterally.

With this bone preservation, osteotomies (intermediate as well as lateral) turned to be incomplete (partial). This tiny bone connection was sufficient to support the nasal pyramid. Maintaining the connection with glabellar region (sutura frontonasalis) additional support was reached, providing even more stability with no need for fixation of suspended fragments [29,30,32,33]. This fact made possible performing one and/or two more intermediate osteotomies on secure approach.

By the principle of "pressure spring", the spontaneous positioning of deviated/fractured fragment can be reached into the correct position. Commonly complete osteotomy leads to "sinking" of the free fragment and over correction, needing doubtful repositioning measures and/or camouflage techniques.

In this new surgical concept of partial osteotomies, the elasticity of the tissue corrects the defect appropriately, on the right measure and on right location. Without the use of force it just "sits" in right position, and still maintains secured by midline junction. Also, the bony "step" in nasion area was avoided, especially with obliquely oriented piezo-electric cut [32-34]. It has been decreased even mores a "step" by previous piezo-electric scrapping of the maxillary bone, on the locations where the osteotomy should be performed.

In actual state of our surgical progress, based on two years follow-up period, some points in our attitudes towards Preservation Rhinoplasty were very well clarified as bellow.

1. Classical PR-D concept should be selected to patients with strait or slight deviated dorsum, with small bony hump, short nasal bones and presence of structural septal support (straight or slightly deviated/deformed nasal septum).

2. With an open surgical approach rhinoplasty assisted by piezo-electric instruments.

3. The preservation of upper lateral cartilages (especially Key-area) is obligatory in every primary and possibly in revision cases due to use piezo-electric instruments.

Due to impossibility and limitation of the Classical Preservation Rhinoplasty Concept in some specific cases, we try to perform the new Extended PR-D Concept. It is destinated to severe nasal septal deviations/deformations and functional necessity to remove or vastly resect perpendicular plate of ethmoid bone. Partial and incomplete osteotomies are necessary to achieve good results. Also, it is necessary to perform a carefully rhinosculpture.

In the "jungle" and the "noise" of information all around rhinoplasty surgery, the correct pathway of acquiring the knowledge is a difficult task. Without the correct and expert senior orientation it is even harder.

Sometimes we are driven to "misty" areas, "wondering", "lost" in concepts, techniques and skills. Confusions and contradictions leave us undecided and susceptible to make mistakes. But, the capability to hear, to see, to elect, to select, to doubt, to prove, to double check can leads us to correct direction.

On the end, we can define our choice, define our strategy and finally name our concept. It worked for our patients and us. The objective was fulfilled and utmost concept of medicine was respected: "Primum nil nocere" by Ἱπποκράτης ὁ Κῷος (Hippocrates of Kos) (460AC-377AC).

## Conclusion

The benefits *vs.* contraindications and limitations in dorsal preservation rhinoplasty concept were presented. In severe nasal septal deformations associated with necessity of major septoplasty associated to pyramid deformity a New Concept of Extended Dorsal Preservation Rhinoplasty is presented (New Extended PR-D).

The New Extended PR-D Concept is indicated in case of pyramid deformity as more large (not only minor) humps, long and thick nasal bones, wide nasal bridge, slight asymmetries and bony deviations.

The New Extended PR-D is based on septoplasty, rhinosculpture and partial and incomplete osteotomies.

## Acknowledgment

We would like to thank all our staff of Hospital Lusíadas Porto, on the help provided in all our ENT and medical work.

## References

1. Finocchi V. The Learning Curve of Preservation Rhinoplsty. In: Saban Y, Çakir B, Daniel R, Palhazi P, editors. Preservation Rhinoplasty. Bio Ofset. 2018;139-55.
2. Saban Y. Preservation Septoplasty & Rhinoplasty in deviated Nose. In: Saban Y, Çakir B, Daniel R, Palhazi P, editors. Preservation Rhinoplasty. Bio Ofset. 2018;295-315.
3. Rollin DK. Preservation Rhinoplasty: Rational & Overview. In: Saban Y, Çakir B, Daniel R, Palhazi P, editors. Preservation Rhinoplasty. Bio Ofset. 2018;18-29.
4. Palhazi PD. Essential Operative Anatomy for Preservation Rhinoplasty. In: Saban Y, Çakir B, Daniel R, Palhazi P, editors. Preservation Rhinoplasty, Bio Ofset. 2018;45-73.
5. Saban Y. Step by Step Closed Rhinoplasty with Dorsum preservation. In: Saban Y, Çakir B, Daniel R, Palhazi P, editors. Preservation Rhinoplasty, Bio Ofset. 2018.251-67.
6. Krmpotic-Nemanic JDW, Helms J. Chirurgische Anatomie des Kopf-Hals-Bereiches. Springer-Verlag Berlin Heidelberg. 2013.
7. Robotti E, Heppt WJ. New tools and proven techniques in rhinoplasty. Facial Plast Surg. 2019;35(1):1-2.
8. Robotti E, Penna WB. Current practical concepts for using rib in secondary rhinoplasty. Facial Plast Surg. 2019;35(1):31-46.

9. Gubisch W. The extracorporeal septum plasty: A technique to correct difficult nasal deformities. Plast Reconstr Surg. 1995;95(4):672-82.
10. Neves JC, Arancibia Tagle D, Dewes W, Wayne Larrabee Jr. The split preservation rhinoplasty: "The Vitruvian Man split maneuver". Eur J Plast Surg. 2020.
11. Trenité GJN. Rhinoplasty: A Practical guide to functional and aesthetic surgery of the nose; [book without Interactive DVD]. Kugler Publications. 2005.
12. Kim DW, Toriumi DM. Management of posttraumatic nasal deformities: The crooked nose and the saddle nose. Facial Plast Surg Clin North Am. 2004;12(1):111-32.
13. Rohrich RJ, Ahmad J. Rhinoplasty. Plast and reconstruc surg. 2011;128(2):49e-73e.
14. Tardy ME, Denneny JC. Micro-osteotomies in rhinoplasty-a technical refinement. Facial Plastic Surgery. 1984;1(2):137-45.
15. Thomas JR, Griner NR, Remmler DJ. Steps for a safer method of osteotomies in rhinoplasty. Laryngoscope. 1987;97(6):746-7.
16. Goldfarb M. Gallups JM, Gerwin JM. Perforating osteotomies in Rhinoplasty. Arch Otolaryngol Head Neck Surg. 1993;119(6):624-27.
17. Padovan I. External approach in rhinoplasty (decortication). Can J Otolaryngol. 1966;3:354-60.
18. Padovan I, Jugo SB. The complications of external rhinoplasty. Ear Nose Throat J. 1991;70(7):454-6.
19. Bull TR. Percutaneous osteotomy in rhinoplasty. Plast and reconstr surg. 2001;107(6):1624-5.
20. Rohrich RJ, Krueger JK, Adams WP Jr, Hollier LH Jr. Achieving consistency in the lateral nasal osteotomy during rhinoplasty: An external perforated technique. Plast Reconstr Surg. 2001;108(7):2122-30; discussion 2131-2.
21. Tirelli G, Tofanelli M, Bullo F, Bianchi M, Robiony M. External osteotomy in rhinoplasty: Piezosurgery *vs.* osteotome. Am J Otolaryngol. 2015;36(5):666-71.
22. Robiony M, Polini F, Costa F, Toro C, Politi M. Ultrasound piezoelectric vibrations to perform osteotomies in rhinoplasty. J Oral Maxillofac Surg. 2007;65(5):1035-8.
23. Robiony M, Toro C, Costa F, Sembronio S, Polini F, Politi M. Piezosurgery: A new method for osteotomies in rhinoplasty. J Craniofac Surg. 2007;18(5):1098-100.
24. Ghassemi A, Prescher A, Talebzadeh M, Hölzle F, Modabber A. Osteotomy of the nasal wall using a newly designed piezo scalpel-a cadaver study. J Oral Maxillofac Surg. 2013;71(12):2155. e1-2155. e6.
25. Gerbault O, Rollin DK, Kossins AM. The role of piezoelectric instrumentation in rhinoplasty surgery. Aesthet Surg J. 2016;36(1):21-34.
26. Albers A, Wähmann M, Riedel F, Kovacevic M, Hopf A. Piezoelectric and conventional osteotomy in rhinoplasty–a systematic comparison. Laryngo-Rhino-Otol. 2019;98(S 02):S167.
27. Smith TW. Osteotomy and infraction in rhinoplasty. Arch Otolaryngol. 1974;100(4):266-8.
28. Marshall DR, Slattery, PG. Intracranial complications of rhinoplasty. British J Plastic Surg. 1983;36(3):342-44.
29. Kovacevic M. Refinements in Dorsal Preservation. In: Saban Y, Çakir B, Daniel R, Palhazi P, editors. Preservation Rhinoplasty, Bio Ofset. 2018;355-63.
30. Gruber RP, Stepnick D. Rhinoplasty: Current concepts, an issue of clinics in plastic surgery-e-book. Elsevier Health Sciences. 1st ed. 2010;27(2).
31. Goksel A. Piezo-Assisted Let Down Rhinoplasty. In: Saban Y, Çakir B, Daniel R, Palhazi P, editors. Preservation Rhinoplasty, Bio Ofset. 2018;327-53.
32. Zholtikov V, Golovatinsky V, Palhazi P, Gerbault O, Rollin KD. Rhinosculpture rhinoplasty: A sequential approach to managing the bony vault. Aesthet Surg J. 2019.
33. Saban Y. Dorsal Preservation by Sub-Dorsal Septal Ressection & Push/Let Down. In: Saban Y, Çakir B, Daniel R, Palhazi P, editors. Preservation Rhinoplasty, Bio Ofset. 2018;269-93.
34. Konsins A. My first 50 Dorsal Preservation Rhinoplasty. In: Saban Y, Çakir B, Daniel R, Palhazi P, editors. Preservation Rhinoplasty, Bio Ofset. 2018.127-37.