



Complex Costal Arch Reconstruction with Biosynthetic Materials after Tumor Resection

Daniel L Miller^{1*} and Fredrick L Durden²

¹Department of Surgery, Section of Thoracic Surgery, Medical College of Georgia, Georgia

²Department of Surgery, Section of Plastic Surgery, Cancer Treatment Centers of America, Atlanta-CTCA, Georgia

Abstract

Reconstruction of the lower chest wall and costal arch after tumor resection can be a challenge. The perfect material does not exist to restore chest wall stability and normal chest wall mechanics. We describe a case of chest wall resection of a massive chondrosarcoma involving ribs 8 to 10, costal arch and portion of the diaphragm. Chest Wall Reconstruction (CWR) was performed with a combination of Biosynthetic Materials (BSM) composed of ovine-derived extracellular matrix/monofilament polypropylene patch and absorbable Polylactic Acid (PLA) bars.

Introduction

Biosynthetic Materials (BSM) incorporate both biologic and synthetic components, which have been shown to be effective in reconstruction of abdominal clean contaminated and contaminated wounds [1,2]. The principal goal of the combination material is to establish a scaffold for tissue in growth in addition to maintaining integrity with a permanent synthetic support. This case report describes our initial experience with a new BSM for CWR that is composed of ovine-derived extracellular matrix/monofilament polypropylene suture in combination with PLA bars.

Case Presentation

58-year-old woman noticed an asymptomatic mass on left lower rib in 2010; patient had no history of trauma or cancer. CT scan showed a mass in the 9th rib (Figure 1). She elected no treatment at that time. The mass grew over two years. A CT scan of the chest and upper abdomen showed enlargement of the mass with no signs of metastasis (Figure 1); needle biopsy revealed a low-grade chondrosarcoma. She elected not to proceed with recommended surgical resection. The patient returned 8 years later with a massive lower chest wall mass (Figure 1), complaining of pain and dyspnea on exertion. Work-up showed no signs of metastatic disease except a new calcified nodule (8 mm) in the Left Lower Lobe (LLL) of her lung (Figure 1). The mass was involving ribs 8-10 and the costal arch of the left lower chest (Figure 1). Patient underwent complete resection of the mass (22.5 cm × 16 cm × 11 cm) en bloc with ribs 8 to 10 (Figure 2), costal arch of the left lower chest, and portion of diaphragm as well as wedge excision of the LLL nodule. Tumor was a well differentiated chondrosarcoma with all margins >2 cm. The LLL nodule was a calcified granuloma. Reconstruction was completed with a scaffolding of absorbable PLA bars (10) and an ovine rumen matrix patch. The PLA bars were secured to ribs (Figure 2), intercostal muscles, and residual diaphragm first for chest wall stability and then the ovine patch over the PLA bars for added stability and reestablishing integrity of the chest (Figure 2). The chest cavity was drained with a 28 Fr chest tube and 10 Fr Jackson Pratt drains over the patch site. Patient refused muscle interposition coverage. Analgesia was provided by a thoracic cavity field block with diluted bupivacaine liposome (20 cc) (Exparel - Pacira Pharmaceuticals, Inc - Parsippany, NJ) as an injectable suspension with 0.25% Marcaine without epinephrine (60 cc) and injectable saline (220 cc) for a total volume of 300 cc and a multimodality pain regiment of scheduled intravenous muscle relaxants and anti-inflammatory drugs and as needed low dose oral narcotics. The patient was discharged on POD 5 with JPs in place. The patient underwent reoperation for incisional dehiscence 6 weeks after CWR with advancement of an inferior latissimus flap and primary closure without sequela; the BSM and PLA bars were intact and not removed. At 12 months follow-up, the patient had no paradoxical motion, chest wall instability or loss of abdominal integrity and no signs of recurrence or metastasis (Figure 3). Preoperative pictures of the tumor and a postoperative incisional picture are shown (Figure 4).

OPEN ACCESS

*Correspondence:

Daniel L Miller, Department of Surgery,
Section of Thoracic Surgery, Medical
College of Georgia, 551 Gramercy Dr
NE, Marietta, 30068, Georgia,
E-mail: dlmillermd@icloud.com

Received Date: 23 Nov 2021

Accepted Date: 14 Dec 2021

Published Date: 23 Dec 2021

Citation:

Miller DL, Durden FL. Complex Costal
Arch Reconstruction with Biosynthetic
Materials after Tumor Resection. *Ann
Plast Reconstr Surg.* 2021; 5(3): 1083.

Copyright © 2021 Daniel L Miller. This
is an open access article distributed
under the Creative Commons Attribution
License, which permits unrestricted
use, distribution, and reproduction in
any medium, provided the original work
is properly cited.

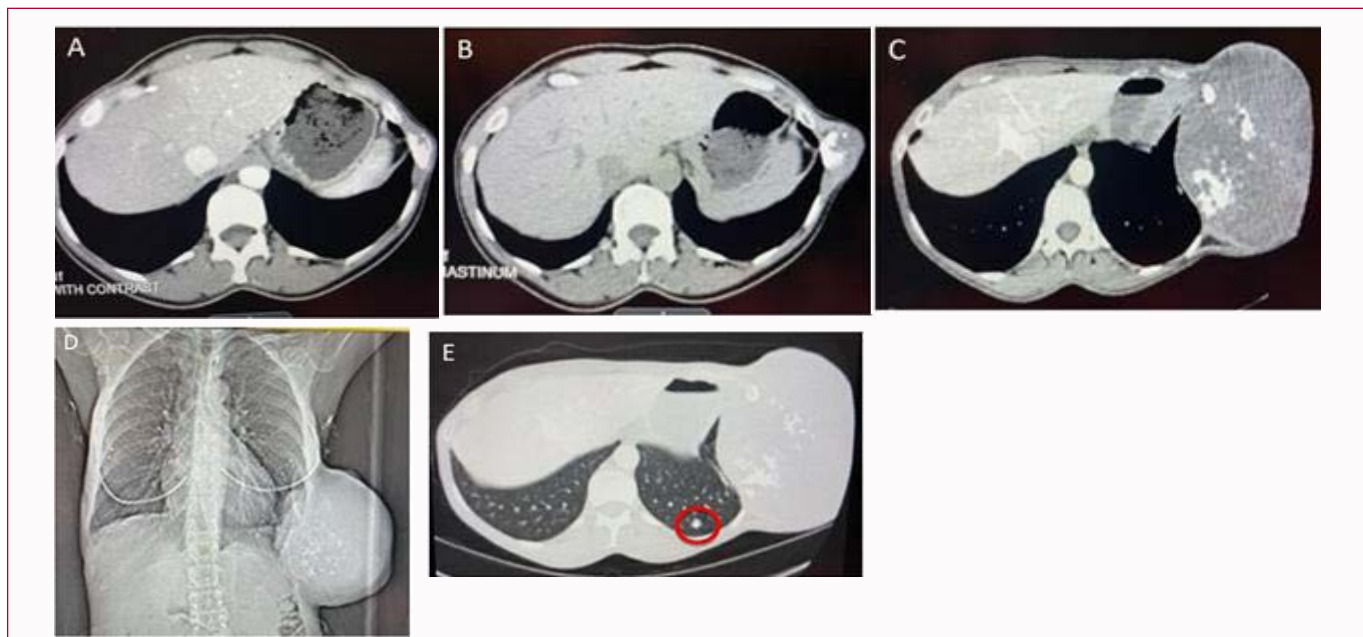


Figure 1: CT scans of enlarging chest wall mass. (A-D) CT scans of chest over 10 years showing enlargement of the left lower chest wall mass arising from the 9th rib initially. (E) Development of an indeterminate pulmonary nodule (red circle) within the left lower lobe.

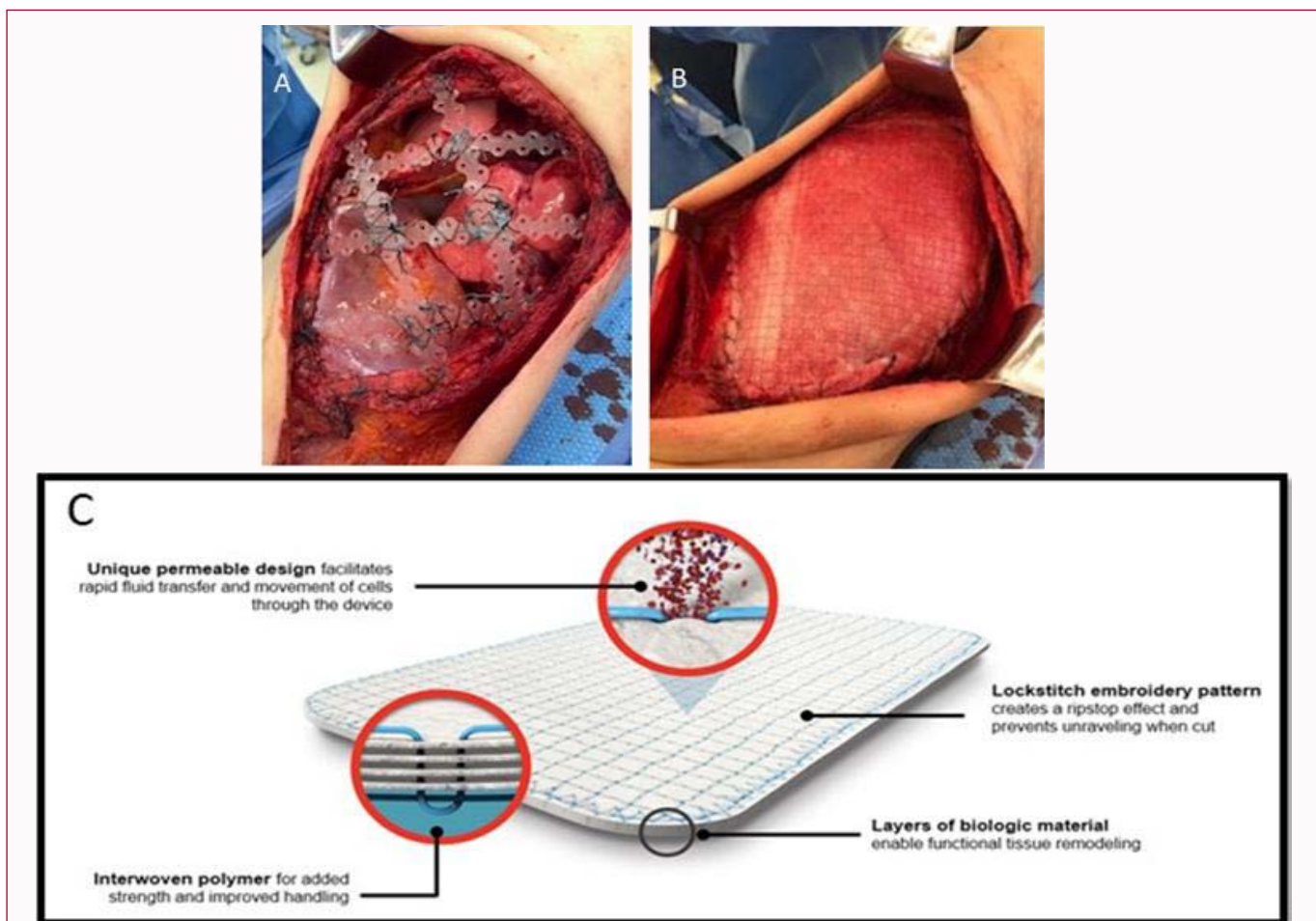


Figure 2: Chest wall reconstruction with biosynthetic materials. (A) PLA (BioBridge®) bars sutured to ribs and diaphragm. (B) Placement of large BSM (Ovitex®) patch for CWR. (C) Ovine extracellular matrix/monofilament polypropylene patch containing four layers of ovine rumen embroidered together into a single layered patch.

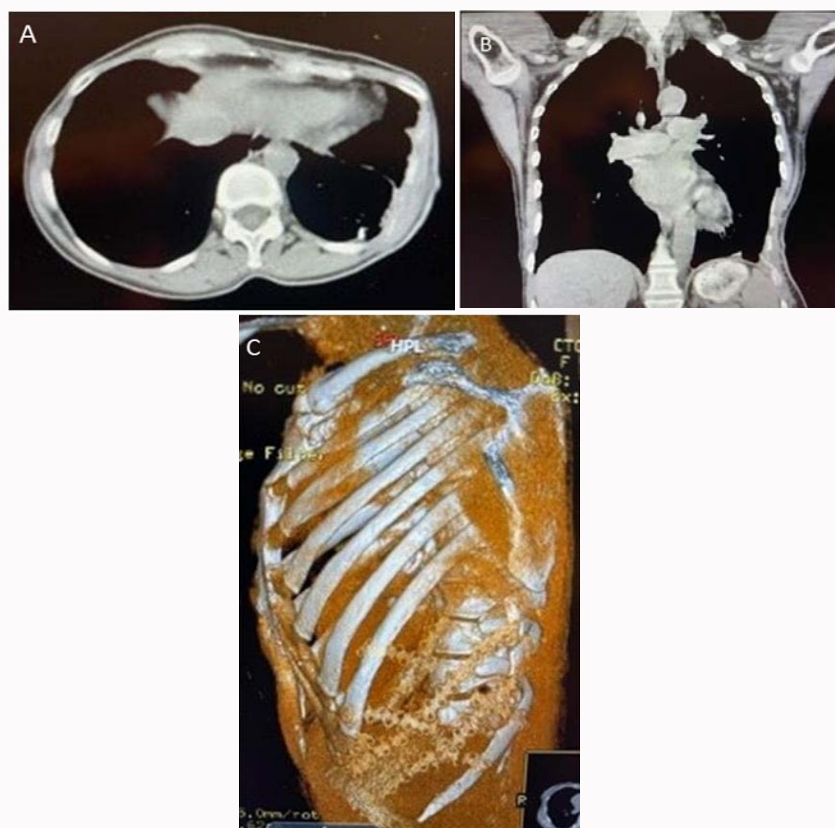


Figure 3: CT scans at 12 months follow-up.

12-month follow-up CT scans of chest showing no recurrence with near-normal reconfiguration of left lower chest wall and costal arch. (A) Axial section CT scan of the chest showing near normal chest configuration. (B) Coronal section CT scan of chest showing reconstruction of the lower chest wall and costal arch. (C) 3-D reconstruction CT scan of chest showing the PLA bars in place.

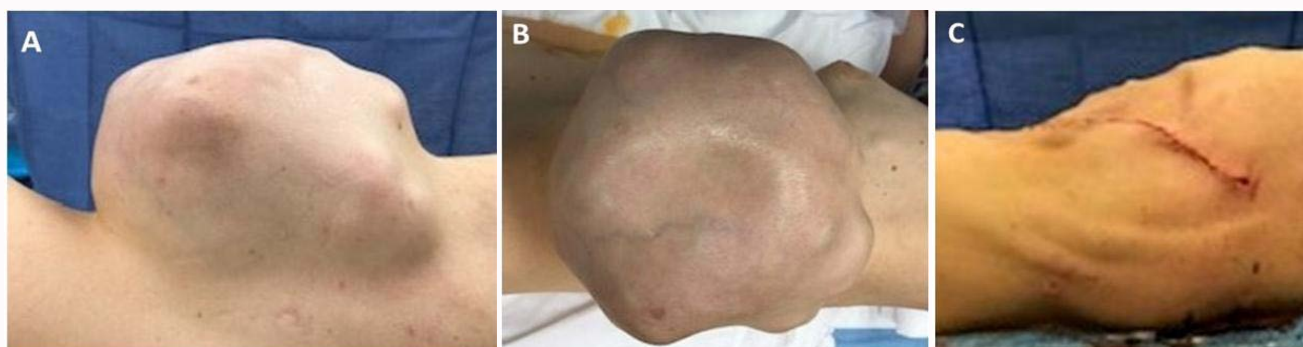


Figure 4: Preoperative and postoperative chest wall pictures.

Pictures of the tumor (A, B) preoperatively and (C) postoperative incision.

Discussion

Chest Wall Reconstruction (CWR) can be a challenge because the ideal reconstruction material does not exist. Universal criteria for material selection include, but are not limited to non-carcinogenicity, chemical inertness, resistance to mechanical stress, sterility, unresponsiveness to body and tissue fluids, limitation of foreign-body reactions, modifiable in size, and non-allergenic [3]. Understanding patient comorbidities, potential for infection, and how the material will incorporate at a cellular level will increase success, avoid surgical morbidity, and improve long-term outcomes [4].

The CWR material was a BSM patch (Ovitex[®] reinforced tissue

matrix; TELA Bio, Inc, Malvern, PA), made of four-layers of ovine rumen mucosa incorporated into a single layer with interwoven and embroidered polymer fibers (polypropylene); the patch was secured under tension with running and interrupted polypropylene sutures over the PLA bars (BioBridge[®]; Acumed, Inc -Hillsboro, OR) that were secured together with 0 silk ties and #1 non-absorbable polyester sutures to create extended doublets to bridge the defect. The PLA bars were secured to the ribs, intercostal muscles, and residual diaphragm with #1 non-absorbable polyester suture under tension to prevent loss of lower chest and abdominal domain. The BSM patch established a scaffold for tissue in growth in addition to maintaining integrity with a permanent synthetic support. This configuration is

designed to stimulate fibroblast migration in addition to cell signaling cascades, leading to neovascularization and deposition of collagen [5]. The biologic material from the ovine rumen reduces foreign body response, enable functional tissue remodeling and promote a natural repair. The interwoven and embroidered polymer fibers provide permanent reinforcement, along with improved handling and load-sharing capability.

With the introduction of biomaterials for reconstruction, the possibility of contamination of the patch is less likely as shown in the abdominal literature [5]. In an earlier series by Miller et al. [6], use of a non-crossed-linked bovine pericardium and absorbable PLA bars proved to be satisfactory; especially in infected cases. The principal goal of a combination material is to establish a scaffold for tissue in growth in addition to maintaining integrity with a permanent synthetic support. This configuration is designed to stimulate fibroblast migration in addition to cell signaling cascades, leading to neovascularization and deposition of collagen [7]. This case describes the first use of a new biosynthetic material for CWR that is composed of ovine-derived extracellular matrix and monofilament polypropylene sutures. The biologic material from ovine rumen reduces foreign body response, enable functional tissue remodeling and promote a natural repair. The interwoven polymer fibers provide permanent reinforcement, along with improved handling and load-sharing capability to support normal CW mechanics. BSM was first introduced for inguinal hernia repair, but the material has been employed in all soft tissue areas of the body for reconstruction support and repair [8]. Since this case we have performed 29 other CWRs for both benign and malignant indications using the BSM. This combination of BSMs appears to more stable with improved integrity of the chest, especially in areas of increased excursion (lower chest) than the PLA bars and bovine pericardial patch for larger defects.

In conclusion, the key to a successful outcome in this complex case was the coordinated effort by the surgical teams individualizing the patient's care with total resection of the disease process, reconstruction of the chest wall, and restoration of near-normal chest and upper abdomen anatomy and function. Chest wall reconstruction with BSM in combination with PLA bars is both safe and effective.

References

1. Ferzoco SJ. Early experience outcome of reinforced bioscaffold in inguinal hernia repair: A case series. *Int J Surg Open*. 2018;12:9-11.
2. Alaedeem DI, Lipman J, Medalie D, Rosen MJ. The single stage approach to the surgical management of abdominal wall hernias in contaminated fields. *Hernia*. 2007;11(1):41-5.
3. Miller DL, Mansour KA. Chest wall reconstruction. *Shield's Textbook of General Thoracic Surgery*. Seventh. Thomas W. Shields. Lippincott Williams & Wilkins. 2009;1:679-87.
4. Mansour KA, Thourani VH, Losken A, Reeves JG, Miller Jr JI, Carlson GW, et al. Chest wall resections and reconstruction: A 25-year experience. *Ann Thorac Surg*. 2002;73(6):1720-6.
5. Parker MJ, Kim RC, Barrio M, Socas J, Reed LR, Nakeeb A, et al. A novel biosynthetic scaffold mesh reinforcement affords the lowest hernia recurrence in the highest-risk patients. *Surg Endos*. 2021;35(9):5173-8.
6. Miller DL, Force SD, Pickens A, Fernandez FG, Luu T, Mansour KA. Chest wall reconstruction using biomaterials. *Ann Thorac Surg*. 2013;95(3):1050-6.
7. Overbeck N, Nagvajara GM, Ferzoco S, May BCH, Beierschmitt A, Qi S. *In vivo* evaluation of reinforced ovine biologic: A comparative study to available hernia mesh repair materials. *Hernia*. 2020;24(6):1293-306.
8. Wiegmann B, Korossis S, Burgwitz K, Hurschler C, Fischer S, Haverich A, et al. *In vitro* comparison of biological and synthetic materials for skeletal chest wall reconstruction. *Ann Thorac Surg*. 2015;99(3):991-8.