Journal of Clinical Obstetrics, Gynecology & Infertility

Research Article
Published: 12 May, 2017

Clinical Course of Node-Positive Squamous Cell Carcinoma of the Vulva without Adjuvant Radiotherapy

Hidetaka Nomura, Maki Matoda, Sanshiro Okamoto, Hiroyuki Kanao, Eiji Kondo, Kohei Omatsu, Kazuyoshi Kato, Kuniko Utsugi, Yuko Sugiyama and Nobuhiro Takeshima*

Department of Gynecology, Cancer Institute Hospital, Tokyo, Japan

Abstract

Aim: Radiotherapy, the most important adjuvant treatment modality for node-positive vulvar cancer, can cause severe lymphedema after inguinofemoral lymphadenectomy. To investigate the prognosis and toxicity outcomes of patients with node-positive vulvar cancer treated with surgery but not adjuvant radiotherapy.

Methods: We performed a retrospective analysis of six patients who were treated at our center from 1992 to 2015. All of these patients underwent radical surgery accompanying inguinofemoral lymphadenectomy, and were histologically diagnosed with node-positive squamous cell carcinoma of the vulva.

Results: The median length of survivor follow-up was 52 months, and the median number of lymph node metastases was 1.5 (range=1-4). Four patients received adjuvant platinum-based combined chemotherapy, and the other two patients refused chemotherapy. Recurrence was seen in three cases, and one patient who showed local recurrence had not received adjuvant chemotherapy. The median length of time to recurrence was 14 months. For the three patients with local recurrence, two patients showed local recurrence and one showed lung metastasis; radiotherapy was administered for these patients. The 3-year progression-free survival rate was 41.7%, and the 3-year overall survival rate was 80%. Grade 3 neutropenia was seen in one patient.

Conclusion: We showed a favorable prognosis of node-positive squamous cell carcinoma of the vulva without adjuvant radiotherapy. Adjuvant chemotherapy without radiotherapy may avoid excessive local therapy, and is expected to decrease distant metastasis risk, resulting in favorable prognosis. Further clinical trials are needed to prove its utility.

Keywords: Adjuvant chemotherapy; Node-positive; Prognosis; Squamous cell carcinoma; Vulvar cancer

OPEN ACCESS

Correspondence:
Hidetaka Nomura, Department of Gynecology, Cancer Institute Hospital, Ariake 3-8-31, Koto-ku, Tokyo 135-8550, Japan, Tel: +81 3 3520 0111; Fax: +81 3 3520 0141; E-mail: hidetaka.nomura@jfcr.or.jp

Received Date: *06 Apr 2017*
Accepted Date*: 05 May 2017*
Published Date*: 12 May 2017*

Citation:
Nomura H, Matoda M, Okamoto S, Kanao H, Kondo E, Omatsu K, et al. Clinical Course of Node-Positive Squamous Cell Carcinoma of the Vulva without Adjuvant Radiotherapy. J Clin Obstet Gynecol Infertil. 2017; 1(2): 1007.

Introduction

With an incidence of two to three cases per 100,000 women per year, vulvar cancer is a relatively rare disease that traditionally affects elderly women [1]. Lymph node involvement is the most critical prognostic factor in vulvar cancer, and results in higher recurrence rates and decreased overall survival (OS) [2-4]. For patients with respectable disease, adjuvant radiotherapy after surgical excision of the primary tumor and inguinofemoral lymphadenectomy improves the prognosis in patients with nodal involvement [5].

Further, adjuvant chemoradiation is now considered as a method of improving the outcomes of these patients [6]. However, adjuvant chemotherapy for patients with node-positive vulvar cancer has not been fully examined. In the case of cervical cancer, which is a human papillomavirus related cancer, several authors have reported the possibility of adding chemotherapy as an adjuvant treatment for patients at high risk of recurrence [7-9].

As we previously reported in a study of cervical cancer, compared with adjuvant radiotherapy, we believe that postoperative chemotherapy may confer the following benefits: 1) it is considered to be the most powerful means of suppressing distant metastasis; 2) it carries a lower rate of morbidity than radiotherapy; and 3) local recurrence can be treated with radiotherapy or chemoradiation [10]. Neoadjuvant chemotherapy for locally advanced vulvar cancer shows a high response rate of 80% to 100% [11-13], which means that vulvar cancer, is highly chemosensitive. However, as far as we know, only one study has examined the role of adjuvant chemotherapy [14]. To our knowledge,

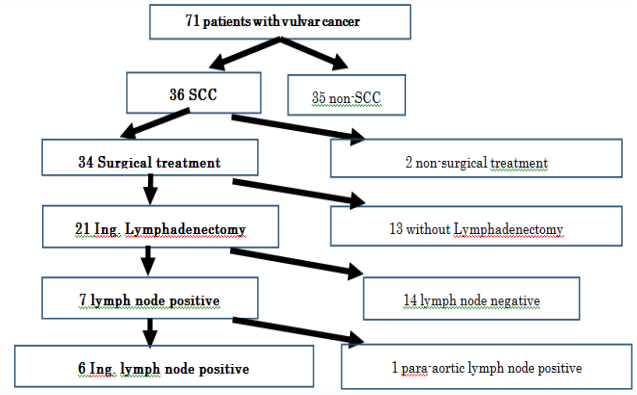

Figure 1: Study design.
SCC: Squamous Cell Carcinoma; Ing: Inguinal.

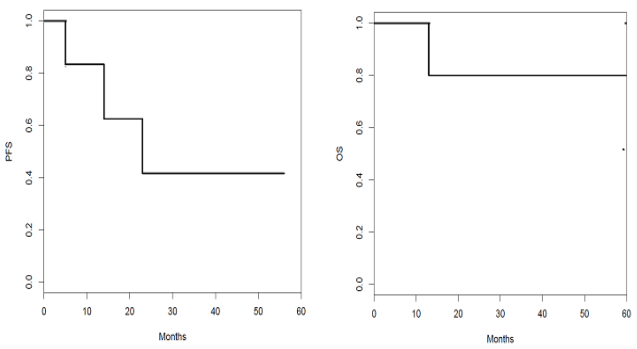

Figure 2: Kaplan–Meier analysis of progression-free survival (PFS; left panel) and overall survival (OS; right panel).

our study is the first to show the effectiveness of platinum-based combined adjuvant chemotherapy without adjuvant radiotherapy on vulvar cancer.

Materials and Methods

Patients

Seventy-one patients with primary vulvar cancer were treated at the Cancer Institute Hospital between 1992 and 2015. After approval by the institutional review board, we retrospectively reviewed the clinical records and pathological material of the patients. Of the 71 patients, 36 patients were pathologically diagnosed with squamous cell carcinoma. Thirty-four patients were surgically treated, and 21 patients also underwent bilateral or ipsilateral inguinofemoral lymphadenectomy. Seven patients were pathologically diagnosed with node-positive vulvar cancer; six of these patients were confirmed to have inguinal lymph node involvement alone, whereas the other one had para-aortic lymph node metastasis (Figure 1). These patients were staged according to the International Federation of Gynecology and Obstetrics (FIGO) system. The diagnosis in all cases was confirmed via histological analysis performed by two gynecological pathologists. The patients' information was collected, including age at diagnosis, FIGO stage, number of lymph node metastases, surgical margin of initial surgery, chemotherapy regimen, site of metastasis, site of recurrence, progression-free survival (PFS), and OS.

Treatment protocol

The patients initially underwent radical surgery and bilateral inguinofemoral lymphadenectomy. Inguinofemoral lymphadenectomy included both superficial and deep nodes relative to the inguinofemoral fascia, including nodal skeletonization of the femoral artery and vein. Nodal tissue medial to the femoral artery and vein was designated the Cloquet's node and surgically excised. A standardized extraperitoneal approach was followed for patients undergoing pelvic node resection, thereby enabling excision of the external iliac, internal iliac, obturator, and common iliac nodes. Patients who were diagnosed as node positive were recommended to undergo four to five cycles of adjuvant chemotherapy. Regimens were chosen according to our experience with them for other squamous cell carcinomas, especially cervical cancer. Until 2007, bleomycin 7 mg, days 1-5; vincristine 0.7 mg/m^2, day 5; mitomycin 7 mg/m^2, day 5; cisplatin 15 mg/m^2, day 1 (BOMP; 21-day cycle) was administered, and thereafter, (CPT-11 60 mg/m^2, day 1; nedaplatin 80 mg/m^2, day 1 (CPT/NDP; 28-day cycle) was administered. Toxicity was evaluated according to the Common Terminology Criteria for Adverse Events version 4.0. PFS and overall OS were calculated using the Kaplan–Meier method using R (version 3.0.1).

Results

We identified six cases of node-positive vulvar cancer that initially underwent surgical treatment (Table 1). The mean age at the time of the initial diagnosis was 68.2 years (range=52-87 years), and the median survivor follow-up was 52 months. Three patients received a pelvic lymphadenectomy. The median number of lymph node metastases was 1.5 (range=1-4). All of these patients were recommended to undergo adjuvant chemotherapy, and two refused to receive both chemotherapy and radiotherapy. However, we included these two patients who refused to receive chemotherapy because they did not undergo postoperative radiotherapy. If they underwent adjuvant chemotherapy, the results of this study may have been better.

Of those four patients who received chemotherapy, one patient (case 3) could not receive the recommended number of regimen cycles due to its toxicity (nausea/vomiting grade 2). Grade 3

Table 1: Treatment data of the patients.

Case	Age (years)	Clinical stage	Operation	Inguinal LN†	Pelvic LN	Surgical margin	CT‡ (cycle)	Recurrence site	PFS§ (mo)//	Status	OS¶ (mo)
1	87	T4AN1M0	RV††+BIL‡‡	1/28	0	negative		vagina	14	DOD§§	69
2	52	T1BN1M0	RV+BIL+PLA//	1/26	0/19	positive	BOMP¶ (4)	lung	5	DOD	13
3	70	T1BN2M0	RV+BIL+PLA	2/12	0/21	negative	BOMP (2)	inguinal LN, pelvic LN, local	23	DOD	64
4	72	T1BN2M0	RV+BIL	2/32	0	negative	CPT/NDP††† (4)			NED‡‡‡	60
5	70	T1BN2M0	RV+BIL	4/17	0	negative				NED	52
6	58	T4AN1M0	RV+BIL+PLA	1/15	0/18	negative	CPT/NDP (5)			NED	10

†: lymph node, ‡: chemotherapy, §: progression-free survival, //: month, ¶: overall survival, ††: radical vulvectomy, ‡‡: bilateral inguinofemoral lymphadenectomy, §§: died of disease, ////: pelvic lymphadenectomy, ¶¶: bleomycin, vincristine, mitomycin, cisplatin, †††: CPT-11, nedaplatin, ‡‡‡: no evidence of disease

Table 2: Adverse effects of adjuvant chemotherapy.

	Number of patients		
Grade	2	3	4
Leukopenia	1	0	0
Neutropenia	0	1	0
Thrombocytopenia	0	0	0
Anemia	2	0	0
Nausea/vomiting	1	0	0

neutropenia was observed in one patient. The adverse effects of the adjuvant chemotherapy are listed in Table 2.

Recurrence was seen in three cases, and the median time to recurrence was 14 months. One patient who showed local recurrence had not received adjuvant chemotherapy. Two cases showed local recurrence, and one case showed lung metastasis. For those patients who showed local recurrence (cases 1 and 3), radiotherapy was administered for the recurrent site. For the patient, with lung metastasis (case 2), another chemotherapy regimen (paclitaxel and carboplatin) was administered. The median observational time was 52 months (range=10-69 months), and the 3-year PFS and 3-year OS were 41.7% and 80%, respectively (Figure 2).

Discussion

A favorable prognosis was found for postoperative chemotherapy without radiotherapy for node-positive vulvar squamous cell carcinoma. To our knowledge, this is the first study to show the effectiveness of adjuvant platinum-based combined chemotherapy. Platinum-based combined chemotherapy is currently used as adjuvant chemotherapy for gynecologic malignancies. Although Bellati et al. [14] used cisplatin in the adjuvant setting; it may not be enough to control this invisible disease. In our study, the adverse side effects of platinum-based combined chemotherapy were acceptable. Mahner et al. [15] reported that the 3-year PFS and 3-year OS of node-positive patients were 35.2% and 56.2%, respectively. In addition, patients who underwent adjuvant therapy, which is mainly radiotherapy, showed statistically better prognoses, with 3-year PFS and 3-year OS of 39.6% and 57.7%, respectively. Our data showed a similar 3-year PFS but better 3-year OS.

Vulvar cancer has historically been considered a chemo resistant tumor [16,17]. However, some studies have shown the effectiveness of neoadjuvant chemotherapy for vulvar cancer, and combination chemotherapy has been shown to deliver an even better clinical response [11-13,18]. In addition, it has been reported that chemotherapy for recurrent or metastatic disease is not as effective as in the neoadjuvant setting. The lower response rate may be due to the high numbers of patients with recurrence in previously radiated fields. Prior radiotherapy has been suggested to decrease responsiveness to chemotherapy by reducing tissue perfusion. Moreover, it remains unclear if recurrent disease inside the original radiation field is more resistant to further treatment [15]; chemotherapy must be administered not long after radiotherapy, which may decrease the responsiveness of the tissue to chemotherapy. Gill et al. [19] reported the effect of adjuvant chemotherapy on patients with node-positive vulvar cancer who received adjuvant radiotherapy, and there was a 38% reduction in the risk of overall mortality in patients who underwent adjuvant chemotherapy soon after adjuvant radiotherapy. This finding may somewhat support the effectiveness of adjuvant chemotherapy, which may decrease the risk of distant metastasis and suppress tumor growth.

Adjuvant radiotherapy is reportedly associated with a high risk of severe acute and late complications such as lymphedema, local irritation, and desquamation, as well as buttock or groin pain due to sacral and pubic fractures [20]. For patients who refuse adjuvant radiotherapy, local recurrence can be treated with radiotherapy or chemoradiation. There are a few advantages of chemotherapy compared with radiotherapy, including treatment of subclinical metastases, lower risk of local acute diseases, and lower risk of long-term complications due to the absence of local tissue damage [21]. Few severe adverse side effects of chemotherapy were observed in the present study.

In our study, a favorable OS was observed in two cases (cases 1 and 3) treated by radiotherapy after local recurrence. Case 2 showed rapid distant metastasis in the lung, and the subsequent chemotherapy did not manage the disease; we believe that in this case, adjuvant radiotherapy would not have cured the patient. For the other three cases, recurrence and metastases have not become apparent. The Gynecologic Oncology Group published GOG37, investigating the value of pelvic lymphadenectomy compared with irradiation of the groin and pelvis after vulvectomy and inguinofemoral lymphadenectomy in a group of 114 patients [6]. A survival benefit for patients with two or more positive groin nodes was observed in the irradiation group. In our study, three cases had two or more positive groin nodes, and these three patients survived for more than 52 months with or without disease. Adjuvant chemotherapy without radiotherapy may prevent excessive local therapy, and is expected to decrease the risk of distant metastasis, resulting in a favorable prognosis.

Our study is limited by its retrospective nature and small sample size because of the rarity of the disease, especially in Japan. In addition, the chemotherapy regimen and total cycle that we administered were not standardized. Hence, we cannot draw conclusions regarding the effectiveness of our chemotherapy procedures, and further investigation is needed.

We showed the favorable prognosis of node-positive squamous cell carcinoma of the vulva without adjuvant radiotherapy. Administration of platinum-based combined chemotherapy before radiotherapy reportedly shows a high response rate, and is expected to decrease the risk of distant metastases. Chemotherapy may be a good candidate for adjuvant therapy. Adjuvant chemotherapy without radiotherapy may avoid excessive local therapy, and is expected to decrease the risk of distant metastasis, resulting in a favorable prognosis. Phase II clinical trials are needed to prove its utility.

References

1. Beller U, Quinn MA, Benedet JL, Creasman WT, Ngan HY, Maisonneuve P, et al. Carcinoma of the vulva. FIGO 26th Annual Report on the Results of Treatment in Gynecological Cancer. Int J Gynaecol Obstet. 2006; 95(1):S7-27.

2. Homesley HD, Bundy BN, Sedlis A, Yordan E, Berek JS, Jahshan A, et al. Prognostic factors for groin node metastasis in squamous cell carcinoma of the vulva (a Gynecologic Oncology Group study). Gynecol Oncol. 1993;49:279-83.

3. Figge DC, Tamimi HK, Greer BE. Lymphatic spread in carcinoma of the vulva. Gynecol Oncol. 1985;152:387-94.

4. Homesley HD, Bundy BN, Sedlis A, Yordan E, Berek JS, Jahshan A, et

al. Assessment of current International Federation of Gynecology and Obstetrics staging of vulvar carcinoma relative to prognostic factors for survival (a Gynecologic Oncology Group study). Am J Obstet Gynecol. 1991;164:997-1003.

5. Mahner S, Jueckstock J, Hilpert F, Neuser P, Harter P, de Gregorio N, et al. Adjuvant therapy in lymph node-positive vulvar cancer: the AGO-CaRE-1 study. J Natl Cancer Inst. 2015;107.

6. Homesley HD, Bundy BN, Sedlis A, Adcock L. Radiation therapy versus pelvic node resection for carcinoma of the vulva with positive groin nodes. Obstet Gynecol. 1986;68:733-40.

7. Mossa B, Mossa S, Marziani R. Adjuvant chemotherapy versus radiation therapy after radical surgery in high-risk positive node stage IB/IIA cervical cancer. Eur J Gynaecol Oncol. 2010;31:545-50.

8. Takeshima N, Umayahara K, Fujiwara K, Hirai Y, Takizawa K, Hasumi K. Treatment results of adjuvant chemotherapy after radical hysterectomy for intermediate- and high-risk stage IB-IIA cervical cancer. Gynecol Oncol. 2006;103:618-22.

9. Angioli R, Luvero D, Aloisi A, Capriglione S, Gennari P, Linciano F, et al. Adjuvant chemotherapy after primary treatments for cervical cancer: a critical point of view and review of the literature. Expert Rev Anticancer Ther. 2014;14:431-39.

10. Matsumura M, Takeshima N, Ota T, Omatsu K, Sakamoto K, Kawamata Y, et al. Neoadjuvant chemotherapy followed by radical hysterectomy plus postoperative chemotherapy but no radiotherapy for Stage IB2-IIB cervical cancer--irinotecan and platinum chemotherapy. Gynecol Oncol. 2010;119:212-6.

11. Geisler JP, Manahan KJ, Buller RE. Neoadjuvant chemotherapy in vulvar cancer: avoiding primary exenteration. Gynecol Oncol. 2006;100:53-7.

12. Raspagliesi F, Zanaboni F, Martinelli F, Scasso S, Laufer J, Ditto A. Role of paclitaxel and cisplatin as the neoadjuvant treatment for locally advanced squamous cell carcinoma of the vulva. J Gynecol Oncol. 2014;25:22-9.

13. Aragona AM, Cuneo N, Soderini AH, Alcoba E, Greco A, Reyes C, et al. Tailoring the treatment of locallyadvancedsquamouscellcarcinoma of the vulva: neoadjuvant chemotherapy followed by radical surgery: results from a multicenter study. Int J Gynecol Cancer. 2012;22:1258-63.

14. Bellati F, Angioli R, Manci N, Angelo ZM, Muzii L, Plotti F, et al. Single agent cisplatin chemotherapy in surgically resected vulvar cancer patients with multiple inguinal lymph node metastases. Gynecol Oncol. 2005;96:227-31.

15. Mahner S, Prieske K, Grimm D, Trillsch F, Prieske S, von Amsberg G, et al. Systemic treatment of vulvar cancer. Expert Rev Anticancer Ther. 2015;15:629-37.

16. Deppe G, Cohen CJ, Bruckner HW. Chemotherapy of squamous cell carcinoma of the vulva: a review. Gynecol Oncol. 1979;7:345-8.

17. Thigpen JT, Blessing JA, Homesley HD, Lewis Jr GC. Phase II trials of cisplatin and piperazinedione in advanced or recurrent squamous cell carcinoma of the vulva: a gynecologic oncology group study. Gynecol Oncol. 1986;23:358-63.

18. Domingues AP, Mota F, Durão M, Frutuoso C, Amaral N, de Oliveira CF. Neoadjuvant chemotherapy in advanced vulvar cancer. Int J Gynecol Cancer. 2010;20:294-8.

19. Gill BS, Bernard ME, Lin JF, Balasubramani GK, Rajagopalan MS, Sukumvanich P, et al. Impact of adjuvant chemotherapy with radiation for node-positive vulvar cancer: A National Cancer Data Base (NCDB) analysis. Gynecol Oncol. 2015;137:365-72.

20. Salom EM, Penalver M. Recurrent vulvar cancer. Curr Treat Options Oncol. 2002;3:143-53.

21. Payne WG, Walusimbi MS, Blue ML, Mosiello G, Wright TE, Robson MC. Radiated groin wounds: pitfalls in reconstruction. Am Surg. 2003;69:994-7.