



## Characterization Endobronchial by Ebus Radial of the Lobular Capillary Hemangioma

Sánchez Ríos Carla\*, Jáquez Carrasco Miguelina, López González Berenice, Izquierdo García Iván, Martínez Mendoza Dina and Sánchez Cabral Olivia

Department of Pulmonology and Interventional Service, National Institute of Respiratory Diseases, USA

### Introduction

Pyogenic granuloma (PG), also known as capillary lobular hemangioma (HLC), is an uncommon non-neoplastic lesion characterized by vascular proliferation and frequently found in the skin and oral mucosa [1,3]. It is considered that this pathology represents a angiogenesis disorder. Specifically, skin presentations occur in all age groups and with the same prevalence by gender, except for the oral mucosa presentation that appears more frequently in women. The lesions are usually smooth or multilobulated, red to purple and sessile or pedunculated, rarely exceeding 2.5 cm. The definitive diagnosis is based on the histopathological study, which reveals capillaries of different sizes surrounded by connective tissue [4-6]. The etiology of HLC is still unclear. The lesions may develop spontaneously or as a sequel to local irritation and trauma. In addition, it is known that hormonal factors and stimulation of growth factors with granulation tissue development play an important role in the development of these lesions. Bacterial or viral coinfection usually occurs [7].

### Clinical Image

A 36-year-old man presented with a 2-month disease characterized by dyspnea, coughing and wheezing. It has a history of interest to have presented 4 months ago a pneumonia due to Influenza AH1N1 with VMI and a stay in the Intensive Care Unit for a week in the reference Hospital from where he graduated without apparent complications. He referred after a pneumonic event, which persisted with symptoms of coughing, wheezing and dyspnea, with an ambulatory BCF procedure in the referred hospital, with macroscopic findings of endobronchial polypoid lesions and negative results of BAL culture. The patient is referred to our Institution for ultrasonographic characterization and biopsies of endoluminal lesions of the bronchial tree. Upon arrival, a stable patient is received with the following vital signs: FC 98 FR 24 Temp 36.4 TA 110/70 mmHg and Sat 89% AA. It is programmed for FBC in the Interventional Pneumology Service of our Institute for USG tracking by EBUS radial and biopsy of endobronchial lesions. Within the preoperative approach, Computed Axial Tomography (CT) of the simple thorax with ground-glass opacity and endobronchial nodular lesions in bronchial lumen (Figure 1,2) as well as pulmonary function tests, finding spirometry with severe airflow obstruction without response, is requested. a bronchodilator with FEV1 40% predicted, carbon monoxide diffusion test (DLCO) with moderate decrease (58% of the predicted corrected by height). Perfusion ventilation gammagram with poor left lung function in lingula and basal segments (Figure 3). During the procedure of invencionismo, the following findings are reported: the use of EBUS-R (radial endobronchial ultrasound) shows multiple polypoid lesions in the entire bronchial tree bilaterally with invasion of airway cartilage (Figure

### OPEN ACCESS

#### \*Correspondence:

Carla Paola Sánchez Ríos, Department of Pulmonology and Interventional Service, National Institute of Respiratory Diseases, Mexico, USA, E-mail: pao1144tost@gmail.com

Received Date: 19 Dec 2017

Accepted Date: 27 Dec 2017

Published Date: 03 Jan 2018

#### Citation:

Carla SR, Miguelina JC, Berenice LG, Iván IG, Dina MM, Olivia SC. Characterization Endobronchial by Ebus Radial of the Lobular Capillary Hemangioma. Clin Respirat Med. 2018; 1(1): 1002.

Copyright © 2018 Sánchez Ríos Carla. This is an open access article distributed under the Creative Commons Attribution License, which permits unrestricted use, distribution, and reproduction in any medium, provided the original work is properly cited.

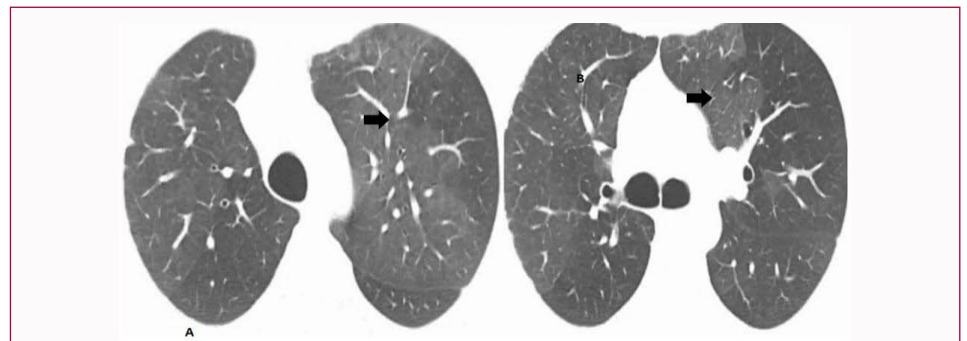
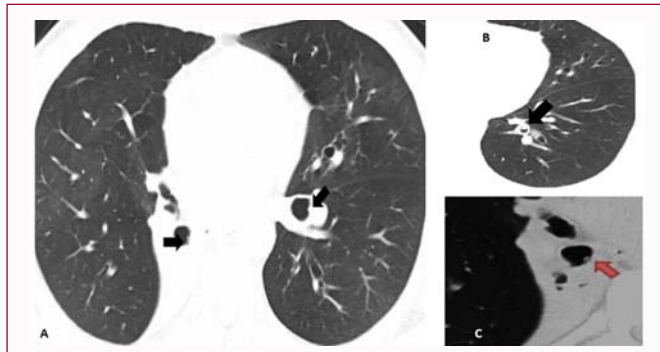
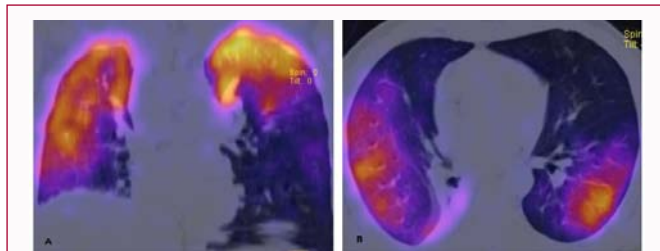


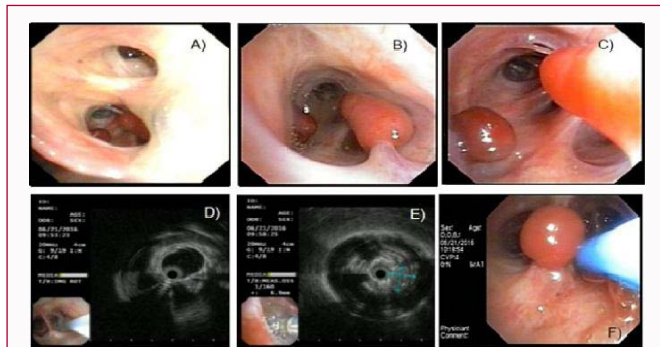
Figure 1: Axial slices of single-phase chest computed axial tomography in window for pulmonary parenchyma at the level of the lower third of the trachea (A) and carina (B) showing bilateral diffuse ground-glass opacity.



**Figure 2:** Computed tomography slices of the chest in a simple phase, Window for lung parenchyma. Axial slices at the level of the LII and LID bronchi are demonstrated with endoluminal lesions (A) and (C). Cut at the bronchial level of the left segment 9 with endobronchial lesion (B).



**Figure 3:** SPECT/CT fusion images in perfusion phase. Coronal fusion (A) and axial fusion showing lack of uptake of <sup>99m</sup>Tc-macroaggregate albumin translating absence of perfusion in basal and posterior segments of LII (A) as well as in LM and lingual (B).

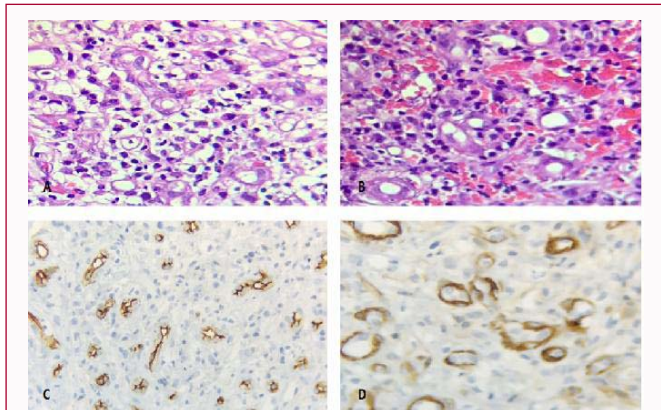


**Figure 4:** A, B) and C) Evidence multiple polypoid lesions in LII, segment 9 and 10. D) and E) Exploration with radial EBUS showing involvement of the bronchial cartilage by infiltration of multiple polypoid lesions (larger size 6.9 mm). F) Cryobiopsies of endoluminal lesions with probe 1.9.

4,5). Cryobiopsies of endoluminal lesions. Histopathological result of cryobiopsies of polypoid lesions: capillary lobular hemangioma with IHC (immunohistochemistry) CD34 positive. Resection of larger polypoid lesions was performed and subsequently left inferior lobectomy was performed due to functional exclusion. Currently in outpatient follow-up for pulmonology and thoracic surgery of our center.

**Discussion**

Capillary lobular hemangiomas, with a polypoid form of capillary hemangiomas that are very often found on the skin and surface of oral mucosa. There are multiple reports of this type of vascular lesions in the nasal cavity, tongue, conjunctiva, penis, duodenum and colon [8]. They are usually found more in the pediatric age, however, there are reports of presentation in adults. The pathogenesis of the disease is



**Figure 5:** A) HE stain at 20X where blood vessels are observed in neoformation without atypias, surrounded by fibro-connective septa. B) HE staining at 40X where blood vessels surrounded by mononuclear inflammatory infiltrate and erythrocytes are observed in the light of them. C) and D) Immunohistochemistry (IHC) reaction with CD34 that marks endothelial cells (wall of blood vessels) at 20X and 40X respectively.

currently unclear despite the discussion of viral oncogenic pathways within its possible etiopathogenesis. Hemoptysis and obstruction of the respiratory tract are the most common symptoms (up to 25%) of patients with lobular capillary hemangiomas in the tracheobronchial tree. An accurate diagnosis of this condition requires a tomographic and bronchoscopic approach. The imaging findings are not typical and usually the literature describes that there is usually homogenous enhancement to the administration of contrast [9,10]. In this case the patient already had his recent tomographic study without contrast and the endobronchial characterization of the lesion for EBUS and cryobiopsy. We proceeded to characterize the polypoid lesions through EBUS-R, finding multiple polypoid lesions of intrinsic, hypogenic origin with infiltration of the tracheobronchial wall with an area of 31.1 mm on average in those of larger size. Only 8 cases of HLC of the tracheal mucosa have been previously reported in the literature. The majority of cases reported were male, with unique lesions and proximal trachea involvement; only one case had been reported with multiple injuries. The usual symptoms described were cough and hemoptysis [11]. This is the first case of complete involvement of the tracheobronchial tree with multiple lesions and with EBUS-R characterization.

**Conclusion**

HLC is a rare disease. Endobronchial presentation usually manifests with cough and hemoptysis. The evaluation of these lesions by means of EBUS-R allows the characterization of the lesions with assessment of the involvement of the tracheobronchial wall.

**References**

1. Mills SE, Cooper PH, Fechner RE. Lobular capillary hemangioma: the underlying lesion of pyogenic granuloma. A study of 73 cases from the oral and nasal mucous membranes. *Am J Surg Pathol.* 1980; 4(5): 470-9.
2. Fechner RE, Cooper PH, Mills SE. Pyogenic granuloma of the larynx and trachea. A causal and pathologic misnomer for granulation tissue. *Arch Otolaryngol.* 1981;107(1):30-2.
3. Madhumita K, Sreekumar KP, Malini H, Indudharan R. Tracheal haemangioma: case report. *J Laryngol Otol.* 2004;118(8):655-8.
4. Hirakawa K, Aoyagi K, Yao T, Hizawa K, Kido H, Fujishima M. A case of pyogenic granuloma in the duodenum: successful treatment by endoscopic snare polypectomy. *Gastro Intest Endosc.* 1998;47(6):538-40.

5. Amy FT, Enrique DG. Lobular capillary hemangioma in the posterior trachea: a rare cause of hemoptysis. *Case Rep Pulmonol.* 2012; 2012: 592524.
6. Harris MN, Desai R, Chuang TY, Hood AF, Mirowski GW. Lobular capillary hemangiomas: an epidemiologic report, with emphasis on cutaneous lesions. *J Am Acad Dermatol.* 2000;42(6):1012-16.
7. Irani S, Brack T, Pfaltz M, Russi EW. Tracheal lobular capillary hemangioma: a rare cause of recurrent hemoptysis. *Chest.* 2003;123(6):2148-9.
8. Porfyridis I, Zisis C, Glinos K, Stavrakaki K, Rontogianni D, Zakynthinos S, et al. Recurrent cough and hemoptysis associated with tracheal capillary hemangioma in an adolescent boy: a case report. *J Thorac Cardiovasc Surg.* 2007;134:1366-7.
9. Chawla M, Stone C, Simoff MJ. Lobular capillary hemangioma of the trachea: the second case. *J Bronchology Interv Pulmonol.* 2010;17(3):238-40.
10. Udoji TN, Bechara RI. Pyogenic granuloma of the distal trachea: a case report. *J Bronchology Interv Pulmonol.* 2011;18(3): 281-4.
11. Xu Q, Yin X, Sutedjo J, Sun J, Jiang L, Lu L. Lobular capillary hemangioma of the trachea. *Arch Iran Med.* 2015;18 (2):127-9.