Annals of Surgical Case Reports

Case Report
Published: 31 Oct, 2022

Atypical Recurrent Nonbacterial Endocarditis on Bioprosthesis

Roxana B[1,2], Bertrand M[1], Paul G[2] and Jean P[1]*

[1]Department of Cardiovascular Surgery, Rangueil University Hospital, Toulouse, France

[2]Department of Cardiology, Rangueil University Hospital, Toulouse, France

Abstract

Nonbacterial Thrombotic Endocarditis (NBTE) is a rare manifestation of a hypercoagulable state, frequently due to an occult cancer, characterized by the deposition of fibrin vegetations on cardiac valves and rarely described on biological valvular prosthesis. Its diverse clinical presentation is commonly related to embolic complications. Its management mainly addresses the underlying cause. An anticoagulation regimen should be associated, and best evidence still favors low-molecular weight heparins. We report the case of a recurrent NBTE on a bioprosthetic aortic valve despite direct oral anticoagulation, in a patient with pancreatic adenocarcinoma.

Keywords: Nonbacterial Thrombotic Endocarditis; Infective endocarditis; Transesophageal Echocardiography

Abbreviations

CT: Computed Tomography; DOAC: Direct Oral Anticoagulant; IE: Infective Endocarditis; LMWH: Low Molecular Weight Heparin; NBTE: Nonbacterial Thrombotic Endocarditis; TTE: Transthoracic Echocardiography; TEE: Transesophageal Echocardiography

Introduction

Valvular vegetations without arguments for an infective endocarditis should always raise the suspicion for a NBTE and thus, for a hypercoagulable state. The optimal management includes systemic anticoagulation and treatment of the underlying disease.

Objectives

- To be able to make the diagnosis of NBTE.
- To be able to make the differential diagnosis between NBTE and infective endocarditis and by doing so, to assess a correct management.

Case Presentation

A 61-year-old male underwent surgical valve replacement for a severe aortic stenosis. Perioperatively, the surgeon found multiple vegetations on the aortic cusps, without valvular destruction. Infective Endocarditis (IE) was excluded due to an anatomopathological exam showing fibrin vegetations associated to inflammatory reaction and negative microbiological exams (including ARN 16 S bacterial sequencing and serology for atypical bacteria). Initial empiric antibiotherapy was stopped at postoperative day 15. At discharge, the Transthoracic Echocardiography (TTE) showed a normal-functioning bioprosthesis (no regurgitation, peak transcortical velocity 2.8 m/sec, mean gradient 18 mmHg and a velocity index of 0.5). The patient was discharged under systemic Direct Oral Anticoagulation (DOAC), apixaban 5 mg b.i.d, because of postoperative atrial fibrillation.

At the first post-discharge follow-up (10 days), TTE showed a prosthesis with an obstructive hemodynamic profile (peak velocity 4.8 m/sec and mean gradient 68 mmHg) while the patient was clinically asymptomatic. The clinical exam was normal despite a systolic aortic murmur. The biological workup only showed an elevated C-reactive protein (80 mg/L for a normal value of <5 mg/L) which could have been explained by the recent operative setting. The patient was readmitted in our institution for further investigation.

An empiric antibiotherapy was started (Gentamycin 3 mg/kg/day, Vancomycin 30 mg/kg/day and Rifampicin 900 mg orally/day) targeting nosocomial and non-nosocomial agents which could

OPEN ACCESS

Correspondence:
Botea Roxana, Department of Cardiology Rangueil University Hospital, 1, Avenue Jean Poulhès TSA 50032 - 31059 Toulouse, France, Tel: +33 (0) 783 01 72 39; Fax: +33 (0) 561 322 959;
E-mail: roxana2288@gmail.com

Received Date: *04 Oct 2022*
Accepted Date*: 26 Oct 2022*
Published Date*: 31 Oct 2022*

Citation:
Roxana B, Bertrand M, Paul G, Jean P. Atypical Recurrent Nonbacterial Endocarditis on Bioprosthesis. Ann Surg Case Rep. 2022; 5(2): 1062.

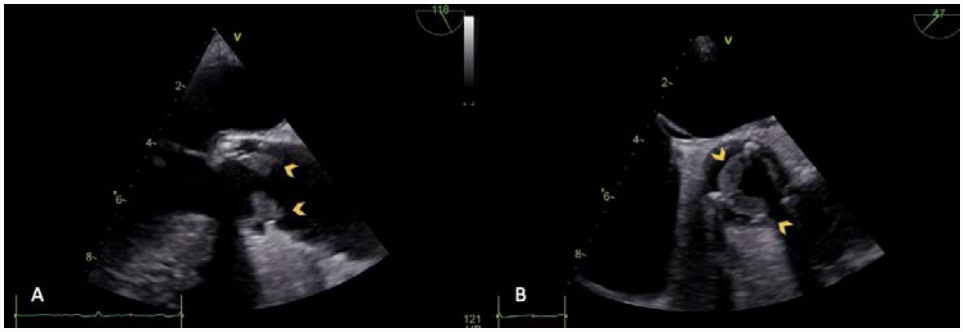

Figure 1: Transesophageal echocardiography suggesting aortic prosthesis endocarditic vegetations.
(A). Mid-esophageal long-axis view, showing an aortic bioprosthesis with thickened free margin of the non-coronary and right cusps (yellow arrows). (**B**). Mid-esophageal short-axis view, showing an aortic bioprosthesis with thickened free margin of all cusps' (yellow arrows), Leaflets mobility is preserved but opening is reduced.

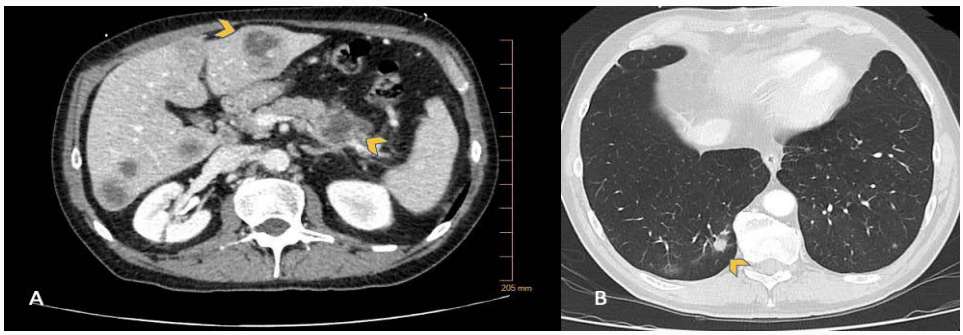

Figure 2: (A). Abdominal computed tomography with contrast showing hypodense pancreatic and hepatic masses (yellow arrows), suggesting metastatic pancreatic adenocarcinoma. **(B)**. Pulmonary computed tomography with contrast showing speculated nodules in the right superior lobe (yellow arrow). Relating to pancreatic body and hepatic masses, it suggests a metastatic determination.

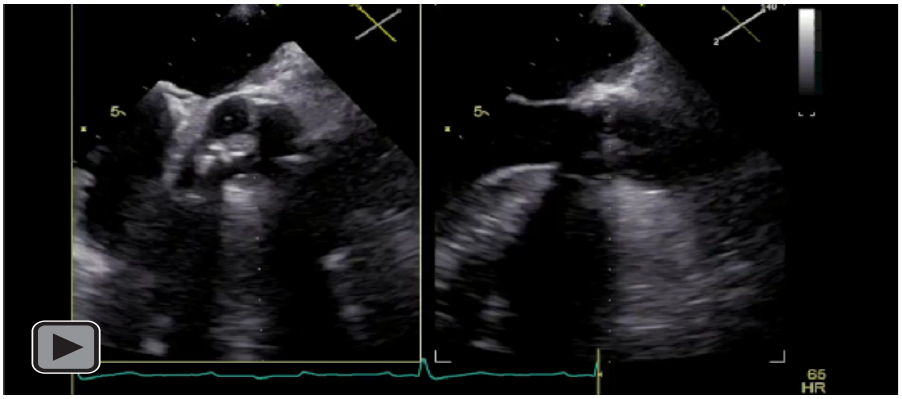

Video 1: Transesophageal echocardiography with X-plan 2D reconstruction showing an aortic bioprosthesis at three weeks after implantation, with thickened cusps' free margins, suggesting vegetations. Leaflets mobility is preserved but opening is reduced. There is no associated leaflet damage.

have been involved in an early prosthetic valve endocarditis. We maintained the same anticoagulation regimen (apixaban 5 mg b.i.d). Nevertheless, all drawn blood cultures came back negative. Further on, we performed a Transesophageal Echocardiography (TEE) which revealed thickened and fixed prosthetic cusps, with hypoechogenic extremities (Figure 1 and Video 1). There was neither an aortic regurgitation nor any signs of mitro-aortic abscess. On the other hand, the exam visualized 10 mm mobile vegetation on the posterior mitral valve commissure (Video 2).

A whole-body CT-scan underscored a large hypodense mass of the pancreatic body, several hypodense hepatic masses (Figure 1A), multiple speculated nodules localized in the right superior pulmonary lobe, bilateral segmental embolisms (Figure 1B), as well as bilateral renal and splenic infarcts. The cerebral contrast CT was normal. An echo-guided liver biopsy was then performed. The biopsy specimen revealed a pancreatic moderately differentiated adenocarcinoma with mucinous features and the immunohistochemical markers reported were CK20, CK7, MUC5 TTF [1].

The final diagnosis was that of a NBTE on aortic bioprosthetic and the native mitral valve, secondary to a pancreatic metastatic adenocarcinoma.

After multidisciplinary team discussion, in the absence of bacterial documentation, the empiric antibiotherapy initiated at admission was stopped. Given the good hemodynamic tolerance and

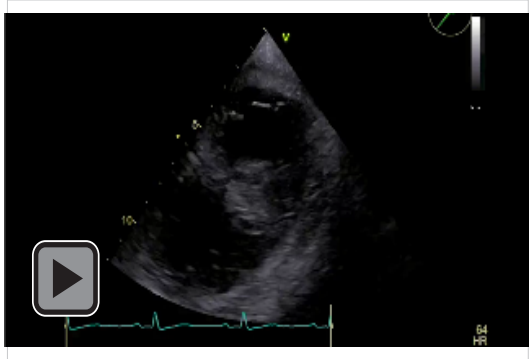

Video 2: Transesophageal echocardiography, mid-esophageal mitral commissural view showing the native mitral valve with 10 mm vegetation at the posterior commissure. There is no associated valvular damage. Due to concomitant aortic bioprosthetic vegetations, endocarditis should be evoked.

the absence of recurrent thromboembolism, the team considered there was no surgical indication [2,3]. Previous DOAC treatment was switched to a Low Molecular Weight Heparin (LMWH) (tinzaparin, 175 anti-Xa IU, subcutaneously, daily), as appropriate in case of cancer-related hypercoagulability state [4]. TEE repeated at 10 days found stable parameters (Figure 2).

Otherwise, the oncology team considered the underlying advanced multi metastatic pancreatic adenocarcinoma, as inoperable and favored a chemotherapy based on the FOLFIRINOX protocol (oxaliplatin, irinotecan, leucovorin and fluorouracil) in order to achieve remission.

The patient had a follow-up consultation every three months. A transthoracic echocardiography was performed at each time-point, showing stable aortic hemodynamic parameters and no progression at the level of the mitral valve vegetation. One-year after the diagnosis, the patient is still alive. Unfortunately, he recently presented ascites and other signs of hepatic failure, thus the initial chemotherapy FOLFIRINOX protocol were switched to a study protocol.

Discussion

NBTE is described in patients having an underlying (neoplastic or inflammatory) condition inducing a hypercoagulability state that promotes valvular deposition of fibrin and platelets forming vegetations highly prone to embolize as they have little inflammatory reaction at the attachment site and little cell organization [3]. NBTE differs from IE by the absence of fever and negative blood cultures. Echocardiogram typically depicts valvular vegetations without any abscesses or valvular destruction [1]. Most of the reported cases involved native valves, while prosthetic NBTE are rare [2].

Regarding the anticoagulation strategy, the roles of DOACs in the context of cancer patient's related thrombotic events is not yet clears [5]. For this subset of patients, the best evidence for anticoagulation regimens favors LMWH [4]. The reason lies probably in the pleiotropic effects of heparins, beyond their ability to inactivate the anti-Xa factor and thrombin [4]. In our case, there was no vegetation progression under tinzaparin. Moreover, the mainstay of therapy remains treating the underlying disease.

Regarding the surgical strategy, the heart team decision was that there was no indication, the patient being asymptomatic and the embolic risk being low [2]. Furthermore, the recurrence of marantic vegetations on bioprosthesis proved that valvular surgery is probably not sufficient to treat NBTE.

Declaration

The Institutional Review Board of the Rangueil University Hospital of Toulouse, France, approved the study protocol and the publication of data (number RnlPH 2022-07) on January 10th, 2022. The patient also provided informed written consent for the publication of the study data.

References

1. Tattevin P, Watt G, Revest M, Arvieux C, Fournier PE. Update on blood culture negative endocarditis. Med Mal Infect. 2015;45(1-2):1-8.
2. Habib G, Lancellotti P, Antunes MJ, Grazia Bongiorni M, Casalta JP, Del Zotti F, et al. 2015 ESC Guidelines for the management of infective endocarditis: The task force for the management of infective endocarditis of the European Society of Cardiology (ESC). Endorsed by: European Association for Cardio-Thoracic Surgery (EACTS), the European. Eur Heart J. 2015;36(44):3075-128.
3. Asopa S, Patel A, Khan OA, Sharma R, Ohri SK. Non-bacterial thrombotic endocarditis. Eur J Cardiothorac Surg. (2007);32(5):696-701.
4. Elyamany G, Alzahrani A, Bukhary E. Cancer-associated thrombosis: An overview. Clin Med Insights Oncol. 2014;8(8):129-37.
5. Vedovati MC, Germini F, Agnelli G, Becattini C, Direct oral anticoagulants in patients with VTE and cancer: A systematic review and meta-analysis. Chest. 2015;147(2):475-83.