Annals of Plastic and Reconstructive Surgery

Research Article
Published: 26 Mar, 2020

A Different Approach to Costal Cartilage Carving for Auricular Reconstruction in Microtia

Armando G Apellaniz-Campo* and Julio Rafael Castillo Moreno

Department of Plastic Surgery, Hospital General "Dr. Manuel Gea González", Mexico

Abstract

A new approach to cartilage costal carving for auricular reconstruction is presented taking advantage of the strong synchondrosis present between the 6th and 7th costal cartilages. It allows a strong and less time consuming framework while requiring less wire fixation loops than in Nagata's traditional framework. The resulting floating helical curvature creates an auriculotemporal sulcus from the beginning and the frameworks projection can be tailored according to the needs of the patient.

Keywords: Costal cartilage carving; Auricular reconstruction; Microtia

Introduction

Auricular reconstruction has attained a large degree of finesse in the last 50 to 60 years. It has reached a point where apparently no more advances in the way the framework is constructed with autologous cartilage, but each surgeon dedicated to this extremely delicate procedure reports his or her own modifications and personal contributions to obtain the best possible results for their patients. The large variety of such contributions initiated by Tanzer [1,2], and thereafter modified by Brent, Nagata, Firmin and Zhang [3-11], have become the standard surgical practice to which every starting surgeon in this area refers to. The most important factors to consider continue to be how to construct a detailed anatomical framework that shows every aspect of the normal external ear, while preserving a thin enough cutaneous pocket that sufficiently accommodates these structures with the needed projection and detail without compromising the circulation and survival of the cutaneous envelope.

We have found that Nagata's technique of layered costal cartilage grafts is an excellent method to construct the three-dimensional frame [3], since all aspects of the reconstructed ear can be attained in detail. We consider that skin incisions however are best dealt with Firmin's approach [10], since the size of the skin flaps to form the pocket tends to be smaller, without the need to maintain the "W" skin incision and the "security pedicle" promoted by Nagata [5]. Furthermore, in our hands, the application of the described wire fixations of the different cartilage layers is time consuming and on the long run, some wires end up exposed through the skin, even if we take the time to bury the wire loop in the upper surface of the framework. In the mid 1990's, Dr. Ortiz Monasterio devised and used a costal cartilage framework in some of the patients with microtia at the Hospital General Dr. Manuel Gea Gonzalez. Its use was not extended due to the excellent reports from Dr. Nagata, and soon was forgotten. Since 2015 the senior surgeon in charge of the auricular reconstruction clinic started using it again, improving some details of the framework's construct. We have since developed a different way to construct the helical portion of the framework where skin tension is maximal, decreasing the need to apply the wire loops to a minimum quantity, while maintaining a sturdy cartilage construct that tolerates the skin pressure over it. At the same time, the framework's base has also been modified, since we feel that there is no need to have the total width of the base to support the onlay layers, while having to carve the depressions like the scapha and navicular fossa anyway.

Materials and Methods

We have found that the ideal age for auricular reconstruction is best if delayed until the patient is 9-10 years old. Thoracic perimeter of 60 cm. that is traditionally accepted is insufficient in our patient population [4], and we prefer to wait for one or two more years of costal cartilage growth, until this measurement is at least 64 cm long. The resulting width and amount of cartilage for a complete framework construction is more than enough, and surplus pieces of sufficient size are kept subcutaneously for the elevation of the framework during a second stage.

OPEN ACCESS

****Correspondence:***
Armando G Apellaniz-Campo, Department of Plastic Surgery, Auricular Reconstruction Clinic, Hospital General "Dr. Manuel Gea González", Mexico, E-mail: afuentedelcampo@prodigy.net.mx

Received Date: *01 Mar 2020*
Accepted Date*: 24 Mar 2020*
Published Date*: 26 Mar 2020*

Citation:
Apellaniz-Campo AG, Castillo Moreno JR. A Different Approach to Costal Cartilage Carving for Auricular Reconstruction in Microtia. Ann Plast Reconstr Surg. 2020; 4(1): 1050.

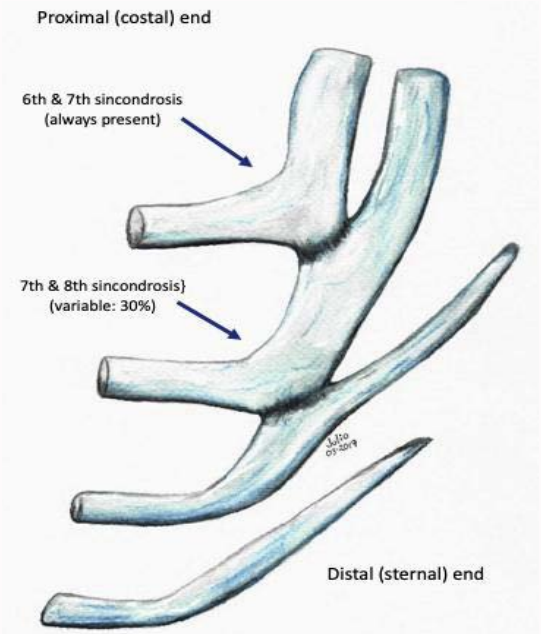

Figure 1: Typical anatomical presentation of right costal arches sixth through ninth. Synchondrosis between sixth and seventh is always present and strong. Synchondrosis between seventh and eighth is more variable. The 9th rib can be spared.

Our surgical team is divided into two groups; one will harvest the costal cartilage taking care not to damage the cartilaginous rib while dissecting the perichondrium. Nagata has demonstrated the advantages of leaving behind and repairing the perichondrium [13], so we try to leave as much as possible behind except for the synchondrosis portion of the ribs. The second team is simultaneously resecting the cartilaginous remnants and dissecting the previously marked cutaneous pocket that will receive the framework.

We normally use a semi oblique 5 cm to 6 cm skin incision following skin creases over the rib cage contralateral to the microtia site. The rectus muscle aponeurosis can either be incised longitudinally with the muscle fibers moved medially to have access to costal cartilages, or incised transversely through the rectus abdominal fibers, which allows a wider exposure of them. Rib cartilages are dissected from its union at the bony component of the ribs, to the proximity of the sternal articulation. Only the 6th, 7th, and 8th costal cartilages are harvested. Dissection of the cartilage is done in the same manner as proposed by other authors leaving it in place for future anatomical reconstruction, and sliced leftover pieces or cartilage to be returned [9]. Once the cartilages are harvested as a unit, their anatomical configuration is ideal for the framework construction (Figure 1). It is necessary to incise the visceral portion of the synchondrosis along the 6th and 7th cartilages, so that they move in a hinge-like way that keeps them still united on the anterior surface, but allows the 7th rib to be bent over the 6th, taking advantage of the natural curvature that the 7th rib describes toward the sternum. It is then reduced in its anteroposterior and cephalo-caudal width by cutting off slices on its visceral face to make it slimmer. This weakening of the deep surface allows the cartilage to be bent into the curvature needed to resemble the opposite ear. If the perichondrium was left untouched on the external surface, it will also help to maintain the planned curvature of the helix (Figure 1).

The natural and acute curvature that the 7th costal cartilage

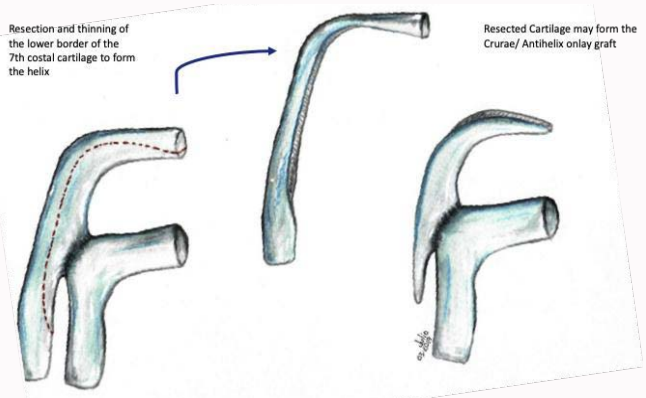

Figure 2: The lower free border of the seventh rib is resected to form the progressively thinner helical root. This portion can later be used to carve the crurae/antihelix onlay graft that will be placed on the base frame. The body of the sixth cartilage is used as the base frame.

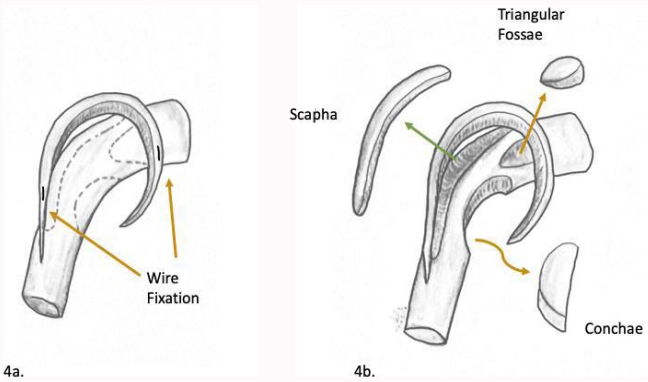

Figure 3: The seventh rib is turned over the sixth, and fixated in place with wire loops (4a). Once it is stable, portions for the scapha and triangular fossa are carved, and the depression for the concha is resected (4b).

presents in its direction toward its sternal articulation (distal portion of the rib) and the strong synchondrosis with the 6th rib make them ideal for the framework construction producing the necessary helical curvature with sufficient length, and with a strong base that holds it in place with the use of wire sutures (Figure 2). We have already used this technique in 62 patients, and have always found this synchondrosis to be strong and sufficiently large. It is not necessary to employ the whole width of the 7th rib when it is bent over the 6th, since the height and width of the natural helix is smaller and more delicate as it approaches toward the root of the helix. If the patient's rib case is sufficiently large, the resected portion of the free margin of the rib will produce enough cartilage to carve the crura/antihelix unit that will later be fixed as an onlay graft over the base of the 6th rib (Figure 3). We frequently bevel the receiving portion of the sixth rib where the seventh will be fixed with wire, so the curvature toward the helical root acquires a progressive descending direction into the conchae.

Once the helix is incorporated and fixed into the base frame, we mark what will be carved off: The depression for the scapha and triangular fossa are so delineated. The template taken from the contralateral ear will also help us mark and resect the semicircular portion of what will be the conchae depression and if possible the antitragal prominence (Figure 4). Note that at this point the 6th cartilage still extends beyond the margins of what will be the complete framework. This excess is also resected and rounded on its edges. Its

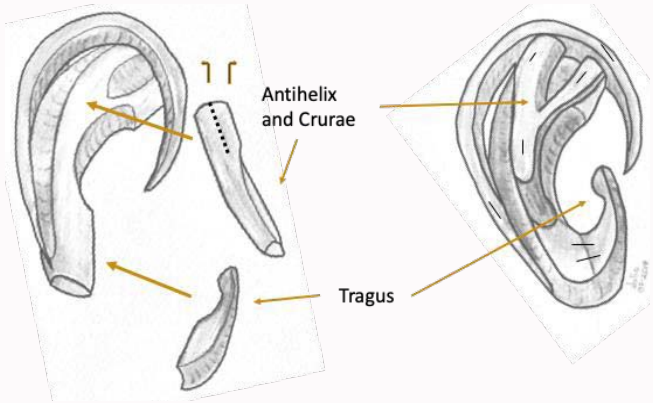

Figure 4: The excess cartilages on both ends of the 6th rib are resected. The portion corresponding to the lobule is lowered, and the onlay grafts corresponding to both crurae, antihelix and tragus are attached.

Figure 5: Immediate postoperative view. The elevated curvature of the 7th rib cartilage produces in some patients an auriculo-temporal sulcus.

portion corresponding to the lobular part of the reconstructed ear is rounded and leveled, so it snugly enters into the lobule (most of the time Firmin's type II incision is used). At this point, the onlay graft that will be placed over the superior and inferior crura, in continuity with the antihelix are also wired on the base, and the navicular fossa between both crurae is made to match the depression previously carved on the base. An asymmetrical incision that leaves the superior crura wider along one border of this graft taking care to also make it taller, will contribute to the anatomical differences between both of them (Figure 5). Finally, the segment fabricated from one of the leftover pieces of cartilage resected from the base frame that will resemble the tragus is also attached. Care is taken to make the depression that will resemble the intertragal notch. Up to this point, the cartilage corresponding to the 8th rib has not been touched. If there is insufficient cartilage to fabricate the tragus, it can be taken from the widest portion of this rib. The remaining portion will be saved subcutaneously below the thoracic incision for elevation of the reconstructed ear in the second stage of reconstruction.

Before introducing the framework into the skin pocket, we place a 10 mm Jackson-Pratt drain that is divided in two halves and brought out through the scalp. Once the wound is closed and suction defines the framework's anatomical details, petrolatum-impregnated gauze is applied over the wound and held in place with gauze and micropore tape.

Discussion

The typical anatomical presentation of the costal cartilages 6th through 8th is with the 6th arch being straighter and shorter but

Figure 6: Clinical appearance after the first stage of auricular reconstruction with the 6th over 7th surgical technique.

often wider than the 7th; this last one describing a longer and more pronounced curvature in its distal portion in order to articulate itself to the sternum. Both of them are united in their mid-portion by a 3 cm to 4 cm synchondrosis (Figure 1). This characteristic allows us to take advantage of the already united cartilages, by doing an incision on the posterior or visceral portion of the synchondrosis that lets the seventh cartilage to be bent over the sixth on the outer surface in a quite sturdy hinge that will form the helix curvature with its proximal portion fixated to the sixth costal cartilage and helical root with its distal third also fixed to the base of the sixth costal cartilage. The proximal third is then used to form the remainder of the helix in its direction toward the antitragus and lobule. This distal portion of the seventh cartilage has to be tailored by reducing its anteroposterior width removing slices from its visceral portion that allows to form a curvature that slowly decreases in size to form the helical root. Since the lower free border of seventh rib also has to be reduced in size, this portion of the cartilage can often be used to form the crura/antihelix complex graft (Figure 2). Only two or three wire sutures are needed to keep the helix in place, and another three to secure the descending portion or the antihelix over the base frame. The free edges of the rib where it was cut off to progressively reduce its diameter toward the helical root are rounded out to resemble the outer surface of the helix.

The advantage that only a small number of wire sutures is required to keep the helical curve in place. Additionally, the skin envelope with its concentrical pull over this structure once the frame is located inside the cutaneous pocket is force that contributes largely to maintain the form. When doing the Nagata technique, keeping both cartilage grafts in place requires the application of multiple wire sutures to maintain the helical graft vertical over the base frame and secure its curvature. The concentrical force exerted by the skin pocket sometimes tends to bend the helix inward, giving it a collapsed appearance. Furthermore, the fact that the upper third of the cartilage is not entirely in contact with the base formed by the sixth rib cartilage works to our advantage, since it produces a depression on the skin envelope that resembles the auriculo-temporal sulcus that although not very deep is prominent enough to allow patients to hold their eye glasses in place even before the second stage of reconstruction (Figure 6).

The layered grafts to produce the stepwise three dimensional appearance of the frame is similar to the framework that Nagata proposed, and the addition of the tragal segment is no different from what Firmin also proposes, sometimes requiring the addition of the P1 proyection graft [11].

In relation to the framework construction, when we occasionally find a firm synchondrosis between the 8th and 7th cartilages, que prefer to build the construct using these two ribs, since the 8th costal cartilage

is much thinner and pliable, making it easier to use it as the helix. Unfortunately, unlike the 6th and 7th synchondrosis which is always present, this is a very inconsistent anatomical finding, and in our series it was taken advantage of in only 25.8% of the cases (16 of the 62 operated until now) (Figure 6).

During the development of this technique, the skin pocket dissection has called our attention in some very important issues: Our surgical results using Nagata's "W" transposition flap for the lobule often gives us an overlapped appearance of the lobule over the framework, instead of a line in continuity of both structures, and sometimes we find it difficult to maintain the "security" subcutaneous pedicle, especially when there is dystopia of anatomical structures. This is the reason we have changed our approach to Firmin's classification of skin incisions, with the transfixion approach or type 2 incisions being the most used. Placement of the frame into the lobule makes the reconstructed ear appear more integrated, keeping the lobule detached from the posterior mastoid skin, which simplifies at the same time the second stage, since a smaller skin graft is required for elevation of the reconstructed ear.

When the cartilage remnants are resected, more often than not the superficial temporal fascia is left with a defect that has to be repaired. Inexperienced surgeons can easily get confused if they start the skin pocket dissection in this area, raising the flap under the superficial temporal fascia which in one hand interferes with the frame's postoperative definition, and on the other makes it impossible during the second stage to give an appropriate coverage on the wedge graft that will keep the frame elevated, if a transposition or advancement flap of the fascia is required.

We continuously remind our residents that the pocket dissection is as important as the framework, for the final surgical result, and great attention has to be given to this point. As other authors suggest, skin undermining is carried out at least 1 cm. beyond the template margin to let the framework enter the space snuggly, and letting the skin redrape over the different anatomical structures of the frame.

Finally, when Firmin's type 2 incisions is employed, the distance between the upper third dissection of the pocket and the free margin of the incision is shorter, and since the elevated flap's circulation is random, viability of the flap is better ensured.

Conclusion

Since the appearance of Nagata's paper on auricular reconstruction with autologous rib cartilage, his framework has become the gold standard on ear reconstruction. Few modifications have appeared overtime with contributions that modify the incisions for the introduction of the framework into the skin envelope, apply cartilage grafts deep to the framework that contribute to better projection, and propose skin expansion previous to the reconstruction. Building the cartilage framework has not suffered major modifications since then, and has been adopted by most surgical teams dedicated to autologous cartilage auricular reconstruction.

We present a different approach to the construction of the framework that basically keeps the natural synchondrosis between the sixth and seventh or seventh and eighth costal cartilages so that one is bent and fixated over the other, producing a curvature that resembles the helix, applying afterward the onlay grafts that will conform both crurae, antihelix, tragus and antitragus.

The main advantages of this technique are:

- A substantial reduction in surgical time.
- The placement of fewer wire fixation loops to the framework's cartilage.
- The formation of a shallow upper third auriculo-temporal sulcus starting from the first stage of reconstruction.
- A natural elevated projection of the helix that obviates the need to apply extra cartilage grafts under the construct.
- Savings in cartilage requirements that make the 9th rib procurement unnecessary.

In relation to the traditional Brent or Nagata's cartilage carving, it is best to delay the first stage of reconstruction until the age of 9 or 10, depending on the patient's body morphism. Mesomorphic patients can usually be operated at earlier ages.

Since the introduction of Firmin's incisions in our practice, we have observed less skin ischemia and cartilage exposure as the main complication of first stage auricular complication.

References

1. Tanzer RC. Total reconstruction of the external ear. Plast Reconstr Surg Transplant Bull. 1959;23(1):1-15.
2. Tanzer RC. Total reconstruction of the auricle. The evolution of a plan of treatment. Plast Reconstr Surg. 1971;47(6):523-33.
3. Brent B. Ear reconstruction with an expansile framework of autogenous rib cartilage. Plast Reconstr Surg. 1974;53(6):619-28.
4. Nagata S, Fukuda O. A new reconstruction for the Lobule-type microtia. Jpn J Plast Reconstr Surg. 1987;7:689.
5. Nagata S. A new method of total reconstruction of the auricle for microtia. Past Reconstr Surg. 1993;92(2):187-201.
6. Nagata S. Modification of the stages in total reconstruction of the auricle: Part I. Grafting the three-dimensional costal cartilage framework for lobule-type microtia. Plast Reconstr Surg. 1994;93(2):221-30.
7. Nagata S. Modification of the stages in total reconstruction of the auricle: Part II. Grafting the three-dimensional costal cartilage framework for concha-type microtia. Plast Reconstr Surg. 1994;93(2):231-42.
8. Nagata S. Modification of the stages in total reconstruction of the auricle: Part III. Grafting the three-dimensional costal cartilage framework for small concha-type microtia. Past Reconstr Surg. 1994;93(2):243-53.
9. Firmin F. Ear reconstruction in cases of typical microtia. Personal experience based on 352 microtic ear corrections. Scand J Past Reconstr Surg Hand Surg 1998;32(1):35-47.
10. Firmin F. Ear reconstruction in the event of microtia. Principles, methods and classification. Auricular reconstruction in cases of microtia. Ann Aesthet Plastic Surg. 2001;46(5):447-66.
11. Firmin F, Marchac A. A novel algorithm for autologous ear reconstruction. Semin Plast Surg. 2011;25(4):257-64.
12. Zhang Q, Quan Y, Yuanda S, Chi L, Xi Y, Liu X. Expanded retroauricular skin and fascial flap in congenital microtia reconstruction. Ann Plast Surg. 2010;64(4):428-34.
13. Kawanabe Y, Nagata S. A new method of costal cartilage harvest for total auricular reconstruction: Part I. Avoidance and prevention of intraoperative and postoperative complications and problems. Plast Reconstr Surg. 2006;117(6):211-8.