



A Case Report on Haloperidol Induced Hepatotoxicity

Satya Kumar Dutta, Pranjal Jyoti Chakravarty* and Ankur Jyoti Borah

Department of Psychiatry, Lokopriya Gopinath Bordoloi Regional Institute of Mental Health, India

Abstract

A 45 year old male presented with psychotic symptoms for 5 years. Patient was started on Haloperidol starting with 5 mg and increasing up to 20 mg over 3 weeks. There was symptomatic improvement of his psychotic symptoms, but in the 3rd week patient presented with jaundice, poor appetite, and yellowish discoloration of urine. On liver function test elevated AST, ALT, GGT, ALP and bilirubin were noted. At this point, patient was on Tablet Haloperidol 15 mg and Tablet Trihexyphenidyl 2 mg. Patient had no diagnosis of chronic liver disease in the past, baseline LFT was within normal limit. In Drug Induced Liver Injury (DILI) Roussel Uclaf Causality Assessment Method (RUCAM) is a means of assigning points for clinical, biochemical, serologic and radio-logic features of liver injury which gives an overall assessment score that reflects the likelihood of injury is due to a drug.

Keywords: Haloperidol; Hepatotoxicity; RUCAM

Introduction

Drug Induced Liver Injury (DILI) is a common drug reaction that may lead to acute liver injury ranging in severity from mild, asymptomatic elevations in liver biochemistry to acute liver failure resulting in death or liver transplantation [1]. Liver is the major organ responsible for concentrating and metabolizing a majority of medications, therefore, it is a prime target for medication-induced damage.

Many pharmacological agents can cause liver damage, including anesthetics, anticancer drugs, antibiotics, antituberculosis agents, antiretrovirals etc. In addition, a range of traditional and herbal remedies may also be hepatotoxic. Depending on the duration of injury and the histological location of damage, Drug-Induced Liver Injury (DILI) is categorized as acute or chronic, and either as hepatitis, cholestatic, or a mixed pattern of injury [1].

We present here a case of hepatotoxicity associated with Haloperidol use. Haloperidol is a psychotropic drug of the Butyrophenone family. Haloperidol as a first generation antipsychotic has the potential to cause the Extra Pyramidal Symptoms (EPS), which includes a group of movement disorders of dystonia, akathisia, tardive dyskinesia and Parkinsonism. Antipsychotic drug induced EPS is caused by the blockage of central dopamine D₂ receptors.

Apart from such common side effects, antipsychotics are also known to cause asymptomatic alterations of liver function. Liver injury of the hepatic (Aspartate Aminotransferase (AST), Alanine Aminotransferase (ALT), or Glutamate Dehydrogenase (GDH) elevations) or the cholestatic (Alkaline Phosphatase (ALP) and bilirubin elevations) type have both been described. Serious liver cell damage is well examined and described in Chlorpromazine treatment, occurring in approximately 1% of the patients.

Cholestatic icterus was described frequently (1% to 10%) with Chlorpromazine treatment and rarely with perphenazine, promazine, thioridazine, trifluoperazine, triflupromazine, and tiotixene treatment. The incidence is even lower under fluoridated phenothiazine such as fluphenazine or butyrophenones such as haloperidol. Here, cholestatic icterus may be accompanied by eosinophilia. Most authors agree that elevations of liver enzymes in neuroleptic treatment are a benign phenomenon, usually not requiring discontinuation of therapy. Therefore, further monitoring while continuing drug therapy is recommended if transaminases do not exceed a limit of 100 U/L [2].

Case Presentation

A 45 year old male presented with psychotic symptoms with total duration of illness of 5 years with poor compliance to medications. Upon admission, following diagnosis of paranoid schizophrenia, patient was started initially on Olanzapine. Following adequate trial, with no improvement in symptoms Risperidone done was tried but poor response to it too.

OPEN ACCESS

*Correspondence:

Pranjal Jyoti Chakravarty, Department of Psychiatry, Lokopriya Gopinath Bordoloi Regional Institute of Mental Health, Tezpur, 784001, Assam, India, Tel: +91-9365533182;

E-mail: pranjaljc@gmail.com

Received Date: 21 Apr 2020

Accepted Date: 08 May 2020

Published Date: 12 May 2020

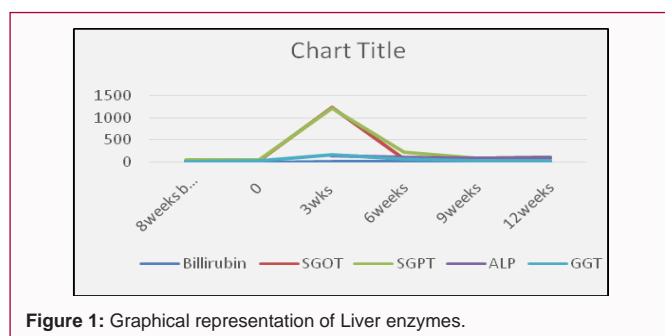
Citation:

Dutta SK, Chakravarty PJ, Borah AJ. A Case Report on Haloperidol Induced Hepatotoxicity. *Ann Psychiatr Clin Neurosci.* 2020; 3(1): 1027.

Copyright © 2020 Pranjal Jyoti Chakravarty. This is an open access article distributed under the Creative Commons Attribution License, which permits unrestricted use, distribution, and reproduction in any medium, provided the original work is properly cited.

Table 1: Dose of medications with chronological liver function test values.

Time	Billirubin	SGOT	SGPT	ALP	GGT	haloperidol	THP
8 weeks before Haloperidol started	0.3	30	45	84	19		
0	0.2	34	49	91	23	5 mg	2 mg
3 weeks	6	1230	1221	147	162	20 mg	2 mg
3 weeks 2 days	7.6	1076	1166	153	143	Withdrawn	Withdrawn
5 weeks	9.6	71	231	112	72	None	None
8 weeks	2.1	84	82	84	36	Restart	
9 weeks	1.5	79	93	82	35	10 mg	2 mg
10 weeks	2.2	94	106	97	36	10 mg	2 mg
11 weeks	2.3	94	113	99	39	15 mg	2 mg
Next day						withdrawn	withdrawn

**Figure 1:** Graphical representation of Liver enzymes.

Patient was started on Haloperidol starting with 5 mg and increasing up to 20 mg over a period of 3 weeks. There was symptomatic improvement of his psychotic symptoms, but in the third week patient presented with jaundice, poor appetite, and yellowish discoloration of urine. On liver function test elevated AST, ALT, GGT, ALP and bilirubin were noted. At this point, patient was on Tablet Haloperidol 15 mg and Tablet Trihexyphenidyl 2 mg. Patient had no diagnosis of chronic liver disease in the past, baseline Liver Function Test (LFT) (Table 1) was within normal limit. All his medications withdrawn over next 3 weeks and his LFT returned to normal, but during this period his psychotic symptoms again aggravated and at times was unmanageable in the ward. Owing to his good response to Haloperidol and poor response to both Olanzapine and Risperidone, patient was again started on Tablet Haloperidol, starting with 5 mg and increasing up to 10 mg over 2 weeks. Over next 2 weeks his LFT was estimated weekly, towards end of 2nd week, his hepatic enzymes again started to rise forcing to stop Haloperidol, subsequently he was started on Tablet Aripiprazole and currently he is doing better.

In Drug Induced Liver Injury (DILI) Roussel Uclaf Causality Assessment Method (RUCAM) is a means of assigning points for clinical, biochemical, serologic and radio-logic features of liver injury which gives an overall assessment score that reflects the likelihood that the hepatic injury is due to a specific medication. Introduced in 1993, RUCAM is now widely used in assessing causality of drug induced liver injury, both in the published literature and in support of regulatory decisions regarding medications implicated in causing hepatic injury [3]. Applying RUCAM in our patient, total score came out to be 7, (0 or less indicate that the drug is “excluded” as a cause; 1 to 2 that it is “unlikely”; 3 to 5 “possible”; 6 to 8 “probable”; and greater than 8, “highly probable”) which suggests Haloperidol as the probable cause for deranged Liver function in our patient (Table 1).

Discussion

Mr. A had presented with clinical jaundice three weeks after Haloperidol was started. Any neuroleptic including haloperidol is known to cause asymptomatic alterations in liver function. Liver injury of the hepatic Aspartate Aminotransferase (AST), Alanine Aminotransferase (ALT), or Glutamate Dehydrogenase (GDH) elevations) or the cholestatic Alkaline Phosphatase (ALP) and bilirubin elevations) type have both been described. GLDH is present in the liver cell mitochondria, and its elevation in the blood is quite specific for liver cell damage. Serious liver cell damage is well examined and described in Chlorpromazine treatment, occurring in approximately 1% of the patients. Incidence of such hepatic damage is very low with antipsychotics like Haloperidol, although few case reports have been published. In most cases it has been suggested that such elevation of liver enzymes is a benign phenomenon so that discontinuation of antipsychotic is rarely required with careful monitoring until transaminases exceed level of 100 U/L (Figure 1).

Einar put an effort to categorize medications based on their potentials to cause hepatic injury. This categorization is based on published case reports of individual drugs, with five categories (category A, 50; category B, 12-49; category C, 4-11; category D, 1-3; category E, none). Haloperidol comes under category B with 25 case reports till May, 2015 out of which there were no fatalities or in none of the cases re-challenge was done [4].

In a case reported by Fuller et al. patient with diagnosis of schizophrenia had presented with symptoms of anorexia, nausea, vomiting, lethargy, fever and lower extremity rash 5 weeks after initiation of Haloperidol. His total bilirubin, 4.2 mg per 100 ml; SGOT 100 IU per liter; and SGPT, 130 IU per liter. Following Haloperidol discontinuation, on examination a general red erythematous macular rash over the lower extremities and palms. On examination of the abdomen, mild right upper quadrant tenderness was noted, but no liver or splenic enlargement. On liver biopsy, pathological impression was that the changes represented a hypersensitivity reaction, predominantly cholestatic, but also hepatocellular. All symptoms resolved after few weeks and liver function test returned to normal [5].

In another case Fuller et al. described a 27 year old female presented with jaundice after four weeks of initiation of Haloperidol at a dose of 15 mg to 20 mg. After detailed evaluation drug Haloperidol induced intra hepatic cholestasis was diagnosed. After four weeks of discontinuation of Haloperidol her liver function test returned to normal [5].

In another case Dincsoy and Saelinger had reported in a 15 year old male malaise, fever, jaundice, generalized pruritus, vague abdominal pain, and dark urine after 4 weeks of initiation of Haloperidol. Combination of hepatic dysfunction with jaundice and eosinophilia developing 4 weeks after administration of haloperidol and benztropine messy late in this patient was highly suggestive of a drug-induced hypersensitivity reaction [6].

In our case symptoms started after 3 weeks of initiation of Haloperidol which matches with the latent period described in previous case reports. Also reduction in hepatic enzymes within 3 weeks following discontinuation of Haloperidol is similar to previous case reports. Unique feature in our case is the upward trend of hepatic enzymes within 1 week following re-challenge, although continuation beyond that period is ethically unjustifiable, because of which re-challenge up-to previous dose and duration could not be achieved. Still, signs of positive re-challenge with objective evidence by RUCAM is sufficient to consider Haloperidol as the causative agent for deranged liver function test in our patient.

References

1. Hamilton LA, Collins-Yoder A, Collins RE. Drug-induced liver injury. AACN Adv Crit Care. 2016;27(4):430-40.
2. Gaertner I, Altendorf K, Batra A, Gaertner HJ. Relevance of liver enzyme elevations with four different neuroleptics: A retrospective review of 7,263 treatment courses. J Clin Psychopharmacol. 2001;21(2):215-22.
3. Rockey DC, Seeff LB, Rochon J, Freston J, Chalasani N, Bonacini M, et al. Causality assessment in drug-induced liver injury using a structured expert opinion process: Comparison to the Roussel-Uclaf causality assessment method. Hepatology. 2010;51(6):2117-26.
4. Björnsson ES, Hoofnagle JH. Categorization of drugs implicated in causing liver injury: Critical assessment based on published case reports. Hepatology. 2016;63(2):590-603.
5. Fuller CM, Yassinger S, Donlon P, Imperato TJ, Ruebner B. Haloperidol induced liver disease. West J Med. 1977;127(6):515-8.
6. Dincsoy HP, Rolfes DB, McGraw CA, Schubert WK. Cholesterol ester storage disease and mesenteric lipodystrophy. Am J Clin Pathol. 1984;81(2):263-9.