



Complete Healing of Venous Leg Ulcer using a Collagen based Dressing a Case Report

Dumont Isabelle^{1#}, Caillava Celine^{2#}, Dupouiron Stephanie², Guillemin Yannis^{2###} and Gouze Jean Noel^{2###}

¹Department of Foot and Ankle Surgery, Center of the Foot Ransart, Belgium

²Department of Research and Development, Genbiotech, France

[#]Dumont Isabelle and Caillava Celine Contributed Equally to this Work

^{###}Guillemin Yannis and Gouze Jean Noel are Co-senior Authors

Abstract

Venous Leg Ulceration (VLU) is a common pathology which affects patients at any age. Ulcers are characterized by long-term healing, pain and frequent recurrence despite adherence to standard of care resulting in time consuming and costly treatments. Here, the authors describe the case of a diabetic, 63 years old male suffering from venous insufficiency and presenting a distal leg ulcer. The ulcer was treated using GBT013 device, a new biocompatible and biodegradable tri-dimensional collagen based matrix. GBT013 seems to be well integrated to the healing tissues and well tolerated. No complication or pain was reported during treatment. Complete healing was obtained within 36 days with no recurrence to date despite a context of stasis dermatitis.

Keywords: Venous leg ulcer; Collagen dressing; Tri-dimensional matrix; Wound healing

Abbreviations

DFU: Diabetic Foot Ulcer; VLU: Venous Leg Ulcer

Introduction

Venous Leg Ulcers (VLUs) are open lesions of the lower extremities caused by venous disease. Risk factors include all factors susceptible to increase pressure within vessels (e.g., obesity, immobility, thrombosis, varicose veins, and trauma) [1-3]. They are more common in women and older people and represent 60% to 80% of leg ulcers [4-7]. VLUs are often chronic and can persist for months, representing a significant health care burden [8-10]. Symptoms include pain, itching and swelling. Most VLUs can heal within 20 to 24 weeks using adapted dressing coupled or not with different treatments such as leg elevation, compression therapy, anti-coagulant and/or vaso-active agents or surgical management [11,12]. Although a wide range of different dressings are commercially available (i.e. hydrocolloids, foams, hydrogels, pastes, simple non-adherent dressings) no significant difference in term of efficacy has been reported [13,14]. GBT013 is a new biocompatible and biodegradable tri-dimensional collagen based matrix, allowing cell colonization and proliferation. Collagen serves as a decoy for Matrix Metallo Proteinases (MMP) found in excess in chronic wounds [15,16]. The safety and efficacy of this cost effective dressing have been recently evaluated in patients with Diabetic Foot Ulcers (DFU) [17]. We are reporting here, the successful use of GBT013 for the complete and long term healing of VLU in a diabetic patient with VLU history.

Materials and Methods

Materials: GBT013 (Genbiotech, Antibes, France) is a CE mark (#0143219-08) class III medical device consisting in a micro porous collagen based dressing. Composition of this tri-dimensional matrix includes equine type I collagen (72%), squid chitosan (20%) and bovine/porcine chondroitin sulfate (8%).

Methods: The case study was conducted from May to June 2013 in Ransart Foot Center (Belgium). The patient was informed about the product and has accepted the treatment. GBT013 has to be cut off to fit the wound size, rehydrated with sterile saline solution and applied directly to the wound bed (Figure 1). Secondary dressing and renewal was left to the practitioner's discretion

OPEN ACCESS

*Correspondence:

Gouze Jean Noel, Department of Research and Development, Genbiotech, 280 rue de Goa, Antibes, 06600, France;

E-mail: jngouze@genbiotech.com

Received Date: 13 Jun 2018

Accepted Date: 26 Jul 2018

Published Date: 30 Jul 2018

Citation:

Isabelle D, Celine C, Stephanie D, Yannis G, Noel GJ. Complete Healing of Venous Leg Ulcer using a Collagen based Dressing a Case Report. *J Surg Tech Proced.* 2018; 2(2): 1017.

Copyright © 2018 Gouze Jean Noel. This is an open access article distributed under the Creative Commons Attribution License, which permits unrestricted use, distribution, and reproduction in any medium, provided the original work is properly cited.




Figure 1: Recommendations for GBT013 Use. (A) GBT013 is a sterile collagen based dressing presented in a sterile plastic blister. (B) Hydration of GBT013 is performed directly in the plastic blister with saline solution. (C). GBT013 is ready to use 5 minutes after hydration and can be applied directly to the wound bed using sterile forceps.

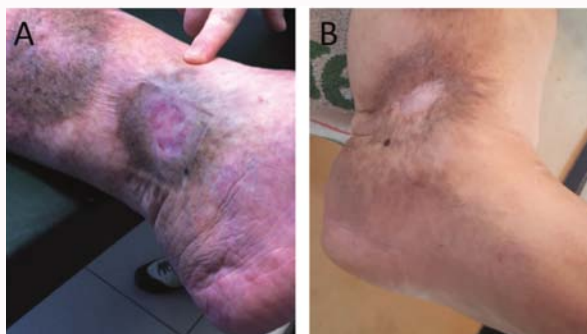


Figure 2: VLU wound healing progress following treatment with GBT013 device. (A) Fibrinous ulcer with scalloped edges measuring 10 cm² before any GBT013 application. No edema and no sign of discharge are observed. (B) Scar of the GBT013 cured ulcer surrounded by sequela of stasis dermatitis. This ulcer has never recurred.

and was applied over GBT013. GBT013 application rate was also left to practitioner's appraisal once per week to once every two weeks. Wound closure had to be measured at each follow-up visit with report of infection, duration and percentage of wound closure.

Results

Case Presentation: The patient was a very severely obese (body mass index at 40.5), non-smoker 63 years old male with a history of type II diabetes and venous insufficiency since 2000. He presented no arterial insufficiency but has been treated for several venous ulcers and diabetic foot ulcers with or without osteitis (toes, forefoot and ankle). Some wounds were medically treated and healed while others needed amputation of the first and second left toes. The patient also presented stasis dermatitis on both limbs. He has undergone a saphenectomy of the left internal saphenous vein in 2010 and the right internal saphenous vein was not continent. Antecedents consisted of arterial hypertension, type II hyperlipemia according to Fredrikson classification, retinopathy, nephropathy, neuropathy resulting from diabetic complications, chronic renal insufficiency due to lithiasis and gout, allergy to penicillin and sleep apnea syndrome.

Treatment: Metformine (850 mg, 3/d), Novomix (2 Inj 1/d), Bisoprolol (10 mg/d), Amlodipine (10 mg/d), Moxonidine (0.4 mg 2/d), Lisinopril (40 mg/d), Asaflow (80 mg/d), Indapamide (2/d) and Allopurinol (300 mg 1/d).

Observation: On examination, the pedal is and tibialis posterior pulses were palpable. A 10 cm² and 0.5 cm deep ulcer was measured, located above the malleola on the left internal side of the left ankle lasting for more than 3 months (Figure 2A). Macroscopically, the wound was clean, slightly fibrinous with scalloped edges. No infection, no maceration, no necrotic tissue nor exposed structures were noted and no pain associated to the wound was reported. On day

one, the ulcer was sharply debrided with curettage and cleaned with normal saline. GBT013 was cut off to fit the wound size, rehydrated with sterile saline solution, and applied directly to the wound bed. GBT013 porous matrix remained easily handled even after hydration (Figure 1). It was found to adhere properly to the wound bed and did not require any operating room and/or staples. Secondary dressing was applied over GBT013 to maintain a moist and compressive environment to optimize wound healing. The secondary dressing used was as follows: Curity Kendall (Covidien, Dublin, Ireland), Stellaline (Lohmann & Rausher) and profore compressive stocking (Smith & Nephew, London, England). As the patient was not suffering from arterial insufficiency, no control of ankle brachial index was necessary before giving the patient a compressive stocking. Secondary dressing was changed daily and the GBT013 treatment was applied every two weeks with 3 final superimposed applications *i.e.*, on days 0, 14 and 28. Before each new GBT013 application, the wound was cleaned with saline with removal of any fibrinous and other non-healthy tissues. On day 11, 80% of the wound was closed and granulation tissue was in place. Complete healing was observed within 36 days with no infection nor maceration signs noted along the process. As neither complication nor pain was reported, GBT013 seems to be both well integrated to the healing tissues and well tolerated. Four years after treatment, in a context of stasis dermatitis, it is of particular interest to note that no recurrence was observed (Figure 2B).

Discussion

VLU is a painful, incapacitating affection presenting a healing duration longer than six weeks and which is prone to frequent recurrence [8,9]. Regarding patient concern and health care burden, reducing leg ulcer recurrence is hence a relevant issue recognized in international leg ulcer management guidelines [12,18]. The main objective of this clinical case was to present VLU treatment with

GBT013, a new collagen engineered skin substitute which the use was previously described in DFU [17]. Regarding the clinical case presently reported treatment with GBT013 resulted not only in well-tolerated, efficient and cost-effective wound healing but was also very satisfactory as no recurrence was observed four years after initial treatment despite the long VLU history of the patient. Obviously, a larger cohort analysis will be needed to assess GBT013 efficiency in VLU treatment. However, as previously reported regarding DFU treatment, clinicians appreciated the ease of use of this new porous matrix that adheres properly to the wound bed and does not require an operating room and/or staples. Another advantage is that GBT013 is left in place throughout the wound healing and layered if further applications are needed. Consequently, this dramatically minimizes interferences with the wound and infectious risks thus accelerating the healing process. Moreover, as patients commonly express pain during dressing change, simplifying handling is of great importance. On the other hand, when conducting nursing at home, it could be problematic to ensure that only the secondary dressing would be taken off and not the primary one. As nurses usually take all the dressings off to clean the wound, they probably have to be educated to the use of this new kind of dressing. This first GBT013 clinical case in VLU treatment completes its clinical use previously described in DFU and pre-clinical evidences of its efficacy [17,19]. As GBT013 seems to result in well-tolerated and efficient healing, its use could represent improvement in patients' welfare but also simplify practitioner's practice decreasing the global cost of VLU care. Thus, these results open interesting perspectives to the design of a randomized and controlled clinical trial in VLU patients.

Acknowledgement

CC, SD, YG and JNG would like to thank Coralie Segalen for her contribution to the project.

References

1. Criqui MH, Jamosmos M, Fronek A, Denenberg JO, Langer RD, Bergan J, et al. Chronic venous disease in an ethnically diverse population: the San Diego Population Study. *Am J Epidemiol*. 2003;158(5):448-56.
2. Scott TE, LaMorte WW, Gorin DR, Menzoian JO. Risk factors for chronic venous insufficiency: a dual case-control study. *J Vasc Surg*. 1995;22(5):622-8.
3. Tuchsén F, Hannerz H, Burr H, Krause N. Prolonged standing at work and hospitalisation due to varicose veins: a 12 year prospective study of the Danish population. *Occup Environ Med*. 2005;62(12):847-50.
4. Beebe-Dimmer JL, Pfeifer JR, Engle JS, Schottenfeld D. The epidemiology of chronic venous insufficiency and varicose veins. *Ann Epidemiol*. 2005;15(3):175-84.
5. Carpentier PH, Maricq HR, Biro C, Poncot-Makinen CO, Franco A. Prevalence, risk factors, and clinical patterns of chronic venous disorders of lower limbs: a population-based study in France. *J Vasc Surg*. 2004;40(4):650-9.
6. Tang JC, Vivas A, Rey A, Kirsner RS, Romanelli P. Atypical ulcers: wound biopsy results from a university wound pathology service. *Ostomy Wound Manage*. 2012;58(6):20-9.
7. Tendera M, Aboyans V, Bartelink ML, Baumgartner I, Clement D, Collet JP, et al. ESC Guidelines on the diagnosis and treatment of peripheral artery diseases: Document covering atherosclerotic disease of extracranial carotid and vertebral, mesenteric, renal, upper and lower extremity arteries: the Task Force on the Diagnosis and Treatment of Peripheral Artery Diseases of the European Society of Cardiology (ESC). *Eur Heart J*. 2011;32(22):2851-906.
8. Falanga V. Care of venous leg ulcers. *Ostomy Wound Manage*. 1999;45(1A):33S-43S.
9. Hansson C, Andersson E, Swanbeck G. A follow-up study of leg and foot ulcer patients. *Acta Derm Venereol*. 1987;67(6):496-500.
10. Olin JW, Beusterien KM, Childs MB, Seavey C, McHugh L, Griffiths RI. Medical costs of treating venous stasis ulcers: evidence from a retrospective cohort study. *Vasc Med*. 1999;4(1):1-7.
11. Collins L, Seraj S. Diagnosis and treatment of venous ulcers. *American family physician*. 2010;81(8):989.
12. Sinha S, Sreedharan S. Management of venous leg ulcers in general practice - a practical guideline. *Aust Fam Physician*. 2014;43(9):594-8.
13. Norman G, Dumville JC, Westby MJ, Stubbs N, Soares MO. Dressings and topical agents for treating venous leg ulcers. *Cochrane Database Syst Rev*. 2017.
14. Palfreyman S, Nelson EA, Michaels JA. Dressings for venous leg ulcers: systematic review and meta-analysis. *BMJ*. 2007;335(7613):244.
15. Li Z, Guo S, Yao F, Zhang Y, Li T. Increased ratio of serum matrix metalloproteinase-9 against TIMP-1 predicts poor wound healing in diabetic foot ulcers. *J Diabetes Complications*. 2013;27(4):380-2.
16. Yang C, Zhu P, Yan L, Chen L, Meng R, Lao G. Dynamic changes in matrix metalloproteinase 9 and tissue inhibitor of metalloproteinase 1 levels during wound healing in diabetic rats. *J Am Podiatr Med Assoc*. 2009;99(6):489-96.
17. Dumont I, Lepeut M, Segalen C, Guillemin Y, Gouze JN. Use of GBT013, a collagen-based dressing, for the healing of diabetic foot ulcers: a case series. *J Am Podiatr Med Assoc*. 2018.
18. Franks PJ, Barker J, Collier M, Gethin G, Haesler E, Jawien A, et al. Management of Patients With Venous Leg Ulcers: Challenges and Current Best Practice. *J wound care*. 2016;25(6):S1-67.
19. Guillemin Y, Le Broc D, Segalen C, Kurkdjian E, Gouze JN. Efficacy of a collagen-based dressing in an animal model of delayed wound healing. *J wound care*. 2016;25(7):406-13.