



Endoballoon Occlusion Catheter Insertion through the Left Subclavian Artery

Sana Rahman and Atiq Rehman*

Tran Catheter Valve Therapy, Lourdes Medical Center, USA

Clinical Image

A 68-year-old gentleman with history of coronary artery bypass and aortic valve surgery had progressive dyspnea affecting lifestyle. Cardiac catheterization revealed patent right internal mammary artery to right coronary artery graft, travelling beneath sternum. Echocardiography revealed functional aortic prosthesis and severe mitral regurgitation; thus mitral repair was planned. Lower extremity could not be used because computerized tomographic angiography of lower extremity revealed extensive calcification. Endoballoon aortic occlusion through femoral artery has been reported [1]; left subclavian artery approach was considered because of peripheral vascular disease. Left subclavian artery exposed and distal end of 60 cm/10 mm HEMASHIELD graft (Maquet, Wayne, NJ) was anastomose to subclavian artery intend to side manner (Figure 1). Endoballoon occlusion catheter was inserted through 21Fr inflow sheath which was inserted in proximal end of graft. Cardiac arrest was obtained and mitral valve repair completed. Once off bypass, endoballoon occlusion catheter was retrieved, graft was divided just above subclavian artery with endostapler device.

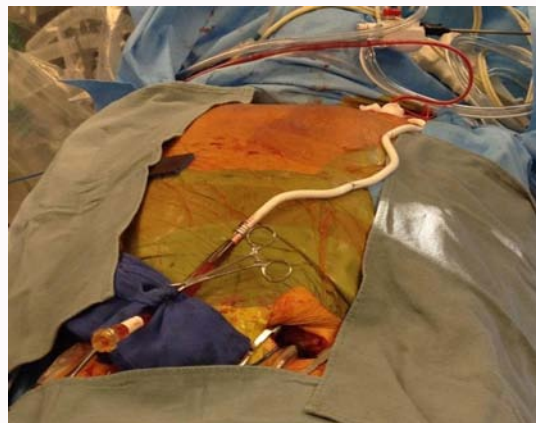


Figure 1: Endoballoon occlusion catheter inserted in left subclavian artery through a 60 cm HEMASHIELD graft.

OPEN ACCESS

*Correspondence:

Atiq Rehman, Trans Catheter Valve Therapy, Lourdes Medical Center, 1600 Haddon Ave, Camden, NJ 08103, USA, Tel: 609-304-8397; Fax: 856-668-8815;

E-mail: atiqmd@aol.com

Received Date: 15 Jul 2017

Accepted Date: 02 Aug 2017

Published Date: 12 Aug 2017

Citation:

Rahman S, Rehman A. Endoballoon Occlusion Catheter Insertion through the Left Subclavian Artery. *J Surg Tech Proced.* 2017; 1(2): 1006.

Copyright © 2017 Atiq Rehman. This is an open access article distributed under the Creative Commons Attribution License, which permits unrestricted use, distribution, and reproduction in any medium, provided the original work is properly cited.

References

1. Ward AF, Loulmet DF, Neuburger PJ, Grossi EA. Outcomes of peripheral perfusion with balloon aortic clamping for totally endoscopic robotic mitral valve repair. *J Thorac Cardiovasc Surg.* 2014;148(6):2769-72.