



Novel Use of Fan Retractor in Minimally Invasive Mitral Valve Surgery

Sana Rahman and Atiq Rehman*

Tran Catheter Valve Therapy, Lourdes Medical Center, USA

Clinical Image

Fan Retractor (V. Mueller- BD, Franklin Lakes, NJ) has been shown to cause cardiac complication during Laparoscopic Nissen Fundoplication [1]. We present patient where this retractor facilitated cardiac surgery. A 54-year-old male with no significant past medical history, experienced increasing dyspnea over last six months. He was active and worked as delivery person. During his work up, heart murmur led to further investigation which demonstrated prolapse of posterior mitral leaflet and severe mitral regurgitation on echocardiography. He opted for mitral valve surgery through right minithoracotomy (Figure 1 and 2). Once minithoracotomy was performed, right hepatic lobe was observed herniating from medial aspect of diaphragm, obstructing view to pericardium. A 34 cm Fan Retractor (V. Mueller- Becton Dickinson, Franklin Lakes, NJ) was inserted through right sub costal port and retracted herniating hepatic lobe inferiorly. Adequate exposure of pericardium led to successful mitral valve repair and retractor was removed at operation's completion. There was no trauma to herniated lobe.

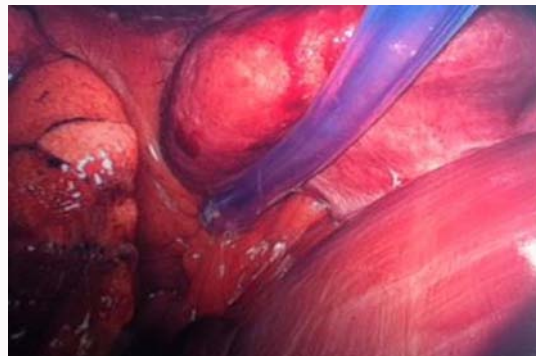


Figure 1: Herniating right hepatic lobe obstructing pericardial exposure through a right minithoracotomy.

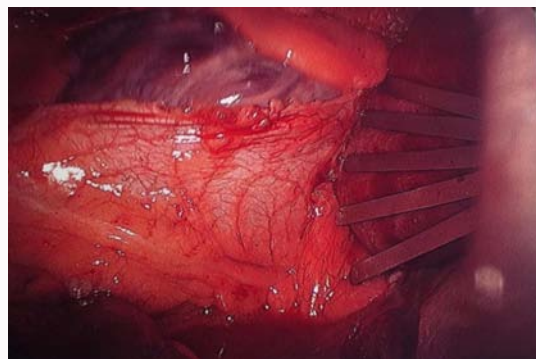


Figure 2: Fan retractor facilitating pericardial exposure.

OPEN ACCESS

*Correspondence:

Atiq Rehman, Trans Catheter Valve Therapy, Lourdes Medical Center, 1600 Haddon Ave, Camden, NJ 08103, USA, Tel: 609-304-8397; Fax: 856-668-8815; E-mail: atiqmd@aol.com

Received Date: 15 Jul 2017

Accepted Date: 02 Aug 2017

Published Date: 12 Aug 2017

Citation:

Rahman S, Rehman A. Novel Use of Fan Retractor in Minimally Invasive Mitral Valve Surgery. *J Surg Tech Proced.* 2017; 1(1): 1005.

Copyright © 2017 Atiq Rehman. This is an open access article distributed under the Creative Commons Attribution License, which permits unrestricted use, distribution, and reproduction in any medium, provided the original work is properly cited.

References

1. Firoozmand E, Ritter M, Cohen R, Peters J. Ventricular laceration and cardiac tamponade during laparoscopic Nissen fundoplication, *Surg Laparosc Endosc.* 1996;6(5):394-7.