



A 37-Year-Old Woman Presented with Sudden Left-Sided Limbs Involuntary Movements

H Wang^{1*}, Y Wang², Z Qi³, W Zhao¹ and Q Cui¹

¹Department of Neurology, The Affiliated Hospital of Chifeng University, China

²Department of Oncology, The Affiliated Hospital of Chifeng University, China

³Department of Radiology, The Affiliated Hospital of Chifeng University, China

Keywords

Involuntary movements; Streptolysin-O; Sydenham's chorea; Penicillin

Clinical Image

A 37-year-old woman with a history of hypertension presented with left-sided limbs involuntary movements. Neurologic examination was unremarkable. Brain MRI revealed signal hyperintensities in the right putamen (Figure 1A and 1C), the right caudate nucleus (Figure 1B and 1D). Electrocardiogram, neck ultrasound, and MRA of the brain are normal (Figure 2). Initial laboratory studies were unremarkable, except anti streptolysin-O (ASO) was positive at 351 U/ml (normal range 0-200 U/ml), serum IgG 16.9 g/L (normal range 7-16 g/L), antinuclear antibodies(ANA) titre 1:160 (normal range <1:100). Sydenham's chorea [1,2] was diagnosed, and intravenous antibiotic

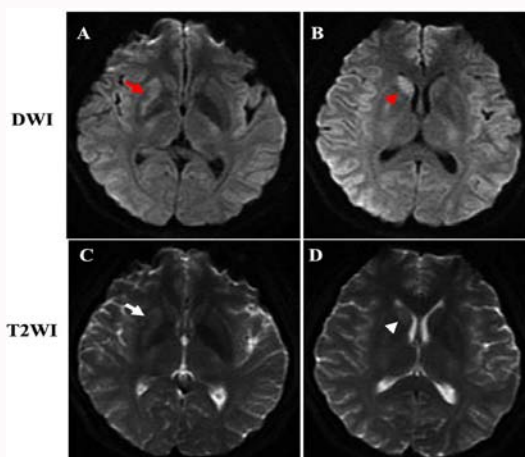


Figure 1: A brain diffusion-weighted image revealed signal hyperintensities in the right putamen (A, red arrow), the right caudate nucleus (B, red arrowhead). Brain MRI revealed abnormal signal hyperintensities on T2-weighted images in right putamen (C, white arrow), the right caudate nucleus (D, white arrowhead).

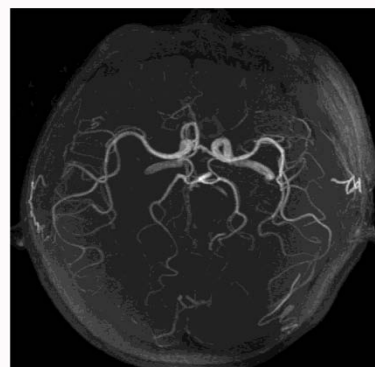


Figure 2: MRA of the brain.

OPEN ACCESS

*Correspondence:

H Wang, Department of Neurology, The Affiliated Hospital of Chifeng University, Chifeng 024005, Inner Mongolia, PR China, Tel: 86 476 5973691; E-mail: whongquan@alu.fudan.edu.cn

Received Date: 19 Jul 2016

Accepted Date: 28 Jul 2016

Published Date: 05 Aug 2016

Citation:

H Wang, Y Wang, Z Qi, W Zhao, Q Cui. A 37-Year-Old Woman Presented with Sudden Left-Sided Limbs Involuntary Movements. *J Neurol Neurosurg Spine*. 2016; 1(1): 1001.

Copyright © 2016 H Wang. This is an open access article distributed under the Creative Commons Attribution License, which permits unrestricted use, distribution, and reproduction in any medium, provided the original work is properly cited.

treatment was started with penicillin. She was discharged without left-sided involuntary movements.

References

1. KG Walker, Wilmschurst JM. An update on the treatment of Sydenham's chorea: the evidence for established and evolving interventions. *Ther Adv Neurol Disord.* 2010; 3: 301-309.
2. Gimeno H, Barry S, Lin JP, A Gordon. Functional impact of Sydenham's chorea: a case report. 2013; 3.