



Severe Adynamic Colonic Ileus

Adil Mir^{1*}, Parth Parekh² and Paul Yeaton²

¹Department of Internal Medicine, Carilion Clinic, USA

²Department of Gastroenterology, Carilion Clinic, USA

Keywords

Abdominal distension; Colonic dilation; Hypokalemia

Clinical Image

An 88 year old female with past history of dementia, chronic diastolic congestive heart failure and hypothyroidism presented with obstipation, nausea (no vomiting), abdominal pain and distension for 2 days. Physical examination revealed abdominal distension, no rebound tenderness with very sluggish bowel sounds. Labs were unremarkable except for severe hypokalemia (serum potassium level 2.5 mmol/liter). Computed tomography of the abdomen showed severe dilation of the entire colon consistent with adynamic colonic ileus, no evidence of mechanical bowel obstruction or volvulus (Figure 1 and 2). Due to severe symptoms, the patient underwent endoscopic decompression via a rectal tube along with the correction of hypokalemia [1]. Following this, the patient's pain, nausea and abdominal distension resolved.

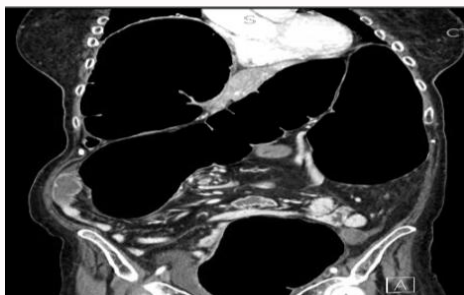


Figure 1: Coronal plane.

OPEN ACCESS

*Correspondence:

Adil Mir, Department of Internal
Medicine, Carilion Roanoke
Memorial Hospital, Virginia, USA, Tel:
3016406349;

E-mail: dr.adilshamim@gmail.com

Received Date: 21 Sep 2018

Accepted Date: 02 Oct 2018

Published Date: 04 Oct 2018

Citation:

Mir A, Parekh P, Yeaton P. Severe
Adynamic Colonic Ileus. *J Gastroenterol
Hepatol Endosc.* 2018; 3(3): 1046.

Copyright © 2018 Adil Mir. This is an
open access article distributed under
the Creative Commons Attribution
License, which permits unrestricted
use, distribution, and reproduction in
any medium, provided the original work
is properly cited.

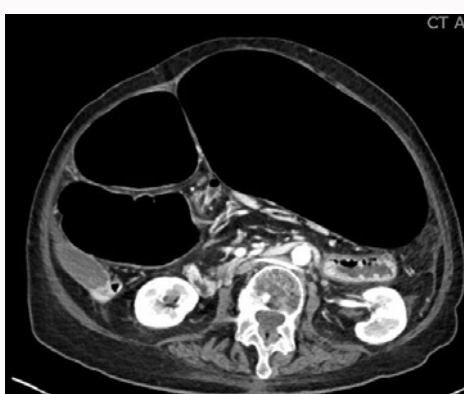


Figure 2: Transverse plane.

References

1. Ben Ameer H, Boujelbene S, Beyrouti MI. [Treatment of acute colonic pseudo-obstruction (Ogilvie's Syndrome). Systematic review]. *Tunis Med.* 2013;91(10):565-72.