



Refractory Left Sided Ulcerative Colitis – Rescue Treatment with Vedolizumab

Riehl S¹ and Dauer M^{2,3*}

¹Kliniken St. Elisabeth, Neuburg an der Donau, Germany

²Department of Medicine, Klinikum St. Marien, Amberg, Germany

³Department of Medicine II, Saarland University Hospital, Homburg, Germany

Clinical Image

A 67-year old patient with a history of left sided ulcerative colitis (UC) and ischemic cardiomyopathy (CMP) was admitted with rectal bleeding. Mayo score at admission was 9. The patient was on oral and topical steroids and off mesalazine due to pancreatitis. Endoscopy showed left sided moderate UC. Symptoms persisted after initiating prednisolone at 1 mg/kg KG po. After bacterial super infection was ruled out, IV steroids were administered at 2 mg/kg KG. Repeat evaluation showed severe UC (Figure 1). Cytomegalus virus (CMV) super infection was diagnosed and treated with oral valganciclovir. The patient was started on tacrolimus po and steroids were tapered. Mayo score remained 10. Colectomy was declined by the patient. Thus, rescue therapy with vedolizumab (VDZ) was initiated. By week 10 of VDZ-treatment, MAYO score was 2 and endoscopy showed complete mucosal healing (Figure 2). Thus, VDZ can be used as rescue treatment for refractory UC if CNI inhibitors are ineffective and Anti-TNF-treatment is contraindicated.

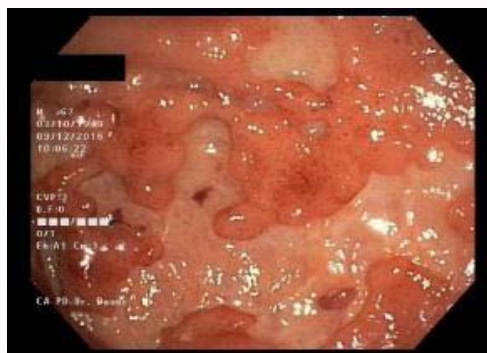

Figure 1: Severe ulcerative colitis in steroid-refractory UC.

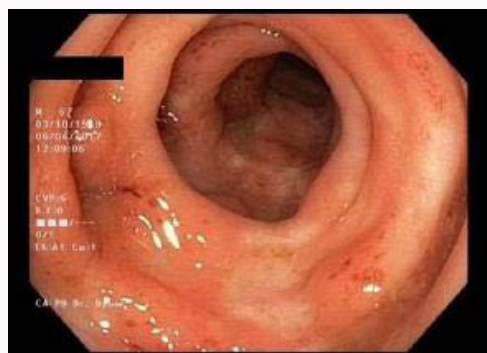


Figure 2: Endoscopic remission after 10 weeks of treatment with VDZ.

OPEN ACCESS

*Correspondence:

Dauer M, Department of Medicine II, Saarland University Hospital, Homburg, Germany, Mobile: 0049-179-1342553;

E-mail: marc.dauer@gmx.de

Received Date: 23 Sep 2017

Accepted Date: 16 Oct 2017

Published Date: 23 Oct 2017

Citation:

Riehl S, Dauer M. Refractory Left Sided Ulcerative Colitis – Rescue Treatment with Vedolizumab. *J Gastroenterol Hepatol Endosc.* 2017; 2(5): 1028.

Copyright © 2017 Dauer M. This is an open access article distributed under the Creative Commons Attribution License, which permits unrestricted use, distribution, and reproduction in any medium, provided the original work is properly cited.