



## Cerebral Toxoplasmosis in an HIV Negative Patient: The First Documented Case Report in Africa and Literature Review

Christine Katusiime\*

Department of Prevention Care and Treatment, Makerere University, Uganda

### Abstract

**Background:** Cerebral toxoplasmosis in HIV negative persons is extremely rare. To the best of our knowledge, this is the first documented case of cerebral toxoplasmosis in an HIV negative individual in Africa.

**Case Presentation:** We present a 45-year-old HIV negative Ugandan woman who was diagnosed with Cerebral toxoplasmosis. Both serology for *Toxoplasma gondii* and cerebral magnetic resonance imaging (MRI) were positive for cerebral toxoplasmosis. The patient showed remarkable clinical improvement following initiation of chemotherapy and maintains clinical improvement.

**Conclusion:** This case illustrates the rarity of cerebral toxoplasmosis in HIV negative persons. To the best of our knowledge, this is the first documented case of cerebral toxoplasmosis in an HIV negative person in Africa and the first documented female case of its kind. This case without a doubt, underscores the necessity of routine screening for cerebral toxoplasmosis in HIV negative patients that present with neurological symptoms.

### Introduction

Globally, toxoplasmosis is recognized as an infection caused by *Toxoplasma gondii*, an obligate intracellular protozoan parasite that is acquired typically through intake of raw or undercooked meat containing bradyzoites, through ingestion of oocysts in cats faeces, mother-to-unborn child transmission, blood transfusion and transplantation [1,2].

A third to half of the global human population has been documented as being infected with *T. gondii* [3,4]. Toxoplasmosis notably causes major debilitating sequelae in the central nervous systems (CNS) of immunosuppressed persons particularly those with HIV infection. This case highlights a case of cerebral toxoplasmosis in a patient without HIV/AIDS in Uganda.

### Case Presentation

A 45-year-old African woman presented to the infectious disease unit of a private hospital in Kampala, Uganda with a 7-month history of headache, bilateral lower limb weakness and a 2-month history of visual blurring in the left eye. Her headaches were generalized, throbbing, non-radiant, with no associated or aggravating factors though were mildly relieved with non-steroidal anti-inflammatory drugs. She had no history of dizziness, vomiting, loss of consciousness, loss of balance, numbness or seizures. She had no history of ever being a pet-owner – in particular owning a cat. She owned a food business in a local area of the city that was directly adjacent to a chicken raring coup for more than 10 years. She had visited several physicians who had purportedly made a diagnosis of brucellosis.

Neurological examination revealed a patient with a Glasgow coma scale 8/15, bilateral paraparesis, positive babinski's sign and a reduced power in both lower limbs of 3/5. She also had a convergent squint in the left eye. General, dermatologic, respiratory and cardiovascular systemic review did not yield significant findings.

With continual deterioration, she was taken to yet another physician who had ordered an MRI scan of the brain. The MRI had revealed multi-focal intra-cranial lesions.

The gadolinium-enhanced MRI showed multiple variable sized; well-enhanced lesions in the right temporal-parietal, right frontal, left parietal lobes and right lentiform nucleus and part of

### OPEN ACCESS

#### \*Correspondence:

Christine Katusiime, Department of Prevention Care and Treatment, Makerere University, Kampala, Uganda, E-mail: katutina1@gmail.com

Received Date: 14 Jan 2018

Accepted Date: 12 Feb 2018

Published Date: 19 Feb 2018

#### Citation:

Katusiime C. Cerebral Toxoplasmosis in an HIV Negative Patient: The First Documented Case Report in Africa and Literature Review. *Ann Infect Dis Epidemiol.* 2018; 3(1): 1026.

ISSN: 2475-5664

#### Copyright © 2018 Christine

Katusiime. This is an open access article distributed under the Creative Commons Attribution License, which permits unrestricted use, distribution, and reproduction in any medium, provided the original work is properly cited.

**Table 1:** HIV-negative patients that have been diagnosed with toxoplasmosis.

	AGE	GENDER	DIAGNOSIS	LESION LOCATION	CONCURRENT CONDITIONS	RACE	COUNTRY	OUTCOME
Headaches	39	F	Brain biopsy; IgG(+); MRI	Right temporo-parietal lesion	N/A	N/A	Iran	Improvement
Tonic-clonic seizure	64	F	IgG(+); MRI	Supratentorial lesions	Erosive Rheumatoid Arthritis	Caucasian	France	Improvement
Headaches; gait & speech disturbances; bilateral peripheral facial palsy & mild left hemiparesis	67	M	Brain biopsy; MRI	Right thalamus lesion	Rheumatoid Arthritis	Caucasian	Italy	Improvement
Generalized tonic-clonic seizure	18	M	IgG(+); MRI	Basal ganglia, right frontal & left parietal lobe lesions	Systemic Lupus Erythematosus	N/A	Malaysia	Improvement
Headache, Photophobia, pyramidal weakness of the right upper arm, ataxia and dysmetria of all extremities	62	F	IgG(+); MRI	Right occipital lobe, cerebral & cerebellar hemisphere lesions	Systemic diffuse large B cell lymphoma	Caucasian	Slovenia	Improvement
Altered mental status	90	F	Brain autopsy; Neuroimaging	Corpus callosum and both periventricular frontal horn	Autoimmune hemolytic anemia and large granular lymphocytic leukemia	N/A	USA	Died
					Systemic Lupus Erythematosus			
			Brain autopsy	N/A				
Confusion								
	44	F				N/A	USA	Died
N/A	70	M	Brain autopsy	Wide-spread microglial nodules	Stage IV chronic lymphocytic leukemia & Aplastic Anemia	N/A	USA	Died
Status epilepticus	45	M	MRI; Brain biopsy	Ventral thalamus-hypothalamus region	Chronic myelocytic leukemia	N/A	Czech Republic	Improvement
Headache	37	F	IgG(+); MRI	Right caudate nucleus & right thalamus	Hematopoietic stem cell transplantation for Aplastic Anemia	Korean	Korea	Improvement
N/A	5	patients	MRI; PCR	N/A	Hematopoietic stem cell transplantation patients	N/A	Turkey	N/A
N/A	15	n/a	Rapid invasive diagnostics	N/A	Post allo-HCST for Non-Hodgkin lymphoma	N/A	Germany	Improvement
N/A	N/A	N/A	N/A	N/A	Post transplantation for Acute myeloid leukemia	N/A	Belgium	N/A
Diplopia; left hemiparesis	69	M	MRI; IgG(+); Brain biopsy	Protuberancial lesions	Waldenstrom's macroglobulinemia	N/A	Spain	Died
N/A	N/A	N/A	N/A	N/A	N/A	N/A	Germany	N/A
Tremors, muscular weakness, diplopia, dysarthria	25	M	MRI; Necropsy	N/A	Chronic Myelogenous leukaemia	N/A	Spain	Died
N/A	12	F	N/A	N/A	HSCT recipient	N/A	Israel	N/A
Confusion; left-sided weakness; altered mental state	44	M	2MRIs; Brain biopsy	Right basal ganglia lesion	Allogeneic HCT for ALL	Caucasian	USA	Improvement
N/A	68	F	MRI; CSF analysis	N/A	Allografted for AML	N/A	Germany	Died
Neurologic symptoms	44	M	MRI; Brain biopsy	Multiple focal space occupying lesions	Renal transplant recipient	Indian	India	Improvement
Headache; speech difficulties; right facial nerve paresis; right arm paresis; left hemiparesis; right-sided thalamic syndrome	42	F	Brain CT; Autopsy	Right thalamus lesions	Allo-HSCT for CML	N/A	Slovenia	Died
N/A	2	patients	IgG(+)	N/A	Allogeneic HSCT	N/A	UK	N/A
N/A	N/A	N/A	N/A	N/A	N/A	N/A	Germany	N/A
N/A	N/A	N/A	N/A	N/A	Autologous stem cell transplantation for NHL	N/A	Spain	N/A
Speech disturbance; behavioral changes	71	F	MRI; CSF analysis; Brain biopsy; IgG(+)	Multiple ring enhancing lesions	Rituximab for Uncontrolled Cutaneous necrotizing vasculitis	N/A	France	N/A
Mental confusion	50	F	IgG(+); MRI brain; CSF Toxo PCR	Basal ganglia	Renal transplant for ESRD	Ghanese	Netherlands	Died

N/A	66/F	IgG(+); Brain MRI	Right occipital lobe lesion	Cord blood transplantation for refractory angioimmunoblastic T-cell lymphoma	N/A	Japan	N/A
N/A	31 patients	Pre-mortem & post-mortem data	N/A	Allo-graft HSCT patients	N/A	Spain	N/A
N/A	N/A	N/A	N/A	Connective tissue disease	N/A	Italy	N/A
N/A	23/M	IgG(+); Brain MRI	Posterior left parietal lobe	CML	N/A	USA	Died
Frank confusion; visual hallucinations	79/F	MRI; CSF Toxo PCR	Innumerable peripherally enhancing lesions	Waldenstrom macroglobulinemia with hyperviscosity syndrome	N/A	USA	N/A
Right facial droop; slurred speech; progressive worsening right sided weakness	76/F	MRI; Brain biopsy; IgG(+)	Cortical enhancing lesions	DM; RA, Chronic kidney disease; hypertension; chronic stable thrombocytopenia	Caucasian	USA	Improvement
Neurological symptoms	22/M	MRI	Right thalamus & left lenticula nucleus	Severe cutaneous & hepatic GVHD	N/A	Italy	Improvement
Disturbance of consciousness	60/F	MRI; CSF IgG(+)	Thalamus, basal ganglia, brainstem & sub-cortical white matter	Myelodysplastic syndrome	N/A	Japan	Improvement
Apraxia, forgetfulness, cognitive impairment	63/M	MRI; Brain biopsy; CSF Toxo PCR	Right & left frontal and parietal lobes	CLL	N/A	USA	Died
Confusion; ataxia	81/M	CT Scan; Brain biopsy	Left frontal cortex	Advanced stage CLL	N/A	UK	N/A
N/A	N/A	N/A	N/A	Post-autologous PBPC	N/A	Spain	Improvement
Impaired consciousness; Hydrocephalus	n/a/F	Imaging studies; Biopsy	Right basal ganglia, periventricular grey matter, mid brain and pons	Non-immunocompromised pregnant woman	N/A	India	Improvement
Headaches; Right facial paresis; Right hemiparesis	42/M	Brain CT scan; MRI; Toxo IgG(+)	Both cerebral hemispheres	Post-Kidney transplantation	N/A	Portugal	Improvement
Headaches; nuchal rigidity, right sided hemiparesis	34/n/a	Toxo IgG(+); Brain CT Scan	N/A	Bone marrow transplantation for CML	N/A	Israel	N/A
Worsening dysarthria; pseudobulbar syndrome	38/F	Autopsy	Left centrum semiovale & right basal ganglia	Intensive cytotoxic therapy & allogeneic marrow rescue for Acute promyelocytic leukemia	n/a	The Netherlands	Died
Neurological signs	46/n/a	Autopsy	n/a	Allogeneic bone marrow transplantation in AML	n/a	The Netherlands	Died
Cerebellar ataxia; visual blurring; scotomas; photophobia; central vision impairment; mental changes; memory defects	23/M	CSF analysis; Post-mortem	N/A	BMT	n/a	West Germany	Died
Headache; behavioural changes; neurological deterioration	21/M	IgG(+); Brain CT scan; MRI; Brain biopsy	Cerebellum, brainstem, & cerebrum	Allogeneic BSCT for myelodysplasia	Turkish	UK	Improvement
N/A	36/F	Brain Autopsy	N/A	SLE & Lupus nephritis; Renal transplant	N/A	USA	Died
N/A	16/F	N/A	N/A	BMT for ALL	N/A	N/A	N/A
Seizures; focal signs; headaches; coma and neuropsychological signs	20 patients [51/F,38/F,52/F,29/M,49/M,35/M,45/M,39/M,31/M,29/F,28/F,17/F,27/M,31/M,54/F,50/F,30/F,48/M,42/F,37/M.	18 Brain MRIs; 2 Brain autopsies; Brain biopsies	N/A	BMT patients	N/A	N/A	N/A
Diplopia	25/M	Brain MRI; IgG(+); PCR CSF	Cerebral & cerebellar hemispheres	BMT for ALL	N/A	USA	Improvement
Headache	15/M	MRI; IgG(+); CSF analysis	Left occipital lobe	Rhabdomyosarcoma	Hispanic	USA	Improvement

		Autopsy					
N/A	N/A		N/A	N/A	N/A	USA	N/A
N/A	2 patients	MRIs; CT scans	N/A	BMTs	N/A	AUSTRIA	N/A
Confusion; lethargy; inability to follow commands	39/M	MRI; Brain autopsy	N/A	BMT for CML	N/A	USA	Died
N/A	12 patients	Toxo PCRs; CSF Toxo PCRs	N/A	Allo-HSCT patients	N/A	France	N/A
Worsening motor deficits of right upper and lower limbs; gait instability; expressive dysphasia	40/F	MRI; Brain biopsy	Basal ganglia	Large granular lymphocytic (LGL) Leukemia	Lebanese	Canada	Improvement
Deteriorating neurological symptoms	N/A	MRI; Brain autopsy	Brain & cerebellum	Bone marrow transplant for CML	N/A	N/A	Died
Progressive incoherent speech; time disorientation; wide-base gait; decline of cognitive fn; memory impairment; focal seizure	47/M	Brain CT scan; Brain MRIs; Brain Biopsy; IgG (+)	Bilateral cerebral hemispheres; right cerebellar & pons	SLE	N/A	Taiwan	Improvement
Confused state; convulsive episode; deterioration of mental state	48/F	Brain autopsy	N/A	SLE	N/A	Israel	Died
Headache; visual disturbance; right-sided facial weakness	54/F	Brain CT; Brain MRI	Left posterior frontal lobe	Metastatic thymoma	N/A	Australia	Improvement
Convulsive episode	18/M	Brain CT; Brain biopsy	Left cerebral hemisphere	Moderate progressive chronic GVHD	N/A	Brazil	Died
Headache; double vision; drowsiness	9/M	Brain CT; Brain autopsy	Both cerebral hemisphere	Chemotherapy for Hodgkins Disease	N/A	Brazil	Died
Progressive left hemiparesis; headache		Brain CT Scan; Brain biopsy	Basal ganglia	N/A			
	22/M				N/A	Brazil	Died
Right hemiplegia; Billateral Babinski signs		Brain CT Scan					
			Basal ganglia, right parietal and both occipital lobes	Hodgkin's disease			
	5/M				N/A	Brazil	Improvement
Neurological symptoms	N/A	MRI; <i>T.gondii</i> PCR	Hyperintense lesions	Allogeneic HSCT	N/A	Japan	Improvement
		MRI; <i>T.gondii</i> PCR					
Neurological symptoms			Hyperintense lesions				
	N/A			Allogeneic HSCT	N/A	Japan	Improvement
Right homonymous hemianopsia; right hemiparesis; transient unconsciousness	24/F	Brain CT Scan; Tumour resection; IgG(+)	Left cerebral hemisphere	SLE	N/A	Japan	Improvement
Right homonymous hemianopsia; aphasia; consciousness disturbance	75/F	Brain MRI scan; IgG(+)	Left occipital lobe	Myelogenous leukemia	N/A	Japan	Improved
Cognitive decline	69/M	Brain MRI; Brain Autopsy	Left thalamus, right pulvinar thalami, putamina, right head of caudate nucleus	None	N/A	Croatia	Died
N/A	61/N/A	Brain biopsy	N/A	Lymphoma	N/A	Germany	Improvement
Neurological symptoms	55/N/A	Brain biopsy	N/A	Acute T-cell leukaemia	N/A	Germany	Improvement
Seizure disorders	25/M	Brain MRI; Brain biopsy and excision	Right frontal and sub-cortical regions	NONE	N/A	India	Improvement
N/A		Brain MRI	N/A	N/A	N/A	India	N/A
	2 patients						
N/A		Brain MRI	N/A	N/A	N/A	India	N/A
Generalized convulsions	62/M	Brain MRI; IgG(+)	Multiple ring-enhanced lesions	Progressive glomerulonephritis	N/A	Japan	Improvement

Headaches; second degree coma; nuchal rigidity; left hemiparesis; seizures	7/N/A	Brain CT scan; Toxo elisa	Frontal and parietal lobes	NONE	N/A	Romania	Improvement
Involuntary hand movements; difficulty in speaking	11/F	CSF IgG(+)	N/A	N/A	N/A	Turkey	Improvement
Headache	42/M	Brain MRI; CT brain; CSF Toxo IgG(+)	Both cerebral hemispheres; left thalamus; globus pallidus	NONE	N/A	India	Died
Dysphasia; numbness of left limb	33/M	Brain CT, Brain MRI, Tumour removal; CSF Toxo IgG(+)	Left temporal lobe	NONE	N/A	China	Improvement
Headache, diplopia, right sixth cranial nerve palsy	15/F	Brain CT	Right frontal lobe	Acute lymphoblastic leukemia	Caucasian	USA	Improvement
Headache, left sided weakness	27/M	Brain MRI; Brain biopsy	Pontine and midbrain	NONE	N/A	India	Improvement
Mouth angle deviation, difficulty closing right eye, unsteady wide-based gait	14/M	Brain MRI; Excision	Pons and the medulla	NONE	N/A	India	Died
Headache	14/M	IgG(+); Brain MRI	Ventriculitis	NONE	N/A	Iran	Improvement
Headache	15/F	Brain CT scan; Brain MRI; IgG(+); Excision	Left parietal corticomedullary junction	ALL	N/A	Iran	Died
		Brain MRI; IgG(+)	Multiple enhancing lesions				
Generalized status tonic clonic convulsions	6/M			AML	N/A	Iran	Improvement
Diplopia; photophobia; ptosis	17/M	Brain CT scan; Brain MRI; IgG(+); CSF IgG(+)	Basal ganglia; right cerebral peduncle	Hodgkin's lymphoma	N/A	Iran	Improvement
Worsening frontal headache	30/M	Brain CT scan; Brain MRI	Basal ganglia	NONE	N/A	Italy	Improvement
N/A	N/A/F	N/A	N/A	N/A	N/A	Pakistan	N/A
Ataxia, nystagmus, neck pain, intensive equilibrium disturbances	7/F	Brain MRI; IgG(+); CSF IgG(+)	Cerebellum	NONE	N/A	Poland	Improvement
Mental disturbance, right hemiplegia	74/M	Brain CT; IgG(+)	Cerebrum	Hairy Cell Leukemia	N/A	Japan	Improvement
N/A	27/F	Brain MRI; Biopsy; IgG(+)	Pituitary	Nonfunctioning Pituitary Adenoma	N/A	Switzerland	Improvement
N/A	65/F	N/A	N/A	IFN- $\gamma$ deficiency	Caucasian	Germany	N/A
Visual impairment; consciousness disorders; sensory aphasia; headache	17/M	Brain CT Scan; IgG(+)	Occipital, frontal, temporal, left parietal lobes	HSCT for Fanconi Anaemia	N/A	Poland	Improvement
Severe headache	65/M	Blood PCR; CSF PCR; Toxo IgG(+)	Cerebrum	CML	Caucasian	France	Died
Frontal and left-sided temporal headache; visual blurring	25/M	Brain MRI; Brain biopsy	Left temporoparietal, right anterior frontal, left parasagittal, bilateral occipital lobes	Sarcoidosis	N/A	India	Improvement
N/A	N/A	CSF analysis	N/A	Azathioprine and systemic glucocorticoids for Ulcerative colitis	N/A	Greece	N/A
Right sided hemiparesis	44/M	Brain MRI; Toxo IgG(+); Brain biopsy	Cerebral hemispheres	Renal transplant for Diabetic nephropathy	N/A	India	N/A
Seizures	18/F	Toxo DNA in CSF	N/A	BMT for B-cell ALL	N/A	France	Improvement
Right-sided facial dysesthesia	38/M	Brain MRI; Toxo IgG(+)	Medulla Oblongata	NONE	N/A	Japan	N/A

the right thalamus and right subependymal area (Figure 1). The largest lesion in the right temporo-parietal region had extensive large perifocal edema exerting mass effect in form of subfalcine herniation measuring about 39 x 24mm. The second largest lesion in the right lentiform nucleus and right thalamus with large perifocal edema measured about 20 x 22mm. Other lesions were noted in the dura on the left. There was a right to left midline shift of 9mm. All lesions depicted significant ring enhancement (Figure 1).

Chest and Lumbar-sacral X-rays and ultrasound scans of the pelvis and abdomen were not significant. Additional tests that were discussed with the patient's attendant were MRI-guided brain biopsy, and ophthalmologic review which were both declined by the attendant because of financial constraints.

Laboratory investigations revealed a total white blood cell count of  $7.93 \times 10^9/L$ , platelet count of  $201 \times 10^9/L$  and hemoglobin of 12.8 g/dL. Random blood sugar, liver function tests, renal function tests

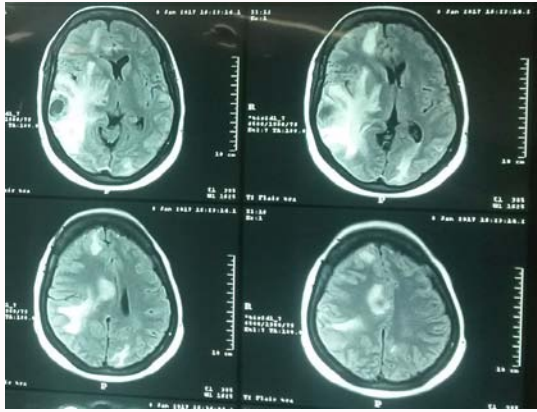


Figure 1: MRI showing *T.gondii* lesions.

and serum electrolytes were normal. Multiple HIV serological tests that had been done by the patient over a series of the past 4 years, as part of self-initiated health status assessment at different testing centers were negative. Additional HIV antibody tests for HIV-1/2 and an HIV viral load were negative. Hepatitis B surface antigen (HBsAg), rheumatoid factor, serum CRAG and antinuclear antibody (ANA) tests were negative. Toxoplasma serological IgG was found to be positive 1.55 U/mL (reference positive range > 1.1 U/mL).

Soon after, the patient was taken to the village by her attendant to seek traditional remedies, against medical advice, for a period of 2 weeks, having initially declined to commence high-dose trimethoprim/sulfamethoxazole for cerebral toxoplasmosis.

With continual counseling and follow-up, the patient was brought back to the city centre having deteriorated to a much more critical condition, with a GCS of 4/15, two weeks after the diagnosis date, and hospitalized. The patient was initiated on high-dose trimethoprim/sulfamethoxazole, dexamethasone and analgesics. Following 4 weeks of strict directly-observed therapy, the patient remarkably improved clinically with significant recovery in her alert level to a fully conscious state with the ability of short and long-term memory recall, articulation of speech, and mobility.

## Discussion

This is the first documented observation of primary cerebral toxoplasmosis in an HIV-negative individual in Uganda and the first on the African continent. As high as 50% of the world's human population, is asymptomatic with *T.gondii* infestation [3,4]. Studies have shown that in HIV negative individuals, *T.gondii* infestation was greatly linked to the consumption of either undercooked or raw meat [2,5]. HIV/AIDS is therefore not a prerequisite for cerebral toxoplasmosis.

According to country reports, the highest numbers of published cases were from USA, India, Japan and Germany.

Low endemic countries included Australia, Croatia, Romania, China, Pakistan, Switzerland, Greece, Iran, Malaysia, Czech Republic, Korea, Belgium, Portugal, Austria, Canada and Taiwan. There have virtually been no reports from African countries. This is possibly because of insufficient diagnostic facilities and a low index of suspicion of Toxoplasmosis in HIV-negative persons.

Cerebral disease denotes reactivation of latent parasitic infestation [6]. Most documented cases showed underlying conditions that contributed to toxoplasma infestation. Our patient presented with neurological symptoms: headache and bilateral paraparesis; this is in keeping with study findings that illustrate that the most common symptom of cerebral toxoplasmosis in immune-competent individuals is headache [6]. Furthermore, the differential diagnosis of toxoplasmosis was considered in our patient when the history disclosed her occupation – she had run a food business in a local area of the city for over 10 years that was adjoined to an open chicken enclosure. The suspicion of consumption of undercooked or raw meat was strongly considered and prompted us to run a serological screening test to rule out toxoplasmosis.

The MRI in our patient depicted multiple regions affected by *T.gondii*: the right temporal-parietal lobe, right frontal lobe, left parietal lobe, right lentiform nucleus and part of the right thalamus and right subependymal areas. All lesions showed significant ring enhancement. Although the patient's spouse declined a brain biopsy, cerebral toxoplasmosis was confirmed from the positive serum toxoplasma titer levels. Radiological improvements on MRI can be detected in as little as within 10 days of initiation of treatment, in keeping with the immediate and remarkable clinical improvement that we saw in our patient. Our patient showed significant clinical improvement after initiation of high-dose co-trimoxazole, and she is still adhering to her medications. Upon review of literature, we have not come across a similar case regarding immunocompetent persons in Uganda or Africa.

## Conclusion

This case underscores the necessity of screening for cerebral toxoplasmosis in immune-competent patients that present with neurological symptoms. Early diagnosis and treatment is paramount, as undiagnosed parasitic *T.gondii* infestation can be fatal.

## References

1. Kistiah K, Winiiecka-Krusnell J, Barragan A, Karstaedt A, Freaun J. Seroprevalence of Toxoplasma gondii infection in HIV-positive and HIV-negative subjects in Gauteng, South Africa. South Afr J Epidemiol and Infection. 2011; 26(4):225-8.
2. Walle F, Kebede N, Tsegaye A, Kassa T. Seroprevalence and risk factors for Toxoplasmosis in HIV infected and non-infected individuals in Bahir Dar, Northwest Ethiopia. Parasit Vectors. 2013;6(1):15.
3. Swai ES, Schoonman L. Seroprevalence of Toxoplasma gondii infection amongst residents of tanga district in north-east Tanzania. Tanz J Hth Res. 2009;11(4):205-9.
4. Ganiem AR, Dian S, Indriati A, Chaidir L, Wisaksana R, Sturm P, et al. Cerebral toxoplasmosis mimicking subacute meningitis in HIV-infected patients; a cohort study from Indonesia. PLoS Negl Trop Dis. 2013; 7(1):e1994.
5. Montoya JG, Remington JS. Toxoplasma gondii. In Principles and practice of infectious diseases. 5th edition. 2000:2858-88.
6. Arab-Mazar Z, Zamanian MH, Yadegarynia D. Cerebral toxoplasmosis in an HIV-Negative patient: A Case report. Arch Clin Infect Dis. 2016;11:e30759.