



Huge Multinuclear Cells in Vitreous Sample Obtained from the Patient with Vitreous Opacity

Tohru Inaba^{1*}, Kenji Nagata² and Kazuichi Maruyama^{2,3}

¹Department of Infection Control and Laboratory Medicine, Kyoto Prefectural University of Medicine, Japan

²Department of Ophthalmology, Kyoto Prefectural University of Medicine, Japan

³Department of Innovative Visual Science, Osaka University Medical School, Japan

Clinical Image

A 70-year-old male received Pars Plana Vitrectomy (PPV) due to vitreous opacity in his right eye. Cytospin specimens prepared from his vitreous fluid mainly consisted of mature small lymphocytes. In addition, there were several huge multinuclear cells (>50 micrometer in diameter with >10 nuclei) morphologically resembling macrophages (Figure 1). Flow cytometric analysis revealed that the majority of his intraocular cells were CD3⁺ T-lymphocytes, and CD4/CD8 ratio was elevated to 12.2. He was diagnosed as having ocular sarcoidosis. We have examined the morphology and immunophenotypic of vitreous cells obtained from more than 400 eyes including 124 with definite sarcoidosis. Patients with ocular sarcoidosis showed the predominant CD4⁺ T-lymphocytes mixed with several macrophages sometimes containing 3-4 nuclei. But, in our experience, such huge multinuclear cells reported here have been never found in the other cases. Further analysis is necessary to elucidate the clinical significance of such characteristic cells in ocular sarcoidosis.

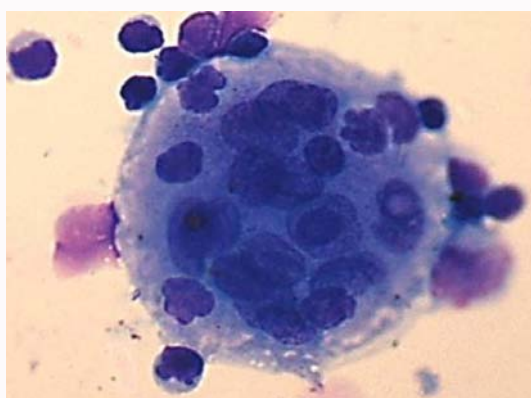


Figure 1: Cytospin specimen of vitreous fluid obtained from the right eye of this patient. Wright-Giemsa staining (x1,000) showed the huge multinuclear cell in addition to mature small lymphocytes.

OPEN ACCESS

*Correspondence:

Tohru Inaba, Department of Infection Control and Laboratory Medicine, Kyoto Prefectural University of Medicine, Kawaramachi-Hirokoji, Kamigyo-ku, Kyoto 602-8566, Japan, Tel: +81-75-251-5852; Fax: +81-75-251-5678; E-mail: inaba178@koto.kpu-m.ac.jp

Received Date: 29 Dec 2017

Accepted Date: 14 Jan 2018

Published Date: 18 Jan 2018

Citation:

Inaba T, Nagata K, Maruyama K. Huge Multinuclear Cells in Vitreous Sample Obtained from the Patient with Vitreous Opacity. *J Clin Ophthalmol Eye Disord.* 2018; 2(1): 1022.

Copyright © 2018 Tohru Inaba. This is an open access article distributed under the Creative Commons Attribution License, which permits unrestricted use, distribution, and reproduction in any medium, provided the original work is properly cited.