



## A Case with Eyelid and Eyelashes Ptosis

Ozdemir Ozdemir\*

Department of Ophthalmology, Zekai Tahir Burak Women's Health Education and Research Hospital, Ankara, Turkey

### Keywords

Bell's phenomenon; Lash ptosis; Levator function; Marginal reflex distance; Ptosis

### Clinical Image

A 77-year-old woman presented with bilateral eyelid and eyelash ptosis. Her complaints have increased over the last two years. In the ocular examination, the corrected visual acuities were 20/20 bilaterally. The intraocular pressures were 17 mmHg in the right eye and 18 mmHg in the left. There was bilateral eyelid ptosis accompanied by lash ptosis. The marginal reflex distance-1 was measured 1.5 mm in the right eye and 2 mm in the left eye. Levator functions were found 10 mm in both eyes. Bell's Phenomenon was existed in both eyes. Lash ptosis or eyelash ptosis is a drooping or declining of the upper eyelashes. It results from the anatomical changes in the eyelid. It has been reported an association with floppy eyelid syndrome, congenital ichthyosis, acoustic neuroma and latanoprost usage. This condition is sometimes together with eyelid ptosis. The management of lash ptosis is generally surgical. The surgical approaches depend on the severity and the accompanying conditions such as eyelid ptosis or blepharoptosis. The main purpose is to rotate the lash line upwards using sutures. Finally, a surgical treatment including eyelid and eyelashes ptosis was recommended to this patient (Figure 1).

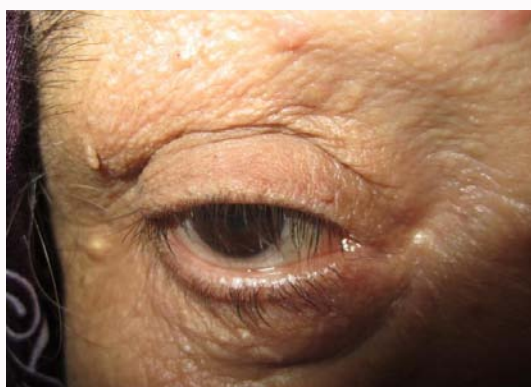


Figure 1: Eyelid and eyelashes ptosis.

### OPEN ACCESS

#### \*Correspondence:

Ozdemir Ozdemir, Department of Ophthalmology, Zekai Tahir Burak Women's Health Education and Research Hospital, Ankara, Turkey, Tel: 90 312 306 56 52; Fax: 0 312 312 49 31;

E-mail: ozdemirozdemir@yahoo.com

Received Date: 25 Jul 2016

Accepted Date: 05 Sep 2017

Published Date: 14 Sep 2017

#### Citation:

Ozdemir O. A Case with Eyelid and Eyelashes Ptosis. *J Clin Ophthalmol Eye Disord.* 2017; 1(2): 1006.

Copyright © 2017 Ozdemir

Ozdemir. This is an open access article distributed under the Creative Commons Attribution License, which permits unrestricted use, distribution, and reproduction in any medium, provided the original work is properly cited.